

Original Research Article

Effect of scopoletin on fascia-wrapped diced cartilage grafts

Ning Zeng, Yi Xu, Xian Wang, Yiping Wu and Haiping Wang*

Plastic and Aesthetic Surgery, Tongji Hospital, Fongji Medical College, Huazhong University of Science and Technology, Wuhan, Hubei Province 430030, China

*For correspondence: **Email:** wanghaiping7@hotmail.com; **Tel/Fax:** 0086-27-3692814

Sent for review: 13 January 2017

Revised accepted: 20 June 2017

Abstract

Purpose: To evaluate the effect of scopoletin (SL) on fascia-wrapped diced cartilage grafts in rhinoplasty surgery.

Methods: Cartilage grafts (2 × 2 cm) from the ears of New Zealand rabbits were diced into sections (1 mm³) and then wrapped in muscle fascia taken from the right rear leg. Each graft was placed on the back of the animal after measuring its weight, and then the rabbits were separated into two groups, viz, control and the SL-treated groups {10 mg/kg, per os (p.o.)}. The treatments were administered for 3 months, the rabbits were sacrificed, and the histopathological features and weight of the grafts were examined.

Results: The weight of the grafts in the two groups did not significantly ($p < 0.05$) differ but the histopathological results suggested that there was a pronounced increase in the viability of the graft tissues in the SL-treated group compared to the control group. Treatment with SL decreased the resorption rate and enhanced basophilia relative to the control group. However, fibrosis, inflammation, and bone metaplasia- and calcification-like factors did not significantly differ ($p < 0.05$).

Conclusion: Treatment with SL significantly enhances the viability of the grafts, and thus may have a beneficial effect on fascia-wrapped diced cartilage grafts.

Keywords: Scopoletin, Rhinoplasty surgery, Fascia-wrapped diced cartilage graft, Histopathology, Basophilia, Inflammation

Tropical Journal of Pharmaceutical Research is indexed by Science Citation Index (SciSearch), Scopus, International Pharmaceutical Abstract, Chemical Abstracts, Embase, Index Copernicus, EBSCO, African Index Medicus, JournalSeek, Journal Citation Reports/Science Edition, Directory of Open Access Journals (DOAJ), African Journal Online, Bioline International, Open-J-Gate and Pharmacy Abstracts

INTRODUCTION

The term 'cartilage graft' was first coined at the end of the 19th century in association with nasal defect reconstruction surgeries [1]. Subsequently, various types of cartilage graft have been used by surgeons to maintain the structural integrity of a patient's body [2]. The graft resorption rate is affected by a variety of parameters, including surgical trauma, graft preparation, and shape; anaesthetic deformities and defective contours can result from excessive resorption rates [3,4].

Long-term permanent results and easily shaped grafts can be obtained by the application of several surgical techniques. For example, block form and fascia-wrapped grafts are easy to implement and have produced successful outcomes for nasal dorsal augmentation and surgically wrapped diced cartilage grafts [5]. Although several current techniques can be used to reduce the resorption rate and form a graft that can be easily shaped, not all surgeons accept a particular model as being ideal for increasing the viability of diced cartilage grafts despite the use of novel surgical techniques. Thus, the present

study aimed to determine if specific drugs could enhance the viability of cartilage grafts without requiring modification of current surgical techniques.

Scopoletin (SL) is isolated from a Chinese medicinal plant known as *Aster tataricus* [6], which contains a coumarin compound that is reported to have antitumor, antioxidant, and anti-inflammatory effects [7-9]. These effects are likely due to the inhibitory effect of this compound on tube formation, endothelial cell migration, cytokinin production, COX-2 expression, and nitric oxide synthesis [10-12]. Intraperitoneal administration of SL significantly reduces the thickness of synovium and attenuates inflammation in the joints [6]. Moreover, SL activates caspase-3 and subsequently induces apoptosis and cell arrest in tumour cells [13,14]. Thus, the present study evaluated the effects of SL on fascia-wrapped diced cartilage grafts.

EXPERIMENTAL

Animals

The present study used New Zealand rabbits (age, 2 months; weight, 800-1,200 g) that were housed under standard laboratory conditions in a room maintained under a temperature of 20–25°C and a 12-h light-dark cycle. The rabbits were housed in the lab, under environmental conditions according to the relevant guidelines, for 10 days prior to the experiment to acclimatise them to the environment. All protocols used in the present study were approved by the animal ethical committee of Tongji Medical College, Tongji Hospital, Huazhong University of Science and Technology, China (ref. no. TJM/ 2015/ 19) and the given study followed the guidelines of

Association for the Assessment and Accreditation of Laboratory Animal Care International (AAALAC) for experimentation and animal use [15].

Animal studies

All animals were anaesthetised with an intramuscular injection of xylazine (5 mg/kg) and ketamine (35 mg/kg) and treated with cefuroxime, which was injected at a prophylactic dose of 30 mg/kg (intramuscular) prior to surgery. The shaving was done at the donor site of each animal and an iodine solution was used to clean the exposed skin. Subsequently, the skin was pulled away from the auricular tissue and the cartilage sections were diced into squares (2 × 2 cm) with the perichondrium protected in the cartilage tissue. Next, a scalpel was used to cut the sections into 2–3 mm pieces; then, the cartilage graft was wrapped in a 2 × 2 cm section of fascia obtained from the right hind leg and the incision was sutured with 5/0 vicryl (Figure 1).

A sensitive scale was used to measure the weights of the fascia-wrapped cartilage grafts, which were implanted by preparing a subcutaneous cavity 5 cm lateral to the midline on the back of each animal. Next, the incision was sutured with 4/0 silk and the animals were divided into two groups based on treatment: the control group received a saline solution and the SL-treated group received daily administrations of SL {10 mg/kg, per os (p.o.)} for 3 months. At the end of the protocol, all animals were sacrificed with thiopental sodium (150 mg/kg) and the grafts were removed. Next, the cleaned grafts were weighed and placed into a 10 % formalin solution for further histopathological study (see Figure 2).

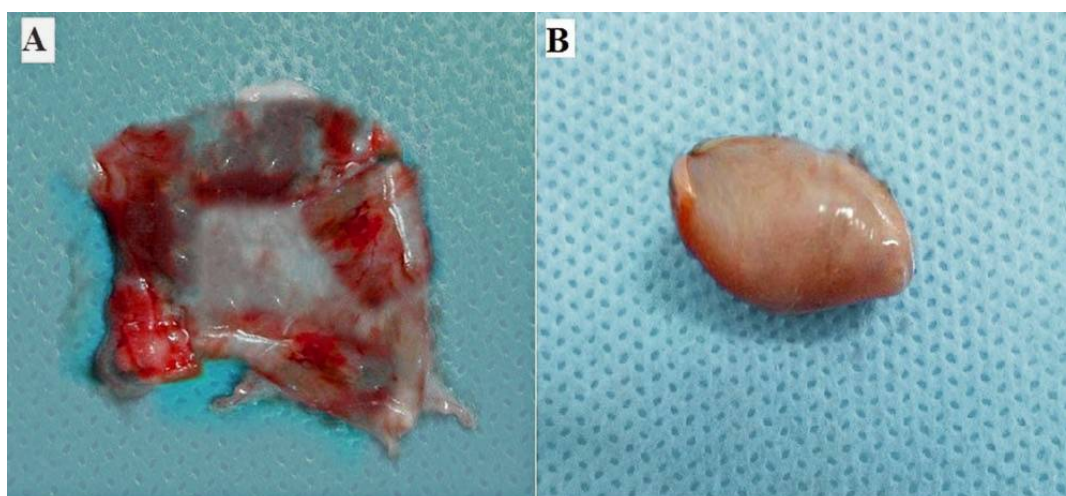


Figure 1: Cartilage implants. (A) Diced cartilage for wrapping with the fascia. (B) Fascia graft folded around the diced cartilage

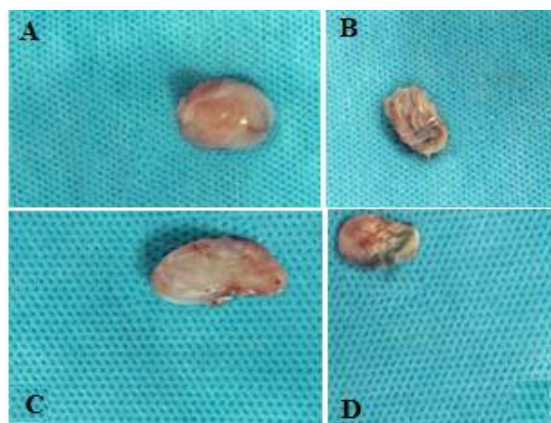


Figure 2: Photo of implants after 3 months. (A) and (C) = scopletin (SL)-treated group; (B) and (D) = control group

Histopathology examination

The tissue samples were dehydrated with ethyl alcohol and then cleaned with a solution of xylol. Next, the tissues were embedded in molten paraffin to obtain paraffin blocks and a microtome was used to cut the tissue into sections (5-mm thick); then they were stained with Masson's trichrome, toluidine blue, and hematoxylin and eosin (H&E). Histopathology of the tissue sections was performed under a light microscope; the chondroid tissues and viability of the chondrocytes were assessed with H&E staining, the connective tissues were examined with Masson's trichrome staining, and the viabilities of the chondrocytes and the chondroid tissue matrix metachromasia were estimated using toluidine blue staining. The grafts were evaluated based on the loss of chondrocyte nuclei in the lacuna, chondroid matrix status, and the life of the cartilage graft. Non-viable chondroid tissues were also evaluated for chondrocyte nuclei and loss of the matrix metachromasia.

The pathologist who evaluated the grafts was not aware of the group assignment when examining various factors such as fibrosis, basophilia, inflammation, metaplasia of bone, calcification, resorption, and graft life. Viable chondrocytes were assessed for viability in each specimen and considered as a percentage of the whole specimen. All parameters were scored on the following scale: 0 = negative, 1 = weak; 2 = moderate, and 3 = excessive.

Statistical analysis

All data are presented as means \pm standard deviation (SD; $n = 10$) and were statistically analysed with Student's t-tests (GraphPad Prism

6.1., CA, USA). $P < 0.05$ was considered to indicate statistical significance.

RESULTS

The effects of SL on the weights of the grafts are shown in Table 1. Compared to the application of saline, SL treatment increased the weights of the grafts following implantation. However, the pre- and post-implantation weights of the fascia-wrapped cartilage grafts did not significantly differ between the groups.

Table 1: Effects of SL on the weights of fascia-wrapped diced cartilage grafts before and after implantation

Group	Weights of fascia-wrapped diced cartilage graft (mg)	
	Before implantation	After implantation
Control	755.7 \pm 395.2	1095.3 \pm 629.5
SL-treated	752.2 \pm 421.5	1504.9 \pm 650.1

Data are presented as means \pm SD; ** $p < 0.001$ (vs. control group)

The effects of SL treatment on fibrosis, basophilia, inflammation, metaplasia of bone, calcification, resorption, and viability were also determined (Table 2). The SL group did not significantly differ from the control group in terms of fibrosis, inflammation, bone metaplasia, or calcification, but basophilia were up to 2.25-fold higher in the SL-treated group compared to the control group (0.85). Additionally, the resorption value significantly decreased in the SL-treated group (0.45) compared to the control group (2.1) and the SL group had a viability percentage of 82.9 %, while that of the control group was 42.1 %.

Table 2: Effect of SL on fibrosis, basophilia, inflammation, metaplasia of bone, calcification, resorption, and viability

Parameter	Control	SL-treated group
Fibrosis	0.59 \pm 0.72	0.63 \pm 0.75
Basophilia	0.85 \pm 0.52	2.25 \pm 0.71**
Inflammation	1.78 \pm 1.12	2.54 \pm 1.47**
Bone metaplasia	0.83 \pm 0.72	0.45 \pm 0.63**
Calcification	0.71 \pm 0.37	0.28 \pm 0.3**
Resorption	2.1 \pm 0.8	0.45 \pm 0.29**
Viability %	42.1 \pm 12.3	82.9 \pm 10.5**

Data are presented as means \pm SD; ** $p < 0.001$ (vs. control group)

The viability of the tissue sections was also significantly higher in the SL-treated group compared to the control group (Figure 3).

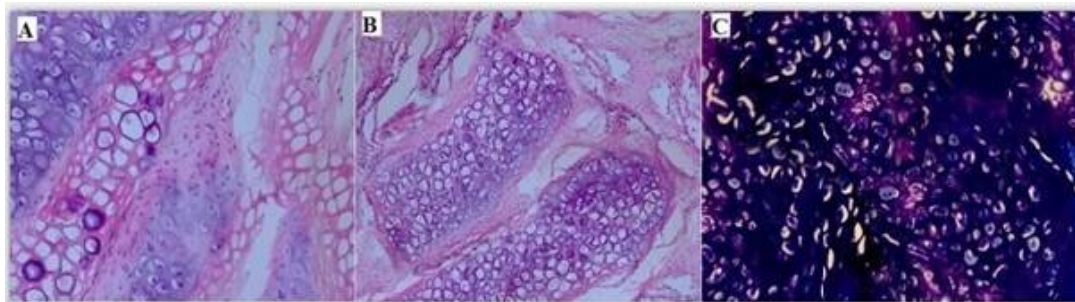


Figure 3: Stained tissue sections. (A) Control group with hematoxylin and eosin (H&E) staining: chondrocytes. (B) SL-treated group with H&E staining: chondrocytes. (C) SL-treated group with toluidine blue staining: metachromasia

DISCUSSION

A variety of factors, including a patient's current systemic status, oxygenation in the local tissue, surgical technique, graft size, and vascularised host bed, contribute to the survival of a cartilage graft. However, the resorption rate may be unpredictable even if the cartilage graft is placed under optimal conditions [16]. There are several techniques that can increase the survival of diced cartilage grafts, including the Turkish delight method described by Erol, which has proven effective and popular around the world [3]. Surgically wrapped diced cartilages exhibit various degrees of resorption; thus, it has been recommended that fascia be used to wrap diced cartilages. However, few surgeons suggest the use of AlloDerm for wrapping because the harvesting of fascia may cause hematoma and alopecia [17]. Additionally, block grafts have a higher viability than diced cartilage grafts and several medical agents, such as steroids and dimethyl sulfoxide, can be used to increase the resorption rate and viability of cartilage grafts [18].

It has been reported that SL exerts antitumor, antioxidant, and anti-inflammatory activities, inhibits the migration of endothelial cells, alters the production of cytokines, and changes the expression levels of COX-2. The intraperitoneal administration of SL significantly reduces the thickness of synovium and attenuates inflammation in joints. Additionally, SL activates caspase-3, which in turn induces apoptosis and cell arrest in tumour cells.

The viability of chondrocytes is higher following application of diced cartilage wrapped in fascia [19]. The present findings showed that SL significantly increased the viability of chondrocytes and decreased the resorption rate compared to a control group receiving saline. The present study also demonstrated that there was a post-implantation increase in the weights of the grafts in the SL-treated group compared to

the control group. Thus, the present findings suggest that fascia-wrapped diced cartilage grafts may benefit from the application of SL.

CONCLUSION

The findings of the study demonstrate that SL has beneficial and positive effects on fascia-wrapped diced cartilage grafts and may be of potential prophylactic application in cases of foreign matter reaction where there is an increase in resorption rate.

DECLARATIONS

Acknowledgement

The authors thank Tongji Hospital, Tongji Medical College, and Huazhong University of Science and Technology, China for providing the facilities for this study.

Conflict of Interest

No conflict of interest associated with this work.

Contribution of Authors

The authors declare that this work was done by the authors named in this article and all liabilities pertaining to claims relating to the content of this article will be borne by them.

Open Access

This is an Open Access article that uses a funding model which does not charge readers or their institutions for access and distributed under the terms of the Creative Commons Attribution License (<http://creativecommons.org/licenses/by/4.0>) and the Budapest Open Access Initiative (<http://www.budapestopenaccessinitiative.org/read>), which permit unrestricted use, distribution,

and reproduction in any medium, provided the original work is properly credited.

REFERENCES

- Hizal E, Buyuklu F, Ozer O, Cakmak O. Effects of different levels of crushing on the viability of rabbit costal and nasal septal cartilages. *Plast Reconstr Surg* 2011; 128: 1045–1051.
- Firat C, Gurlek A, Aydin NE. Viability of cartilage grafts in various forms. *J Craniofac Surg* 2011; 22: 1666–1670.
- Erol O. The Turkish delight: a pliable graft for rhinoplasty. *Plast Reconstr Surg* 2000; 105: 2229–2241.
- Daniel RK, Calvert JW. Diced cartilage grafts in rhinoplasty surgery. *Plast Reconstr Surg* 2004; 113: 2156–2171.
- Calvert J, Brenner K. Autogenous Dorsal Reconstruction: Maximizing the Utility of Diced Cartilage and Fascia. *Semin Plast Surg*. 2008 May; 22(2): 110–119.
- Li Y, Dai Y, Liu M, Pan R, Luo Y, Xia Y, Xia X., Scopoletin induces apoptosis of fibroblast-like synoviocytes from adjuvant arthritis rats by a mitochondrial-dependent pathway. *Drug Dev Res*, 2009; 70 (5): 378–385.
- Cheng AS, Cheng YH, Chang TL. Scopoletin attenuates allergy by inhibiting Th2 cytokines production in EL-4 T cells. *Food Function*, 2012; 3: 886–890.
- Pan R, Dai Y, Gao XH, Lu D, Xia YF. Inhibition of vascular endothelial growth factor-induced angiogenesis by scopoletin through interrupting the autophosphorylation of VEGF receptor 2 and its downstream signaling pathways. *Vasc Pharmacol*, 2011; 54: 18–28.
- Muschietti L, Gorzalczy S, Ferraro G, Acevedo C, Martino V. Phenolic compounds with anti-inflammatory activity from *Eupatorium buniifolium*. *Planta Med*, 2001; 67: 743–744.
- Ng TB, Liu F, Lu Y, Cheng CH, Wang Z. Antioxidant activity of compounds from the medicinal herb *Aster tataricus*. *Comp Biochem Physiol C Toxicol Pharmacol* 2003; 136: 109–115.
- Manuele MG, Ferraro G, Barreiro Arcos ML, Lo'pez P, Cremaschi G, Anesini C. Comparative immunomodulatory effect of scopoletin on tumoral and normal lymphocytes. *Life Sci* 2006; 79: 2043–2048.
- Ding Z, Dai Y, Wang Z. Hypouricemic action of scopoletin arising from xanthine oxidase inhibition and uricosuric activity. *Planta Med* 2005; 71:183–185.
- Kim EK, Kwon KB, Shin BC, Seo EA, Lee YR, Kim JS, Park JW, Park BH, Ryu DG. Scopoletin induces apoptosis in human promyeloleukemic cells, accompanied by activations of nuclear factor kB and caspase-3. *Life Sci* 2005; 77:824–836.
- Liu XL, Zhang L, Fu XL, Chen K, Qian BC. Effect of scopoletin on PC3 cell proliferation and apoptosis. *Acta Pharmacol Sin* 2001; 22:929–933.
- Guide for the Care and Use of Laboratory Animals: Eighth Edition Committee for the Update of the Guide for the Care and Use of Laboratory Animals; National Research Council. 2010; ISBN: 0-309-15401-4.
- Bhatt YC, Vyas KA, Tandale MS, Panse NS, Bakshi HS, Srivastava RK., Maxillonasal dysplasia (Binder's syndrome) and its treatment with costal cartilage graft: A follow-up study. *Indian J Plast Surg*. 2008; 41(2): 151–159.
- Kim HK, Chu LS, Kim JW, et al. The viability of diced cartilage grafts wrapped in autogenous fascia and AlloDerm in a rabbit model. *J Plast Reconstr Aesthetic Surg* 2011; 64: 193–200.
- Fann PC, Hartman DF, Goode RL. Pharmacologic and surgical enhancement of composite graft survival. *Arch Otolaryngol Head Neck Surg* 1993; 119: 313–319.
- Brenner KA, McConnell MP, Evans GR, Calvert JW. Survival of diced cartilage grafts: an experimental study. *Plast Reconstr Surg* 2006; 117: 105–115.