

Original Research Article

Accumulation of ^{99m}Tc -Methylene Diphosphonate Radiotracer in Rat's Forelimb

Gh Assadnassab

Department of Clinical Science, Faculty of Veterinary Medicine, Tabriz Branch, Islamic Azad University, Tabriz, Iran

*For correspondence: **Email:** assadnassabgh@iaut.ac.ir; **Tel:** +98 914 412 1145

Received: 7 December 2013

Revised accepted: 22 September 2014

Abstract

Purpose: To evaluate the efficacy and radioactivity counts of technetium-99m methylene diphosphonate (^{99m}Tc -MDP) radiotracer by scintigraphy.

Method: In this study, 7 healthy Wistar rats were anesthetized. Technetium was milked from molybdenum-technetium generator and added to methylene diphosphonate (MDP) kit. Scintigraphic scans were carried out in several areas of the rat's forelimbs by gamma camera 2 h after the injection of ^{99m}Tc -MDP via the tail vein. Accumulations of the radioisotope in the study areas were calculated using region of interest (ROI) technique.

Results: Mean count of radioisotope in the right and left sides of the shoulder area was 4179.29 and 4074.24, respectively; in the right and left sides of the elbow joint areas, the count was 1662.14, 1645.28, respectively. The count in the right and left sides of the carpal joint and finger areas was 1908.42 and 2028.28, respectively.

Conclusion: This study shows that ^{99m}Tc -MDP radiotracer can be used for survey radioactivity examination in different bones of the forelimb. Comparison of radioisotope counts in these areas can be used for the diagnosis of disease.

Keywords: Bone, Rat, Scintigraphy, Technetium, Methylene diphosphonate

Tropical Journal of Pharmaceutical Research is indexed by Science Citation Index (SciSearch), Scopus, International Pharmaceutical Abstract, Chemical Abstracts, Embase, Index Copernicus, EBSCO, African Index Medicus, JournalSeek, Journal Citation Reports/Science Edition, Directory of Open Access Journals (DOAJ), African Journal Online, Bioline International, Open-J-Gate and Pharmacy Abstracts

INTRODUCTION

Nuclear medicine (scintigraphy) is a technique used in diagnostic imaging. Nowadays, radioactive substances and gamma cameras are used in different medical centers for diagnostic purposes. This technique shows the anatomical and physiological functions and also the technique enables the diagnosis of disease from normal condition. In this technique, by injecting the radioactive substance into body, the substance congests in a particular part of body. This congestion can be registered and counted and portrayed by particular equipment like gamma revealer.

Bone scintigraphy is important in nuclear medicine because they have special effects in skeletal functions. Most of the radiotracers used in bone imaging are phosphate analogues that are labeled with technetium. Bone scintigraphic scans often detect the disease early and in comparison with other radiographic tests, larger lesions can be seen. Occasionally, these lesions on bone scans are nonspecific, but they are often important diagnostic keys for differential diagnosis [1,2].

Drawing on the literature and considering the biological effects of these radiotracer

substances, rats were used as the experimental model.

This study was designed to demonstrate the effect of using radioisotope activity on rat's forelimbs and to compare the counts of this material in these areas. It also attempts to count radioactive substance in the forelimb bones of rat as an experimental model. The uptake and effect of the radiotracer was also examined in several areas of the rat's forelimb.

EXPERIMENTAL

Materials

In this study, ADAC with two-head detectors gamma camera (Philips Inc.) of Vertex model was used. The methylene diphosphonate (MDP) kit, technetium-99m methylene diphosphonate (^{99m}Tc -MDP), and molybdenum-technetium generator used in the study were prepared and confirmed by the Atomic Energy Organization of Iran.

Animals

Seven healthy Wistar rats (3 female and 4 male; weight 190 - 220 g) were used in this study. To ensure their breed purity, they were purchased from a university laboratory. Blood experiments (CBC) and clinical examinations were done to make certain that they were healthy. Animals were housed in standard polypropylene cages at a temperature of 24 ± 3 °C, with free access to food and water. Examinations were carried out following the institutional Ethical Committee guidelines, "Principles of Laboratory Animal Care" (in accordance with National Institutes of Health Publication no. 85-23, 1985) in the Faculty of Veterinary Medicine, Tabriz Branch, Islamic Azad University, Tabriz City, Iran [3,4].

Functional method

Rats were anesthetized by Ether (Merck, Germany) in a particular lacuna. Then their tail veins were detected by surgery in standard methods.

The radioisotope used technetium was milked from molybdenum- technetium generator and then added to methylene diphosphonate kit.

The prepared ^{99m}Tc -MDP radiotracer was quickly injected into the tail vein at a dose of 2 mCi with an insulin syringe which had been kept in a lead shield. After the injection, the secondary activity of Insulin syringe was evaluated by the same counter machine (Capintec, USA). Thereafter,

the animals were returned to their cages and cared for. After 2 h, four rats were anesthetized with Ether and others by Ketamine drug (Alfasan, Woerden, Holland) (100 mg/kg) and Xylazine (Alfasan, Woerden, Holland) as well as pre-anesthetic medication with a dose of 50 mg/kg [5].

The animals were positioned on the table with hands and feet stretched (thin strings were used to keep them steady) before the scan was performed. After adjusting the gamma camera near the forelimb and focusing the detector device, scintigraphy images were obtained from animals on both sides (Fig 1). Scintigraphy scans were prepared by adjusting the detector of camera on the target parts in static way. For counting to be carried out efficiently, a lead shield was used around the tail. This procedure was also applied in the qualitative and quantitative gamma camera studies with using region of interest (ROI) technique.

Thus, ROIs were drawn on imagining scans in both the right and left parts (Fig 1) and count variations were calculated at time intervals within these ROIs. The resultant curve was plotted by a computer through drawing lines around every mentioned target parts and also drawing backgrounds of each. Total count time was 2 min and total radioisotope count was 500 kcount.

Statistical analysis

Ultimately, the counted values of the right and left sides were compared. Statistical Package for Social Sciences (SPSS) version 17.0 was employed for data analysis. Paired sample t-test was used to determine the differences in the data for the right and left limbs from different areas. Confidence level was set at $p < 0.05$.

RESULTS

In this study, counting of radioactive material was done and recorded by a gamma camera and computer after injecting the prepared radioisotope ^{99m}Tc -MDP in different parts of rat's forelimbs (Table 1).

Table 1: The count of radioactivity after injection of ^{99m}Tc -MDP radiotracer in different areas of rat forelimb

Area	Right	Left
Shoulder joint	4179.29	4074.28
Elbow joint	1662.14	1645.28
Carpal joint and fingers	1908.42	2028.28

The counts of the right structures were not significantly different from the left one in each animal ($p > 0.05$)

This study shows that absorption of radioisotope in bone areas was higher hyperactive areas) than in soft tissue areas which are easily seen in the other image (Fig 1).

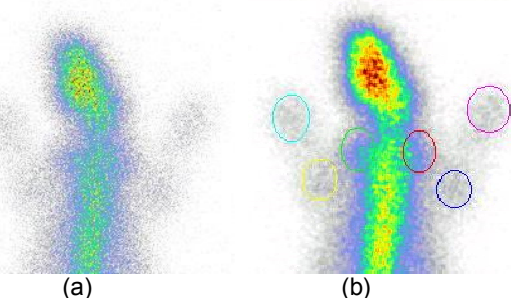


Figure 1: Dynamic scanned images 2 h after intravenous injection of radioactive materials in rats (a) and ROIs drawn on the scanned photo in measured areas of rat's forelimbs (b)

DISCUSSION

This study entailed bone scintigraphic scanned images of rats and drawing of time to activity curves. Scintigraphy is applicable to animals and this survey uses rats in radioactive experimental studies. Radiotracers can be used in animals [6-8] and scintigraphy has been done in the laboratory and on small animals [9-11].

Scintigraphy is one of the most important diagnostic imaging techniques. Absorption of radioisotope in some areas is higher than in other areas and is recognizable in images which conform to other studies. This study shows that bone areas with higher radioactivity show like hyperactive areas which are easily separated from other soft areas [1,2,12].

Computer scans and conventional medical integrating software are readily applicable with animals and do not cause any particular problem in this field but we must adjust the magnification of the machine to the highest possible range. Counting of radioactive materials in received scanned images is easily done with accuracy.

Based on the definition and labeling colors near the images, we can reveal the areas with radioactive absorption and this conforms to other studies [1,7]. In forelimbs, areas with more hyperactivity like bone and joints are observable as seen in other studies [2,12,13].

In this study, the shoulder joint area has the highest count of all the counted areas. Thickness of the bones in this area may be a factor.

Counting results differ from one animal to another. So we must compare the numbers of counts only with the opposite organ at the same animal. Comparing the numbers of the same organs of different animals or with other organs of the same animal is not correct [14,15]. In this study, counts of the right structures were not significantly different from the left one in each of the rats ($p > 0.05$).

According to this study, scintigraphy technique is applicable in bone observation and detection of bone disease, as shown by some researchers. Scintigraphy not only produces descriptive structures but also is usable in evaluating functional and physiological activities [1,6]. This study shows the physiological work of bones. Thus, nuclear medicine techniques useful in physiological studies in animals.

The findings of this study are in agreement with the reports presented by other researchers on the effects of using scintigraphy in rats. The findings also suggest that ^{99m}Tc -MDP could be used in the scintigraphy of rat's bone, as revealed by some other studies [14,15].

To the best of our knowledge, no side effects (e.g., non-responding of bones' reaction to the radiotracer, allergy or mortalities) have yet been reported for the use of this radioactive material.

Examination of the scanned photos shows that bone scintigraphy can diagnose the special bone disease conforming with other studies [6,12,15]. This study shows that scintigraphy of the rats has more resemblance with human bone scintigraphy [1,2]. Computer software, model scanning, assemblage of photos and drawing ROIs are easily applicable to this animal. Quantification of radioactivity is easy and can be done with computer gamma camera software accurately.

This study shows that drawing of ROIs in rat can be made simple by this technique and can be done by computer software. Executive and time process steps of computer scintigraphy of the rat's bone is similar to it in humans being [1,2]. This study, which indicates uptake of radiotracer in the target organs, suggests that using radioisotope radioactivity in forelimbs and comparing the counts of this material in the areas can be useful in the diagnosis of diseased.

Lastly, scintigraphy is a useful diagnostic imaging method in veterinary medicine, and animals like rats can be used as specific models in research in both human and veterinary medicine.

CONCLUSION

The findings of this study show that animals can be used as an experimental model in nuclear medicine studies and that bone scintigraphy can play an important role in human and veterinary medicine research because they have special effects on skeletal functions. Using this technique, diagnosis of disease can be facilitated by comparing radiotracer counts of normal and diseased states.

ACKNOWLEDGEMENT

The author appreciates the clerks and chief of Dr Dabiri Nuclear Center, especially Dr. Shahram Dabiri Oskoie, Dr Babak Mahmoudian and Dr. Esmail Garapapagh, and would also like to thank Tabriz Branch, Islamic Azad University, Research Department, Tabriz, Iran for its support.

REFERENCES

1. Henkink R, Boles M, Dillehay G, Eds. *Nuclear Medicine*. St Louis: Mosby – Year Book 1996; pp 1055-1090.
2. Mettler F. *Essentials of Nuclear Medicine Imaging*, 4th edn. Philadelphia: Saunders 1998; pp 335-356.
3. Hallenbeck JM, Dutka AJ, Kochanek PM, Siren A, Pezeshkpour GH, Feuerstein G. Stroke risk factors prepare rat brainstem tissues for modified local Schwartzman reaction. *Stroke* 1988; 19: 863-869.
4. *Guide for the Care and Use of Laboratory Animals*. Washington, DC: Government, Printing Office, NIH Publication 1985; p 23.
5. Hau J, Hoosemi LV, editors. *Handbook of Laboratory Animal Science*. 2th edn. London: CRC Press 2002; pp 250-300.
6. Chow PL, Stout DB, Komisopoulou E, Chatziioannou AF. A method of image registration for small animal, multi-modality imaging. *Phys Med Biol* 2006; 51: 379-390.
7. Furumoto S, Takashima K, Kubota K, Ido T, Iwata R, Fukuda H. Tumor detection using 18F-labeled matrix metalloproteinase-2 inhibitor. *Nucl Med Biol* 2003; 30: 119-125.
8. Heck LL. Extra- osseous localization of phosphate bone agents. *Semin Nucl Med* 1980; 10: 311-312.
9. Beekman FJ, Van der Have F, Vastenhouw B, Van der Linden AJ, Van Rijk PP, Burbach JP, Smidt MP. U-SPECT-I: a novel system for submillimeter-resolution tomography with radiolabeled molecules in mice. *J Nucl Med* 2005; 46: 1194-1200.
10. El-Deen ME, Khalaf I, Rahim FA. Effect of internal ureteral stenting of normal ureter on the upper urinary tract: an experimental study. *Scintigraphic imaging with 99mTc- exorphin C in rabbits*. *J Endourol* 1993; 7: 399-405.
11. Gomes ML, de Mattos DM, Freitas RS, Dire GF, Lima EA, Souza SM, Bernardo-Filho M. Evaluation of the effect of mitomycin-C on the bioavailability of technetium-99m-labelled sodium pyrophosphate in mice. *Cell Mol Biol* 2002; 48: 757-759.
12. Silberstein EB, Francis MD, Tofe AJ, Slough CL. Distribution of 99mTc-Sn diphosphonate and free 99mTc-pertechnetate in selected soft and hard tissues. *J Nucl Med* 1975; 16: 58-61.
13. Horiuchi-Suzuki K, Konno A, Ueda M, Fukuda Y, Nishio S, Hashimoto K, Saji H. Skeletal affinity of Tc(V)-DMS is bone cell mediated and PH dependent. *Eur J Nucl Med Mol Imaging* 2004; 31: 388-398.
14. Wirrwar AK, Nikolaus S, Schramm NU, Arkian S, Cohnen M, Muller HW. TierSPECT: performance of a dedicated small-animal-SPECT camera and first in vivo measurements. *Z Med Phys* 2005; 15: 14-22.
15. Ostendorf B, Scherer A, Wirrwar A, Hoppin JW, Lackas C, Schramm NU, Cohnen M, Modder U, Van den Berg WB, Muller HW et al. High-Resolution Multipinhole Single-Photon-Emission Computed Tomography in Experimental and Human. *Arthritis & Rheumatism* 2005; 54: 1096–1104.