

# Traumatic transperineal delivery, a tragedy in unassisted vaginal delivery: A case report and review of literature

**RABIU A, AHMED ZD, YOLA AI<sup>1</sup>**

Department of Obstetrics and Gynaecology, Bayero University Kano/Aminu Kano Teaching Hospital, <sup>1</sup>Laure Fistula Centre, Murtala Muhammad Specialist Hospital, Kano, Nigeria

### ABSTRACT

Transperineal delivery is a traumatic childbirth whereby the baby is forcefully ejected out through a contraction and pushing-induced laceration of the perineum in the presence of intact vaginal and anal orifices. We presented a 23-year-old primipara who presented 3 days after delivery with infected perineal injury and pains following unsupervised childbirth. She delivered a fresh stillborn baby through the perineum (between the fourchette and the anal orifice). She was, however, continent of urine and feces. She was optimized and repair of the perineal injury was scheduled after puerperium. The postoperative condition was satisfactory. We therefore call and appeal on the relevant stakeholders, to provide more skilled birth attendants, especially at the densely populated areas and ensure their presence and willingness to participate in conducting all deliveries with good supervision in all health facilities, so as to prevent future occurrence of transperineal delivery.

**Key words:** Nigeria; perineal tear; transperineal delivery; traumatic childbirth.

### Introduction

Transperineal delivery is defined as a traumatic childbirth whereby the baby is forcefully ejected out through a contraction and pushing-induced laceration of the perineum in the presence of intact vaginal and anal orifices. This obstetric tragedy has become totally extinct or nonexistence in the scientific literature. Data on obstetric deliveries in the developed nation and countries with good maternal health indices are totally devoid of this disfiguring condition. Conversely, in Sub-Saharan Africa, Nigeria in particular, where figures for antenatal coverage and delivery by a skilled birth attendants (SBAs) (60.9% and 38%, respectively)<sup>[1,2]</sup> are far below the recommended figures, pregnant women are at risk of unassisted vaginal delivery with lasting consequences of perineal injuries.

The concept of “hands-off” delivery whereby a woman in the second stage of labor is allowed to deliver unassisted without

guarding the perineum without assessment for the need of episiotomy is still in the mind of some healthcare providers. This will invariably hinder total elimination of this condition. We present to you a case of traumatic transperineal delivery.

### Case Report


She was a 23-year-old, Hausa Muslim housewife with secondary school level of education. She was a primipara and presented 3 days after delivery with perineal injury and pains following childbirth. The preceding pregnancy was booked elsewhere. She had three antenatal visits before she was self-referred to Kano for delivery close to her parent. She presented to Murtala Muhammad Specialist Hospital

**Address for correspondence:** Dr. Rabiu A, Department of Obstetrics and Gynaecology, Bayero University Kano/Aminu Kano Teaching Hospital, P.M.B. 3011, Nigeria. E-mail: ayyubarabiu@yahoo.com

This is an open access journal, and articles are distributed under the terms of the Creative Commons Attribution-NonCommercial-ShareAlike 4.0 License, which allows others to remix, tweak, and build upon the work non-commercially, as long as appropriate credit is given and the new creations are licensed under the identical terms.

**For reprints contact:** reprints@medknow.com

**How to cite this article:** Rabiu A, Ahmed ZD, Yola AI. Traumatic transperineal delivery, a tragedy in unassisted vaginal delivery: A case report and review of literature. Trop J Obstet Gynaecol 2019;36:301-3.

Access this article online	
<b>Website:</b> www.tjogonline.com	<b>Quick Response Code</b> 
<b>DOI:</b> 10.4103/TJOG.TJOG_94_18	

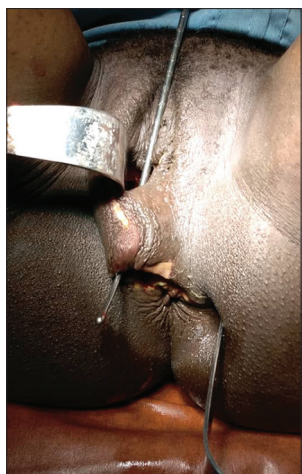


Figure 1: Transperineal tear with intact vaginal and anal orifices

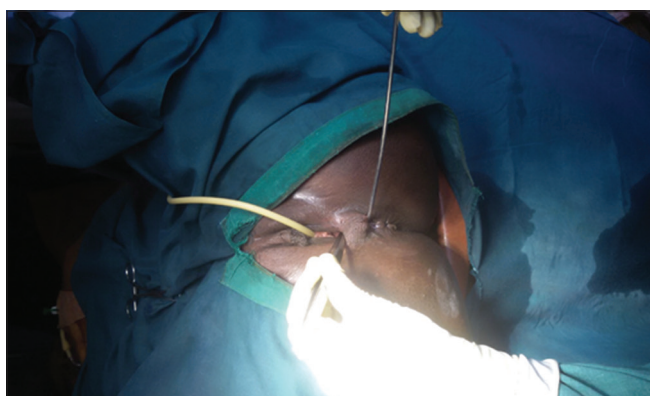


Figure 2: Transperineal tear after puerperium

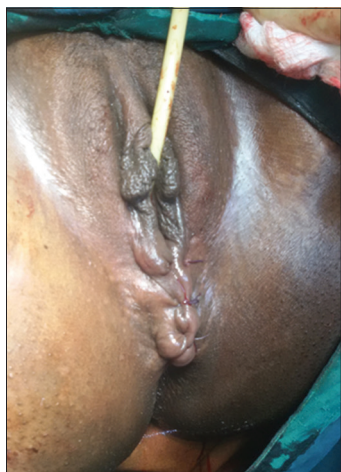

Figure 3: Repaired transperineal tear

with complaints of labor pains and drainage of liquor for 24 h. She was immediately reviewed and referred to Jakara Hospital due to lack of bed space. At the referred hospital, she was reviewed and admitted by a midwife. Four hours into admission, she had the urge to bear down but there was no SBA to assist her in the second stage of labor. She delivered a fresh stillborn baby through the perineum (between the

fourchette and the anal orifice) [Figures 1 and 2]. She was continent of urine and feces.

She was found to be a young woman, not pale (packed cell volume (PCV) 34%), afebrile. Her pulse rate and blood pressure were normal. There was suprapubic fullness and the uterus was about 16 weeks, firm and well-contracted. Perineal examination revealed intact vaginal and anal orifices with a deep laceration in the perineum measuring about 4–3 cm. The laceration communicated from the perineal skin to the mid posterior vaginal mucosa.

She was counseled on her condition and was commenced on antibiotics, hematinics, and analgesics. She was instructed on perineal hygiene and asked to come for repair in 6 weeks time.

She was admitted 6 weeks after delivery. She was examined and the findings confirmed perineal tear (with good perineal hygiene) secondary to transperineal delivery. She was counseled for the findings, the diagnosis, and the need for surgical repair. A client media released consent, and consent for the surgery was sought and obtained.

A spinal anesthesia was administered. She was placed in lithotomy position. A size 16 G Foley catheter was passed. The perineum was cleaned and draped. A midline longitudinal incision was made on the fourchette which was extended downward until it communicated with the transperineal laceration. A blunt dissection was made to separate the posterior vaginal mucosa off the perineal muscles. The edges of the mucosa were trimmed. The defect was closed with interrupted sutures using vicryl 1. The vaginal mucosa was repaired with vicryl 2/0. The perineal skin was repaired with mattress sutures using vicryl 2/0. The procedure was well-tolerated [Figure 3]. Postoperative condition was satisfactory. She was discharged 5 days after the procedure and was counseled on the need for family planning, abstinence from sexual intercourse for at least 3 months, and the need for future pregnancies to be managed in a well-equipped hospital with SBAs who are well-motivated to conduct deliveries with good supervision.

## Discussion

Childbirth is often faced with tragedy in developing countries especially with rapid uncontrolled population growth and the limited, mal-distributed number of health workers. Kano, the most populous state in Nigeria with an estimated population of 12,757,211 people, has a high maternal mortality ratio of 1,025 deaths per 100,000 live births.<sup>[3]</sup> The antenatal care coverage was also low, which was reported to stand at 64.3%,

and facility-based delivery rate by SBAs was at 12.9% (NDHS 2013).<sup>[4]</sup> Reports from the National Demographic Health Survey in 2013 showed that the total fertility rate was also high amounting to 6.8%.<sup>[4]</sup> As a result of these poor maternal indices, challenges such as delivery at home attended by traditional birth attendants and hospital delivery unattended by SBA do occur which predispose to transperineal delivery. This patient attended secondary school level of education. She booked for antenatal care. Delivery was planned to be conducted in a nearby hospital close to her parent. Unfortunately, for her, there was no available bed space at the hospital she planned to deliver which necessitated referral to a nearby hospital. By the time she reached the nearby hospital, she was reviewed by a midwife. When she was in second stage of labor, she had the urge to bear down but there was no SBA to assist the delivery. She ultimately delivered and sustained the birth trauma. This showed that this patient avoided risk factors of perineal tears such as illiteracy and unbooked status, and she addressed the issues related to birth preparedness and complication readiness but due to lack of adequate number of SBAs, she sustained this perineal tear following unassisted vaginal delivery. The issues of lackadaisical attitudes of some health workers, and the belief in hands-off where by a pregnant woman in labor is allowed to deliver unassisted could have contributed to this transperineal traumatic delivery.

Trends over the years (1990–2013) on the use of SBAs in Nigeria have shown that there was very low utilization, barely at one-third usage with insignificant changes over these period.<sup>[5]</sup> Women empowerment, including decision-making power and residence, would certainly be the strongest determinants of SBA use. To overturn poor child and maternal health outcomes in Nigeria through SBA use, efforts should be targeted toward improving girl child education, sexual and reproductive health education, and accessible and improved healthcare facility services.<sup>[5]</sup>

Following the delivery, the secondary referral was early in this patient. An assessment and diagnosis was made. She was counseled on the needs for antibiotics, analgesics, perineal hygiene, and ultimate surgical repair after puerperium. This

was done to ensure adequate wound healing without further scarred tissue formation and recto vaginal fistula formation. A midline incision commencing from the fourchette to the wound was done to determine the wound extent, to reflect the posterior vaginal mucosa, and to repair the wound with good restoration of the anal sphincteric function.

We therefore call on the relevant stakeholders to provide more SBAs especially at the densely populated areas and ensure their presence and willingness to participate in conducting all deliveries with good supervision in all health facilities, so as to prevent future occurrence of transperineal delivery.

#### Declaration of patient consent

The authors certify that they have obtained all appropriate patient consent forms. In the form the patient(s) has/have given his/her/their consent for his/her/their images and other clinical information to be reported in the journal. The patients understand that their names and initials will not be published and due efforts will be made to conceal their identity, but anonymity cannot be guaranteed.

#### Financial support and sponsorship

Nil.

#### Conflicts of interest

There are no conflicts of interest.

#### References

1. Federal Ministry of Health N (FMoH). National HIV/AIDS and Reproductive Health and Serological Survey, 2012 (NARHS Plus). Abuja, Nigeria: Federal Ministry of Health; 2013.
2. National Population Commission (Nigeria) and ICF International: Nigeria Demographic and Health Survey 2013. Abuja, Nigeria; 2014.
3. MNCH2. Kano; History [Internet]. 2018. Available from: <http://www.mnch2.com/kano-state/>. [Last accessed on 2019 Jun 28].
4. Nigeria Demographic and Health Survey (NDHS) [Internet]. 2013;1–565. Available from: <https://dhsprogram.com/pubs/pdf/FR293/FR293.pdf>. [Last accessed on 2019 Jun 28].
5. Fagbamigbe A, Hurricane-Ike E, Yusuf O, Idemudia E. Trends and drivers of skilled birth attendant use in Nigeria (1990-2013): Policy implications for child and maternal health. *Int J Womens Health* 2017;9:843-53.