

# The incidence of retained fetal bones after 1,002 hysteroscopies in an environment with restrictive abortion laws

JUDE OKOHUE

Fertility and Endoscopy Unit, Gynoscope Specialist Hospital, Rivers State, Nigeria

## ABSTRACT

**Background:** Retained fetal bones within the uterine cavity are rare. The incidence in an environment with restrictive abortion laws is however unknown.

**Aim:** To document the incidence of retained fetal bones in an environment with highly restrictive abortion laws.

**Methods:** Case records of patients who had hysteroscopy on account of retained fetal bones from April 1, 2010 to March 31, 2017 were retrieved. Data including age, number of terminations of pregnancy, gestational age at termination of pregnancy, duration of infertility, and treatment outcome were retrieved.

**Results:** A total of 1,002 patients had hysteroscopy for various indications. Of these, 26 patients had retained fetal bones giving an incidence of 0.26%. The age range of the patients was 28--42 years, mean  $34.7 \pm 4.6$  SD. Duration of infertility ranged from 2 to 8 years, mean  $4.6 \pm 2.3$  SD. The number of terminations of pregnancy ranged from 1 to 6, mean  $2.6 \pm 1.7$  SD. One patient had an unexplained intrauterine fetal death of one of a set of twins at 20 weeks gestation with subsequent elective cesarean section at 37 weeks gestation. All the cases had histological confirmation of fetal bones. Of the 24 patients who had secondary infertility, 6 (25.0%) achieved spontaneous pregnancies. Eight women underwent *in vitro* fertilization treatment with 2 (25%) clinical pregnancies.

**Conclusion:** The incidence of intrauterine retained fetal bones in our environment with highly restrictive abortion laws is 0.26%. A review of these laws is probably long overdue.

**Key words:** Fetal bones; hysteroscopy; incidence.

## Introduction

Fetal bones are rarely found within the uterine cavity. Although they have been reported to mostly follow retained bone fragments, there are cases suspected to be due to metaplasia of mature endometrial stromal cells following chronic inflammation or trauma.<sup>[1,2]</sup> Fetal skeleton begins to develop bones from about 13 weeks of gestation. Second trimester termination of pregnancy can therefore either be performed by dilatation and evacuation or with the use of medical agents.<sup>[3]</sup> Dilatation and evacuation can be associated with retained fetal bones, limiting its role in modern gynecological practice.<sup>[4]</sup>

In most developing countries such as Nigeria, abortion services are restricted or unaffordable, limiting the access of women to such services.<sup>[5]</sup> This leads to unsafe abortion and its sequelae, including retained fetal bones.<sup>[3]</sup>


Although the true incidence of intrauterine retained fetal bones is unknown, Makris *et al.* reported an incidence of

**Address for correspondence:** Dr. Jude Okohue, Gynoscope Specialist Hospital, Number 22/24, Gynoscope Drive, Port Harcourt, Rivers State, Nigeria.  
E-mail: judosca@yahoo.com

This is an open access journal, and articles are distributed under the terms of the Creative Commons Attribution-NonCommercial-ShareAlike 4.0 License, which allows others to remix, tweak, and build upon the work non-commercially, as long as appropriate credit is given and the new creations are licensed under the identical terms.

**For reprints contact:** reprints@medknow.com

**How to cite this article:** Okohue J. The incidence of retained fetal bones after 1,002 hysteroscopies in an environment with restrictive abortion laws. Trop J Obstet Gynaecol 2019;36:249-51.

Access this article online	
<b>Website:</b> www.tjogonline.com	<b>Quick Response Code</b> 
<b>DOI:</b> 10.4103/TJOG.TJOG_91_18	

0.15% among 2,000 diagnostic hysteroscopies in Greece, a country with liberal abortion laws.<sup>[6]</sup>

The incidence of retained fetal bones in a resource-poor setting with highly restrictive abortion laws remains unknown.

### Aim

To document the incidence of retained fetal bones in an environment with restrictive abortion laws.

### Setting

A private fertility unit in the Niger-Delta region of Nigeria offering hysteroscopy services with referrals from the South-south and South-eastern parts of the country.

### Methods

Case records of patients who had hysteroscopy on account of retained fetal bones from April 1, 2010 to March 31, 2017 were retrieved. Data including age, number of terminations of pregnancy, gestational age at termination of pregnancy, duration of infertility, and treatment outcome were retrieved.

### Results

A total of 1,002 patients had hysteroscopy for various indications. Of these, 26 patients had retained fetal bones giving an incidence of 0.26%. Two (7.7%) of the patients were single while the remaining 24 (92.3%) patients presented with secondary infertility.

As shown in Table 1, the age range of the patients was 28–42 years, mean  $34.7 \pm 4.6$  SD. Duration of infertility ranged from 2 to 8 years, mean  $4.6 \pm 2.3$  SD. The number of terminations of pregnancy ranged from 1 to -6, mean  $2.6 \pm 1.7$  SD. One patient had an unexplained intrauterine fetal death (IUID) of one of a set of twins at 20 weeks gestation with a subsequent elective cesarean section at 37 weeks gestation.

Following hysteroscopic bone retrieval, three women (11.5%) had repeat hysteroscopies to remove missed fetal bones.

All the cases had histological confirmation of fetal bones. Of the 24 patients who had secondary infertility, 6 (25.0%)

achieved spontaneous pregnancies. Eight women underwent *in vitro* fertilization treatment with 2 (25%) clinical pregnancies.

### Discussion

Nigeria, with a land mass of close to a million square kilometers, is divided into six geopolitical zones and has an estimated population of over 190 million people.<sup>[7]</sup> Our unit receives referrals mainly from the South-south and South-eastern geopolitical zones of the country.

The incidence of retained fetal bones from our findings was 0.26%. This was more than the 0.15% reported by Makris *et al.* in Greece, although they had a higher patient population of 2000.<sup>[6]</sup> The higher incidence is however not surprising. Greece, a European country, has more liberal abortion laws.<sup>[8]</sup> As in 2007, it was reported that the abortion rate in Greece was 7.2 abortions per 1,000 women aged 15–44 years.<sup>[9]</sup> This is much lower than the 33 abortions per 1,000 women aged 15–49 years in Nigeria.<sup>[10]</sup> Studies have shown that countries like Nigeria with highly restrictive abortion laws tend to have higher abortion rates.<sup>[11]</sup> These illegal abortions are responsible for an estimated 20,000 maternal deaths from unsafe abortions annually in Nigeria.<sup>[12]</sup> Apart from one case in our study that had an IUID, all the others had dilatation and evacuation for termination of a second trimester pregnancy. This further confirms the dangers inherent with second trimester termination of pregnancy. In a study in Benin City, Nigeria, it was found that over 70% of abortions were performed by dilatation and curettage, with the same percentage of women reporting having at least one previous termination of pregnancy.<sup>[13]</sup> The mean number of termination of pregnancy in our study was  $2.6 \pm 1.7$  SD. All the cases we reviewed were diagnosed via transvaginal ultrasound scans as echogenic lesions within the endometrial cavity.

Retained fetal bones are known to cause secondary infertility.<sup>[14]</sup> This was manifested in the 24 (92.3%) patients who presented with variable durations of secondary infertility that ranged from 2 to 8 years as shown in Table 1. In a systematic review by Peirera *et al.*, infertility was the most common (72.9% of cases) presentation among women with retained fetal bones.<sup>[14]</sup> Although reports in the literature suggest that presentation can be in the form of secondary infertility, irregular vaginal bleeding, vaginal discharge, and passage of fetal bones, only 4 (15.4%) of the patients complained of spontaneous passage of fetal bones in our study.<sup>[15–17]</sup> One patient had an intrauterine fetal death of one of a set of twins at 20 weeks gestation. She presented with copious vaginal discharge 2 years after delivery by cesarean section, with ultrasound scan findings suggestive of retained intrauterine fetal bones. This was confirmed at hysteroscopy. She underwent two hysteroscopic procedures to remove the fetal bones. It was not

**Table 1: Demographics of patients with retained fetal bones**

Parameter	Range (mean $\pm$ SD)
Age	28–42 years ( $34.7 \pm 4.6$ )
Duration of infertility	2–8 years ( $4.6 \pm 2.3$ )
Gestational age at TOP	13–26 weeks ( $14.6 \pm 2.9$ )
Number of previous TOP	1–6 ( $2.6 \pm 1.7$ )

TOP, Termination of pregnancy

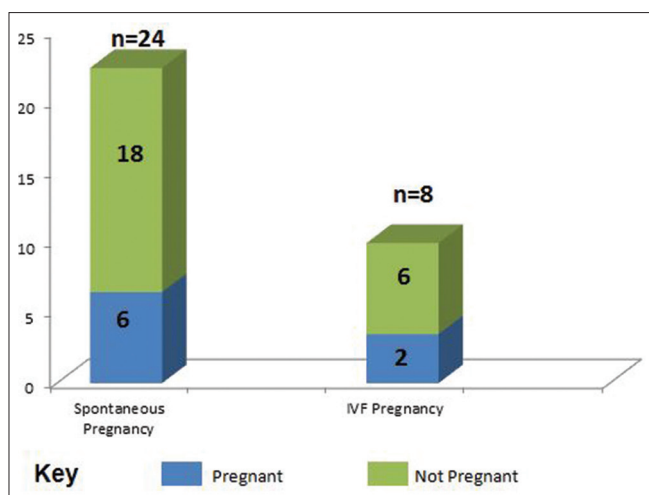


Figure 1: Outcome following hysteroscopic bone retrieval

clear why the bones were missed at cesarean section. While some obstetricians routinely clean the uterine cavity after delivery of the placenta at cesarean section, others do not. A recent report from researchers at the Michigan State University Sparrow hospital found a nonsignificant reduction in the rates of endomyometritis and sepsis involving the tissues of the uterus in patients who had routine cleaning of the uterine cavity.<sup>[18]</sup> It is possible the uterine cavity was not cleaned out in this case of retained fetal bone.

Elford and Claman suggested dilatation and curettage with intraoperative abdominal ultrasound guidance for removal of the fetal bones.<sup>[19]</sup> Bakshi *et al.* suggested a diagnostic hysteroscopy followed by an operative hysteroscopy with resectoscopic removal of the retained bones.<sup>[20]</sup> All our patients had hysteroscopic removal with a hysteroscopic grasping forceps, three patients required a repeat procedure.

The successful removal of the fetal bones should lead to conception if there are no other causes of infertility. As shown in Figure 1, there was a 25% spontaneous pregnancy rate following hysteroscopic removal of the fetal bones. Eight patients were found to have indications for IVF treatment and subsequently underwent assisted reproduction. Only 2 patients (25%) achieved clinical pregnancy. One pregnancy was carried to term and delivered via spontaneous vaginal delivery and the other ended as a spontaneous miscarriage at 9 weeks gestation.

## Conclusion

We have been able to establish the incidence of intrauterine retained fetal bones in our environment with highly restrictive abortion laws to be 0.26%. A review of these highly restrictive laws is probably long overdue.

## Financial support and sponsorship

Nil.

## Conflicts of interest

There are no conflicts of interest.

## References

- Graham O, Cheng L, Parson's J. the ultrasound diagnosis of retained fetal bones in West African patients complaining of infertility. *Br J Obstet Gynecol* 2000;107:122-4.
- Allahbadia GN, Tibrewala S, Mangeshkar P, PaiDhungat PB, Desai SK. Prolonged intrauterine retention of fetal bones after abortion-vagino sonographic diagnosis and hysteroscopic removal. *Singapore J Obstet gynecol* 1996;27:83-6.
- Okohue JE. Adhesions and abortion. In: Tinelli A, Alonso Pacheco L, Haimovich S, editors. *Hysteroscopy*. Cham, Switzerland: Springer; 2018. p. 697-708.
- Srofenyoh EK, Addison M, Dortey B, Kuffour PA. Intrauterine retained fetal bones as a cause of secondary infertility. *Ghana Med J* 2006;40:105-9.
- Leke RJ. The tragedy of induced abortion in sub-Saharan Africa. In: Boniface T, editor. *Contemporary Health Issues in Africa*. Luxemburg: Harwood Academic; 1994. p. 281-92.
- Makris N, Stefanidis K, Loutradis D, Anastasiadou K, Hatjipappas G, Antsaklis A. The incidence of retained fetal bone revealed in 2000 diagnostic hysteroscopies. *JSLs* 2006;10:76-7.
- Nigeria population 2018. Available from: <http://worldpopulationreview.com/countries/nigeria-population/>. [Last accessed on 2018 Sep 24].
- Ioannidi-Kapoulou E. Use of contraception and abortion in Greece: A review, *reproductive health matters* 2004;12:174-83.
- World abortion policies 2013. United nations department of economic and social affairs. Population division. Available from: <https://www.un.org/en/development/desa/population/publications/policy/world-abortion-policies-2013.shtml>. [Last accessed on 2018 Sep 24].
- Bankole A, Adewale IF, Hussain R, Awolude O, Singh S, Akinyemi JO. The incidence of abortion in Nigeria. *Int Perspect Sex Reprod Health* 2015;41:170-81.
- Sedgh D, Bearak J, Singh S, Bankole A, Popinchalk A, Ganatra B, *et al.* Abortion incidence between 1990 and 2014: Global, regional, and subregional levels and trend. *Lancet* 2016;388:258-67.
- Okonofua FE, Hamed A, Abass T, Mariga AG, Mohammed AB, Adewale A, *et al.* Private medical providers' knowledge and practices concerning medical abortion in Nigeria. *Stud Fam Plan* 2011;42:41-50.
- Enabudoso EJ, Gharoro EP, Ande ABA, Ekpe UP, Okohue JE. Five years review of complicated induced abortions in university of Benin teaching hospital, Benin City. *Benin J Postgrad Med* 2007;9:13-21.
- Pereira MC, Vaz MM, Miranda SP, Araujo SR, Menezes DB, Medeiros F. Uterine cavity calcifications: A report of 7 cases and a systematic literature review. *JMIG* 2014;21:346-52.
- Dutt S. Endometrial ossification associated with secondary infertility. *Br J Obstet Gynecol* 1978;85:787-9.
- Melius FA, Julian TM, Nagel TC. Prolonged retention of intrauterine bones. *Obstet Gynecol* 1991;78:919-21.
- Ikechebelu JI, Eleje GU, Eke NO. Hysteroscopic removal of retained intrauterine fetal bone causing chronic pelvic pain *Nig J Surg Sci* 2017;27:30-2.
- Eke AC, Denny M, Roth S. Intrauterine cleaning after placental delivery at cesarean section: A randomized controlled trial ACOG 2016; Abstract 270P.
- Elford K, Claman P. Novel treatment of a patient with secondary infertility due to retained fetal bone. *Fertil Steril* 2003;79:1028-30.
- Bakshi PS, Allahbadia GN, Kaur K, Virk SPS. Hysteroscopic removal of intrauterine retained fetal bones. *Gynecol Surg* 2004;1:159-66.