

# Retention clitoral cyst following female genital cutting; clitoral cyst excision: A case report

**RABIU A, ABUBAKAR IS**

Department of Obstetrics and Gynecology, Bayero University Kano/Aminu Kano Teaching Hospital, Kano, Nigeria

### ABSTRACT

Female genital cutting involves partial or total removal of the female external genitalia for cultural or other nontherapeutic reasons. It is found to interfere with natural functioning of the body and can result in several complications with associated lasting health consequences. One of the complications of this practice is clitoral inclusion cyst. This occurs due to the invagination of squamous epithelium and sebaceous glands in the line of the scar following female genital cutting which desquamates and produces secretions to form a cystic mass. It is usually following type 1 female genital cutting. We presented a 15-year-old sickle cell anemia patient who had female genital cutting during childhood and presented with clitoral cyst. She was the second of a set of twins. She had normal female external genitalia with a solitary, firm, well-circumscribed mass on the clitoris which was centrally located. The prepuce covering the clitoris and part of the clitoris were amputated. The labia minora, majora, the urethral orifice, the vaginal orifice, and the hymen were all normal. The problems were explained to the parent and the child. She was counseled on her condition and the possible cause. Assent was sought and obtained for surgical removal, and the cyst was removed under spinal anesthesia with light sedation.


**Key words:** Clitoral inclusion cyst; female genital cutting; Nigeria.

### Introduction

Female genital mutilation is defined as “all procedures involving partial or total removal of the female external genitalia or other injuries to the female genital organs whether for cultural or other nontherapeutic reasons.”<sup>[1]</sup> It is believed to have no known health benefits; in addition, the removal of the female external genitalia or damage to the healthy genital tissue is found to have interference with the natural functioning of the body which can result in several immediate and long-term lasting health consequences.<sup>[2]</sup> Female genital cutting (mutilation) is classified into four major types. These include type 1 which is commonly referred to as clitoridectomy and it involves partial or total removal of the clitoris and in rare occasion only the removal of the prepuce. In type 2 which is referred to as excision, there is

partial or total removal of the clitoris and the labia minora with or without excision of the labia majora. Type 3 is also referred to as infibulations and it involves narrowing of the vaginal opening through the creation of a covering seal. This seal is formed by cutting and repositioning the labia minora or majora through stitching, with or without clitoridectomy. All other harmful procedures for nonmedical purposes to the female genitalia that do not fall within the types 1–3 such as piercing, incision, pricking, cauterization, and scraping the genital area are classified as type 4 female genital cutting.<sup>[3]</sup> In 2007, WHO revised the classification of female genital mutilation into subdivision based on the experience with

**Address for correspondence:** Dr. Rabiu A, Department of Obstetrics and Gynecology, Bayero University Kano/Aminu Kano Teaching Hospital, P.M.B. 3011, Kano, Nigeria. E-mail: ayyubarabiu@yahoo.com

Access this article online	
<b>Website:</b> www.tjogonline.com	<b>Quick Response Code</b> 
<b>DOI:</b> 10.4103/TJOG.TJOG_28_18	

This is an open access journal, and articles are distributed under the terms of the Creative Commons Attribution-NonCommercial-ShareAlike 4.0 License, which allows others to remix, tweak, and build upon the work non-commercially, as long as appropriate credit is given and the new creations are licensed under the identical terms.

**For reprints contact:** reprints@medknow.com

**How to cite this article:** Rabiu A, Abubakar IS. Retention clitoral cyst following female genital cutting; clitoral cyst excision: A case report. Trop J Obstet Gynaecol 2019;36:136-39.

the usage of the old classification over the past decade and the need for the inclusion of various procedures that are more closely related. Type 1 is subdivided into type 1a, which involves removal of the clitoral hood or prepuce only and type 1b which involves removal of the clitoris with the prepuce.<sup>[2]</sup> Female genital cutting is rarely performed without complications which could be of short- or long-term effects. Excessive bleeding, dysuria, urinary incontinence, genital swelling, and acute infections are some of the short-term complications.<sup>[2]</sup> Long-term complications include synechia of the labia, keloids formation, fibrosis, tissue rotation, and organic dyspareunia.<sup>[4]</sup> Genital swellings, such as clitoral inclusion cyst, are commonly seen among those that had type 1a or 1b female genital cutting.

### Case Report

The patient was a 15-year-old female adolescent, who presented with 4-year history of progressive swelling in the perineum. The informant was her mother. She was in her usual state of health until 4 years before presentation before she noticed a swelling on the clitoris. The swelling was initially small but had progressively enlarged in size. It was painless but about 3 weeks before presentation, it became painful. There was no associated itching discharge or ulceration. She had female genital cutting at the age of 5 years.

She was a known sickle cell disease patient diagnosed at 3 years of age when she presented with painful hands and feet swelling in this hospital. Her hemoglobin genotype was SS. She was since commenced on folic acid and proguanil. No history of swellings in other parts of the body. No history of abnormal hair distribution, deepening of voice, or acne. She was yet to attain menarche but had other secondary sexual characteristics such as early breast development and axillary hair. She was the second of a set of twins. No similar complaints from the other twin who had attained menarche.

Clinical examination revealed an adolescent girl who was moderately pale (hemoglobin of 9.2 g/dl) with tinge of jaundice. She was a febrile (temp. 36.2°C), and her pulse rate and blood pressure were 96 beat/min and 100/60 mmHg, respectively. There were no masses palpable per abdomen.

She had normal female external genitalia with a solitary, firm, well-circumscribed mass on the clitoris [Figure 1]. It was mildly tender and measured 5 cm × 3 cm in its largest diameter. The mass was centrally located. The prepuce covering the clitoris and part of the clitoris were amputated. The labia minora, majora, the urethral orifice, the vaginal orifice, and the hymen were all normal. There was no discharge or bleeding. She

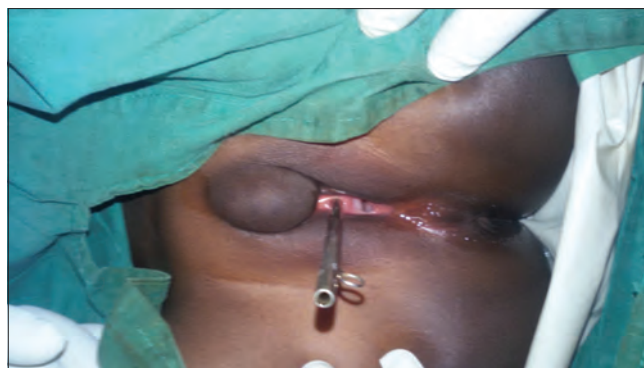


Figure 1: Inclusion clitoral cyst with metal catheter inside the urethra

had a pelvic ultrasound scan, which revealed a normal-sized uterus measuring about 20 mm in its antero-posterior diameter. It depicted uniform parenchymal echo texture. Both adnexae were free. The pouch of Douglas was empty. Using high-resolution techniques, perineal examination showed an enlarged clitoris with a thickened wall and a cystic space within it. Mobile echoes were seen within the cystic space raising suspicion for an abscess collection. It measured 18 mm × 30 mm × 11 mm. The subcutaneous muscle and other tissue planes of the perineum were within the normal limits. The problems were explained to the parent and the child.

She was counseled on her condition and the possible cause. Assent was sought and obtained for surgical removal under spinal anesthesia with light sedation.

The vulva and perineum were cleaned with antiseptic and draped. Following insertion of size 12 Foley catheter, the surrounding skin of the clitoral cyst was infiltrated underneath with adrenaline. An inverted U-shaped incision was made on the skin covering the cyst. The skin was held with Allis tissue forceps and gently dissected off the cyst. The cyst was gently enucleated intact with the aid of a blunt dissection [Figure 2]. The redundant skin was trimmed and the remains of the clitoral tissues were reconstructed using vicryl 2/0 [Figure 3]. There was a minimal blood loss and hemostasis was well secured. The cyst was submitted for histological diagnosis.

She was commenced on prophylactic antibiotics. Immediate postoperative condition was satisfactory. Catheter was removed after 24 h. She was continent of urine and had no dysuria. She was discharged home after 5 days. Histology results revealed macroscopy: "a partly skin covered cyst measuring 5 cm × 4 cm × 3 cm. The lumen revealed thick sebaceous materials." Microscopy "shows a cyst wall, lined by keratinizing stratified squamous epithelium. The lumen is filled with keratinous debris."

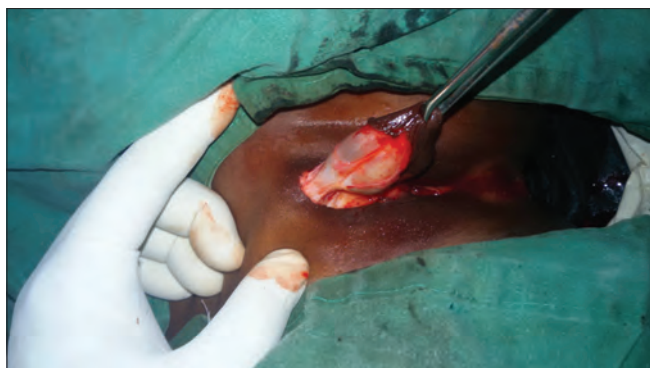

Figure 2: Enucleation of the inclusion clitoral cyst

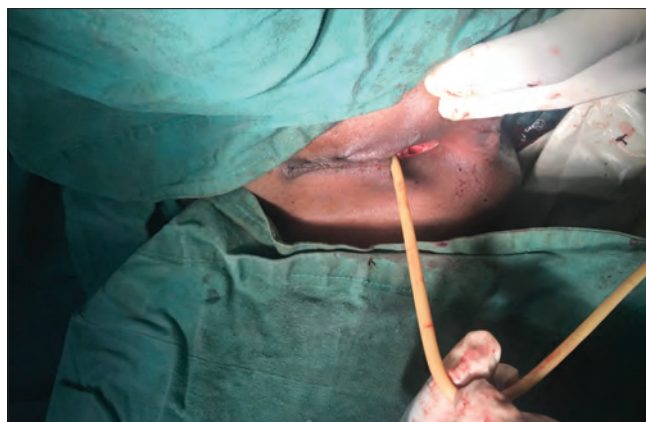

Figure 3: Reconstructed perineum after removal of clitoral cyst with Foley catheter *in situ*

## Discussion

Clitoral inclusion cyst results from the invagination of squamous epithelium and sebaceous glands in the line of the scar following female genital cutting; it desquamates and produces secretions to form a cystic mass.<sup>[5]</sup> It arises as a complication of type I female genital cutting.<sup>[5,6,7]</sup> Following the aforementioned harmful practice, patients present with various complications of mainly labial adhesions and clitoral retention cyst.<sup>[6]</sup> The clitoral retention cyst occurs in about 48.72% of the cases of female genital cutting.<sup>[6]</sup> The age at presentation is usually within the range of 1–5 years,<sup>[5,8]</sup> although a number of cases presented within the age range of 30–50 years.<sup>[8]</sup> This patient presented at the age of 15 years.

At presentation, their complaints depend on the age of the patient, the degree of the procedure and associated complication, and the size of the clitoral retention cyst.<sup>[5]</sup> These could be a slowly growing painless swelling in the pubic region that interferes with daily activities; difficulty in having sexual intercourse; difficulty in wearing underwear.<sup>[5,7]</sup> Some are discovered incidentally by the parents.<sup>[8]</sup> Here, the swelling was discovered by the patient probably because of her age and level of maturity.

The harmful practice of female genital cutting, which gives rise to long-term complications such as clitoral retention cyst, originated since antiquity. Although most communities of the world had practiced it at one time or another, in modern times, however, it has become virtually limited to the developing world where it is performed for such reasons as chastity, reduction of vaginal discharge, and as a symbol of femininity.<sup>[9]</sup> Hence, to be a female child and brought-up in developing world is a risk factor for clitoral retention cyst.

In this index case, the presumptive diagnosis was clitoral retention cyst that was related to female genital cutting and as such it was decided to be removed under anaesthesia. The

cyst was easily dissected from the surrounding structures and completely excised intact. The redundant labial skin is usually trimmed and the wound closed with absorbable sutures.<sup>[7]</sup> These were what this patient had. The operative findings included the presence of subcutaneous encapsulated cystic swelling with a well-demarcated plane of cleavage between the cyst and the overlying skin. There was no residual clitoral tissue in the histology. There was no complication usually after excision of clitoral cyst and most patients are discharged the second postoperative day.<sup>[5]</sup> This patient was, however, kept on admission until after 5 days due to her sickle cell anemia.

The harmful practice of female genital cutting is deeply ingrained in the mind of our people, as such emphasizing the reproductive health implication of the practice may serve as an effective strategy for eliminating it.

## Declaration of patient consent

The authors certify that they have obtained all appropriate patient consent forms. In the form the patient(s) has/have given his/her/their consent for his/her/their images and other clinical information to be reported in the journal. The patients understand that their names and initials will not be published and due efforts will be made to conceal their identity, but anonymity cannot be guaranteed.

## Financial support and sponsorship

Nil.

## Conflicts of interest

There are no conflicts of interest.

## References

1. Eliminating female genital mutilation: an interagency statement World Health Organization - Geneva, Switzerland: WHO, 2008.

2. WHO. Sexual and reproductive health; Classification of female genital mutilation. 2019. Available from: <https://www.who.int/reproductivehealth/topics/fgm/overview/en/>. [Last accessed on 2019 Apr 03].
3. WHO. Female genital mutilation. Key facts. 2018. Available from: <https://www.who.int/en/news-room/fact-sheets/detail/female-genital-mutilation>. [Last accessed on 2019 Apr 03].
4. Kaplan A, Hechavarría S, Martín M, Bonhoure I. Health consequences of female genital mutilation/cutting in the Gambia, evidence into action. *Reprod Health* 2011;8:1-6.
5. Young W, Shakya R, Sanders B, Lind J. Delayed vaginal erosion of the tape: A rare complication with TVT. *J Obstet Gynaecol* 2004;24:96-8.
6. Adekunle A, Fakokunde F, Odukogbe A, Fawole A. Female genital mutilation: Post-circumcision vulval complications in Nigeria. *J Obstet Gynaecol* 1999;19:632-5.
7. Rizk D, Mohammad K, Joshi S, Al-Shabani A, Bosmarr T. A large clitoral epidermoid inclusion cyst: First presenting in adulthood following circumcision. *J Obstet Gynaecol* 2007;27:446-8.
8. Ekenze S, Ezegwui H, Adiri C. Genital lesions complicating female genital cutting in infancy: A hospital-based study in south-east Nigeria. *Ann Trop Paediatr* [Internet] 2007;27:285-90.
9. Egwuatu V, Agugua N. Complications of female circumcision in Nigerian Igbo. *Br J Obstet Gynaecol* 1981;88:1090-3.