

# Caesarean section in a primigravida with spina bifida occulta and a spinal cord stimulator: Preconception counselling, antenatal care and anesthetic considerations

HADIJAT O RAJI, ZAKARI A SULEIMAN<sup>1</sup>, ZAINAB A ABDULKADIR<sup>2</sup>, AMINUDEEN ABDULRAHMAN<sup>3</sup>

Departments of Obstetrics and Gynecology, <sup>1</sup>Anaesthesia, University of Ilorin, Departments of <sup>2</sup>Obstetrics and Gynaecology, <sup>3</sup>Anaesthesia, University of Ilorin Teaching Hospital, Kwara State, Nigeria

## ABSTRACT

Recent developments in medical and surgical subspecialties have contributed to improved quality of life in patients with spina bifida (SB). Despite the challenges of chronic pain, spinal abnormality, gait abnormalities, loss of urinary, and fecal continence, female patients can become pregnant. Provision of obstetrics and/or surgical care to patients with SB may become more common as more patients survive to adulthood. Preconception counseling, antenatal care, obstetrics, and other specialized care are essential components of optimal management of these patients. We report the obstetric and anesthetic challenges encountered in a primigravida with SB occulta and a spinal cord stimulator who had caesarean delivery. Effective communication between the patient, obstetricians, and anesthesiologists, as well as planned and coordinated care, ensured a successful fetomaternal outcome.

**Key words:** Antenatal management; caesarean delivery; preconception care; spina bifida; spinal cord stimulator.

## Introduction

Spina bifida (SB) is a neural tube defect (NTD) caused by failure of closure of the neural arch during embryogenesis. It may be associated with neural, sensory, and motor losses, orthopedic impairments, bladder and bowel dysfunction, and occasional cognitive impairments.<sup>[1]</sup> By estimate, NTDs affect 300,000 newborn babies globally, with SB accounting for about 50% of cases.<sup>[2]</sup>

Although mortality rate of up to 60% was previously reported in patients with SB by adulthood,<sup>[3]</sup> advances in medical and surgical managements have raised survival to adulthood to the current level of 80%.<sup>[4]</sup>

Pregnancy in a patient with SB is fraught with many problems including 4% higher risk of delivering a baby with NTD compared with 0.1%–0.3% in the general population,<sup>[5]</sup>

worsening of bowel and bladder dysfunction, and movement disorders among others. Literature on the obstetric and anesthetic management of parturients with SB is virtually nonexistent in our environment. We present our experience on preconception counseling, antenatal care, and successful Caesarean delivery in a primigravida with SB who had multiple corrective spine surgeries and a spinal cord stimulator (SCS).

## Case Report

The patient was a 33-year-old married nulliparous woman with SB occulta who visited our hospital to enquire about

**Address for correspondence:** Dr. Hadijat O Raji, Department of Obstetrics and Gynaecology, College of Health Sciences, University of Ilorin, PMB 1515, Ilorin, Kwara State, Nigeria.  
E-mail: laideraji1@yahoo.com

This is an open access journal, and articles are distributed under the terms of the Creative Commons Attribution-NonCommercial-ShareAlike 4.0 License, which allows others to remix, tweak, and build upon the work non-commercially, as long as appropriate credit is given and the new creations are licensed under the identical terms.

**For reprints contact:** reprints@medknow.com

**How to cite this article:** Raji HO, Suleiman ZA, Abdulkadir ZA, Abdulrahman A. Caesarean section in a primigravida with spina bifida occulta and a spinal cord stimulator: Preconception counselling, antenatal care and anesthetic considerations. Trop J Obstet Gynaecol 2018;35:192-5.

Access this article online	
<b>Website:</b> www.tjogonline.com	<b>Quick Response Code</b> 
<b>DOI:</b> 10.4103/TJOG.TJOG_7_18	

preconception care and obstetrics care services for patients with NTDs. Diagnosis of SB occulta was made in her teenage years and she had history of urinary and fecal incontinences, chronic constipation, chronic pain, and progressive loss of sensory and motor functions involving both lower limbs resulting in lower limbs' weakness and gait abnormalities.

She had multiple corrective spinal surgeries, the most recent one being 3 years previously and involved spinal re-exploration and de-tethering, L2–L5 laminectomy, lipoma excision, filum sectioning, duraplasty, and insertion of spinal cord stimulation electrodes [Figures 1-3]. The inserted electrodes over the thoracic and sacral epidural space were for control of chronic lower limb pain and neurogenic bladder, respectively. She learnt how to perform essential skills such as self-catheterization, manual rectal evacuation, and soap and water enema to relieve constipation. She was also on intermittent prophylactic laxatives to relieve constipation. Despite gait abnormality, she was ambulating with the aid of either crutches or a walking frame.

Clinical examination revealed a healthy young woman with intact cranial nerves, normal power, tone and reflexes in the upper limbs but mild hypo-tonia and hypo-reflexia, muscle atrophy, and patchy loss of touch sensations in both lower limbs up to the upper thirds of her thighs. Power in the right and left lower limbs were 3 and 4, respectively. There was a longitudinal surgical scar over the lower back and an oblique scar along the superior edge of the glutei muscles bilaterally, with the implantable pulse generator on the right side.

That pregnancy, when achieved, might be associated with high risk of delivering a baby with the same congenital abnormality, recurrent urinary tract infections (UTIs), increasing bowel and bladder dysfunction, and worsening of back and lower limb pain was part of the preconception counseling offered to the patient. She was immediately commenced on high-dose folic acid and advised to re-present when she conceives.

Six months after counseling and commencement of high-dose folic acid, she presented with an ultrasound confirmation of an 8-week intrauterine gestation. Laboratory investigations were within normal limits at antenatal booking. She was encouraged to continue high-dose folic acid and hematinics. Anomaly scan performed at 22 weeks was normal. The SCS was deactivated and remained so throughout the remaining period of pregnancy. The patient had prophylactic nitrofurantoin from the second trimester up to 34 weeks to reduce the incidence of recurrent UTIs. Delivery options were discussed and an elective Caesarean section at term

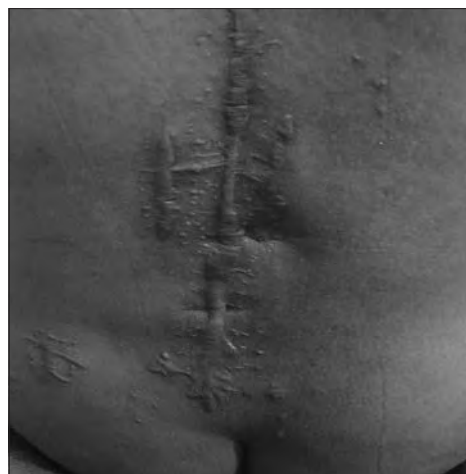

Figure 1: Back view of patient showing surgical scars

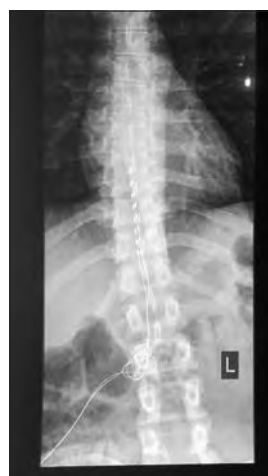

Figure 2: X-ray of thoracolumbar region showing the Spinal Cord Stimulator leads at T9-T11

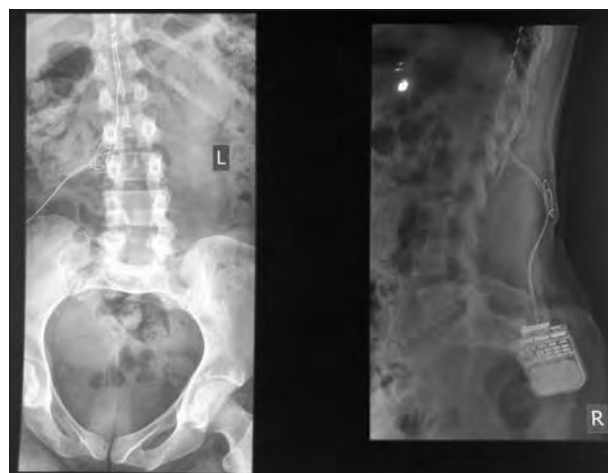


Figure 3: Lateral view of the thoracolumbar region showing the implantable pulse generator in the gluteal region

was decided upon in view of her neuromuscular problems. Options of anesthesia were also discussed. An episode of UTI occurred during the antenatal period, and sensitivity result

guided the treatment. Her renal function remained normal throughout pregnancy.

At 38 weeks' gestation, she was delivered of a live male infant through an elective Caesarean section under opioid-free general anesthesia with ketamine used as an induction agent and pancuronium bromide to intubate the trachea and maintain muscle relaxation. Effective communication during the antenatal and perioperative periods ensued between the patient, obstetrics, and the anesthesiology teams in taking this decision.

Postoperative analgesia was achieved by continuous ketamine infusion at 12 mg/h through an infusion pump and continuous wound infusion with plain bupivacaine (0.125%) 2 mL/h delivered with Beeline postop pain control pump (LOT CP15669, REF BL 1D002SK2-CP, USA) and acetaminophen infusion 600 mg 8 hourly for 3 days, with good pain control achieved throughout. Postoperative compression stockings, anticoagulant, combined with early ambulation in the post-operative period, were instituted to prevent development of deep vein thrombosis, a common complication in patients with SB due to restricted mobility. Disturbing spastic contraction of the lower limbs was prominent on the third postoperative day but it responded to baclofen tablets.

The newborn underwent a thorough physical examination with no abnormalities detected. She was discharged home on the sixth postoperative day. She attended postnatal visits at the second and sixth week postpartum and had no complaints.

## Discussion

Worldwide, pregnancy in SB patients is a relatively uncommon occurrence, and to the best of our knowledge, this is the first report of successful obstetric care of a parturient with SB occulta and SCS in this environment.

This case highlighted the importance of immediate and thorough physical examination of all newborn for early detection of congenital abnormalities, the necessity of preconception care provision, including preconception folic acid, the challenges that could occur during pregnancy and delivery, as well as the need for multidisciplinary management of parturients with SB to achieve good outcome.

In view of the increased risk of giving birth to a child with similar abnormality, this patient was commenced on preconception high-dose folic acid which has been found to lower this risk, as dietary folic acid deficiency has been implicated in the development of NTDs.

This patient had a neurogenic bladder, which is common in patients with SB and the antenatal period was complicated by UTI. Prophylactic nitrofurantoin and intermittent catheterization may have helped to limit the occurrence of UTI to just one episode. Use of prophylactic nitrofurantoin is encouraged in patients with increased risk of UTI during pregnancy.<sup>[6]</sup>

She also had an SCS implanted for neurogenic bladder and chronic lower limb pain. This device is helpful in the management of various disorders including urinary tract and bowel dysfunction, spinal injury, and chronic pain syndromes, and there have been reports of pregnancies in patients with the device. The risks posed to the fetus by the SCS remain unknown, and there is no consensus regarding its safety during pregnancy. While some clinicians have postulated that SCS, through electromagnetic field force, could potentially compromise the placenta and developing fetus,<sup>[7]</sup> others have reported on its safe use without any untoward effect on the pregnant woman or her baby.<sup>[8,9]</sup> It has thus been advised that activation or deactivation during pregnancy should be individualized.<sup>[10]</sup>

Patients with SB have an increased predisposition to preterm labor<sup>[11]</sup> possibly due to UTIs or undetected coexisting abnormalities of the genital tract such as bicornuate uterus.<sup>[4]</sup> This complication, however, did not occur in this patient.

Although there are reports of safety of vaginal deliveries among women with SB,<sup>[11]</sup> our patient was counseled for, and had, an elective Caesarean section at term because she was a primigravida with an untried pelvis, wasted muscles of the lower limbs, gait abnormalities, and previous multiple spinal surgeries. This helped to avoid potential prolongation of labor and difficult delivery that could result from suspected compromised pelvis. Our chosen mode of delivery agrees with preferences of some authors for Caesarean section in patients with SB<sup>[12]</sup> although other authors recommend Caesarean section only for obstetric indications.<sup>[5]</sup>

Generally speaking, establishing regional anesthesia in patients with SB is challenging due to the abnormality of the spine and possibility of tethered cord which may result in iatrogenic cord injury.<sup>[13,14]</sup> Regional anesthesia was not favored in this patient due to the high likelihood of fibrosis within the peri-spinal spaces from her multiple spine surgeries. Moreover, she had SCS leads in the epidural space overlying T9–11 with the generator in the gluteal region. This lead can migrate if, during neuroaxial block, the advancing tip of the needle impinges on the connecting wire.

Preconception care and multidisciplinary care involving obstetrician, neurosurgeon, physiotherapist, neonatologist, and anesthetist contributed to the good outcome observed in this patient.

## Conclusion

As more patients with SB are surviving to adulthood, maternity care providers will increasingly encounter pregnant parturients with this congenital abnormality. There is a need for healthcare practitioners to be familiar with obstetric, urologic, surgical, and anesthetic challenges involved in the care of these patients and their preconception care needs to improve outcomes and reduce the risk of recurrence in their offspring.

## Declaration of patient consent

The authors certify that they have obtained all appropriate patient consent forms. In the form the patient(s) has/have given his/her/their consent for his/her/their images and other clinical information to be reported in the journal. The patients understand that their names and initials will not be published and due efforts will be made to conceal their identity, but anonymity cannot be guaranteed.

## Financial support and sponsorship

Nil.

## Conflicts of interest

There are no conflicts of interest.

## References

1. Flores AL, Vellozzi C, Valencia D, Sniezek J. Global burden of neural

tube defects, risk factors, and prevention. *Indian. J Community Health* 2014;26:3-5.

2. Christianson AL, Howson CP, Modell B. *Global Report on Birth Defects: The Hidden Toll of Dying and Disabled Children*. White Plains, NY, March of Dimes Birth Defects Foundation; 2006.
3. Oakeshott, P, Hunt GM, Poulton A, Reid F. Expectation of life and unexpected death in open spina bifida: A 40-year complete, non-selective, longitudinal cohort study. *Dev Med Child Neurol* 2010;52:749e53.
4. Drakes O. Spina bifida and motherhood. *Spec Educ Forward Trends* 1984;11:16-8.
5. Rietberg CCT, Lindhout D. Adult patients with spina bifida cystica: Genetic counselling, pregnancy and delivery. *Eur J Obstet Gynecol Reprod Biol* 1993;52:63-70.
6. ACOG. Sulfonamides, nitrofurantoin, and risk of birth defects. Committee Opinion No. 717. *American College of Obstetricians and Gynecologists. Obstet Gynecol* 2017;130:e150-2. Available from: <https://www.acog.org/Clinical-Guidance-and-Publications/Committee-Opinions/Committee-on-Obstetric-Practice/Sulfonamides-Nitrofurantoin-and-Risk-of-Birth-Defects>. [Last assessed on 2018 Jan 2].
7. Ito S, Sugiura T, Azami T, Sasano H, Sobue K. Spinal cord stimulation for a woman with complex regional pain syndrome who wished to get pregnant. *J Anesth* 2013;27:124-7.
8. Bernardini DJ, Pratt SD, Takoudes TC, Simopoulos TT. Spinal cord stimulation and the pregnant patient-specific considerations for management: A case series and review of the literature. *Neuromodulation* 2010;13:270-4.
9. Yaiesh SM, Al-Terki AE, Al-Shaiji TF. Safety of sacral nerve stimulation in pregnancy: A literature review. *Genitourin Disord* 2016;19:770-9.
10. Mahran A, Soriano A, Safwat AS, Hijaz A, Mahajan ST, Trabuco EC, *et al.* The effect of sacral neuromodulation on pregnancy: A systematic review. *Int Urogynecol J* 2017;28:1357-65. Available from: <https://www.ncbi.nlm.nih.gov/pubmed/28160010>. [Last assessed on 2017 Dec 28].
11. Arata M, Grover S, Dunne K, Bryan D. Pregnancy outcome and complications in women with spina bifida. *J Reprod Med* 2000;45:743e8.
12. Wynn JS, Mellor S, Morewood GA. Pregnancy in patients with spina bifida cystica. *Practitioner* 1979;222:543-6.
13. Crosby ET, Halpern SH. Obstetric epidural anaesthesia in patients with Harrington instrumentation. *Can J Anaesth* 1989;36:693-6.
14. Vaagenes P, Fjaerestad I. Epidural block during labour in a patient with spina bifida cystica. *Anaesthesia* 1981;36:299-301.