

Intramyometrial gestation: A rare localization of ectopic pregnancy

RAVIKANTH REDDY

Department of Radiology, St. John's Medical College, Bengaluru, Karnataka, India

ABSTRACT

Intramyometrial pregnancy is the rarest subtype of ectopic pregnancy. It poses a diagnostic and therapeutic challenge. Preoperative diagnosis is difficult, and hysterectomy is always required due to the delay in diagnosis. Misdiagnosis can lead to uterine rupture with life threatening hemorrhage. We report a rare case of intramyometrial ectopic pregnancy in a 27-year-old lady, P3L3, with no history of previous abortions. The patient was admitted at 8 weeks of gestation with pelvic pain and hemorrhage. She underwent ultrasound and magnetic resonance imaging scans of the pelvis which revealed an intramyometrial ectopic. Findings on diagnostic laparoscopy revealed an asymmetrically enlarged anterior wall of the uterus. Hysteroscopy was performed concurrently demonstrating an empty uterine cavity. Medical management was adopted with methotrexate. She was followed up until the beta-HCG levels returned to the baseline. This case report illustrates the imaging findings of an exceptional case of intramyometrial ectopic pregnancy.

Key words: Intramyometrial ectopic; magnetic resonance imaging; methotrexate; ultrasound.

Introduction

Following fertilization and fallopian tube transit, the blastocyst normally implants within the uterine cavity. Implantation at a site other than the uterine cavity is considered ectopic and comprises 1–2% of all first trimester pregnancies.^[1] Nearly 95% of ectopic pregnancies are implanted in various segments of the fallopian tube, with the remaining 5% of nontubal pregnancies implanting in the ovary, peritoneal cavity, cervix, or prior cesarean scar. Intramural pregnancy refers to a gestation completely implanted within the myometrium of the uterus separate from the uterine cavity, fallopian tube, or round ligament. This is a very rare location for an ectopic, and less than 50 cases have been reported in the literature (less than 1% of all ectopic pregnancies).^[2] These cases are usually complicated by hemorrhage and uterine rupture. Diagnosis is often difficult with the closest differential being hydatiform mole. Diagnostic modalities include ultrasound scan and magnetic resonance imaging (MRI) demonstrating

myometrium completely surrounding the gestational sac with no communication with the endometrial cavity. No documented case of term pregnancy exists. However, if the diagnosis is made earlier, treatment may be conservative, resulting in the preservation of reproductive potential. Treatment modalities documented in the literature for intramural pregnancy include expectant management, surgical enucleation, uterine artery embolization, systemic or local methotrexate administration, hysterectomy, and intrafetal injection of potassium chloride.^[3]

Case History


We report a rare case of intramyometrial ectopic pregnancy in a 27-year-old lady, P3L3, who presented to the emergency department at 8 weeks of gestation with complaints of

Address for correspondence: Dr. Ravikanth Reddy, Department of Radiology, St. John's Medical College, Bengaluru - 560 034, Karnataka, India.
E-mail: ravikanthreddy06@gmail.com

This is an open access article distributed under the terms of the Creative Commons Attribution-NonCommercial-ShareAlike 3.0 License, which allows others to remix, tweak, and build upon the work non-commercially, as long as the author is credited and the new creations are licensed under the identical terms.

For reprints contact: reprints@medknow.com

How to cite this article: Reddy R. Intramyometrial gestation: A rare localization of ectopic pregnancy. Trop J Obstet Gynaecol 2017;34:73-5.

Access this article online	
Website: www.tjogonline.com	Quick Response Code 
DOI: 10.4103/TJOG.TJOG_2_17	

pelvic pain and hemorrhage not subsiding with medical management. Transvaginal ultrasound revealed an exocentric gestational sac with thick decidual reaction and a “ring of fire” appearance on color Doppler [Figure 1]. Uterine cavity was empty and no adnexal masses were visualized. Furthermore, MRI of the pelvis with contrast was done to confirm the location of the ectopic gestation which revealed a well-defined T1 isointense, T2 hyperintense lesion in the anterior myometrium abutting the junctional zone and showing contrast enhancement [Figure 2]. Endometrial stripe was seen separately with an empty uterine cavity [Figure 3]. Pouch of Douglas had no free fluid. On diagnostic laparoscopy, an asymmetrically enlarged swollen anterior wall of the uterus was seen. Hysteroscopy was performed concurrently demonstrating an empty uterine cavity. Medical management with methotrexate was initiated following confirmation of the diagnosis. Beta-HCG at the time of diagnosis was 9949 mIU/ml. She was followed up until the hormone levels returned to the baseline value of 5 mIU/ml and serial scans showed a healed solid collection.

Discussion

Ectopic pregnancy is the most common gynecologic abnormality and emergency that afflicts a potential mother and remains a major cause of mortality worldwide. It comprises 1–2% of all pregnancies with a myriad of locations having a hierarchy of prevalence as well as associated morbidity and mortality.^[4] The most common location for ectopic pregnancy continues to be the fallopian tube. Intramyometrial ectopic pregnancy constitutes less than 1% of the total number and is the rarest type. Pathological definition of an intramyometrial pregnancy refers to a conceptus implanting within a myometrium and separated from both the uterine cavity and tubes as well as surrounded by myometrium. Intramyometrial gestation rarely exceeds 12 weeks of gestation with risk of uterine rupture and 2.5% of maternal mortality.^[5]

Most common etiological factor is uterine trauma resulting in a sinus tract within the endometrium. Other factors include increased trophoblastic activity and defective decidualization, which allows the conceptus to penetrate the myometrium. Implantation on the focus of adenomyosis may also account for this phenomenon as may serosal implantation of the conceptus following external migration. Other factors such as *in-vitro* fertilization, embryo transfer, and traumatic factors such as dilatation and curettage (D and C), caesarean section, myomectomy, and manual removal of placenta have also been implicated in the etiology of intramyometrial gestation.^[6]

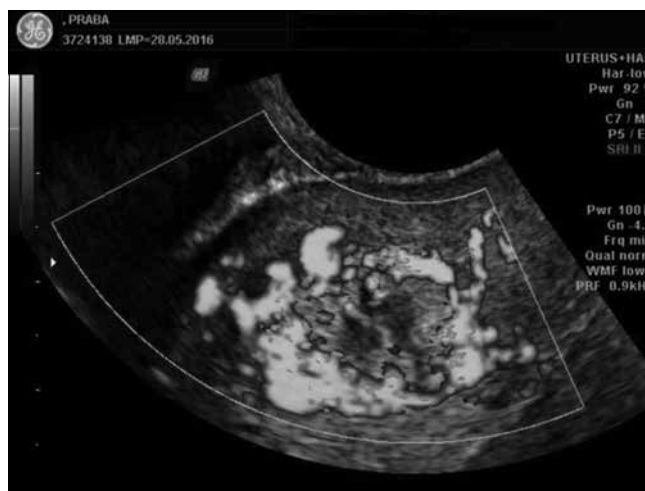

Figure 1: Transvaginal ultrasound images showing showing “Ring of fire” appearance suggesting hypervascularity of the intramyometrial ectopic

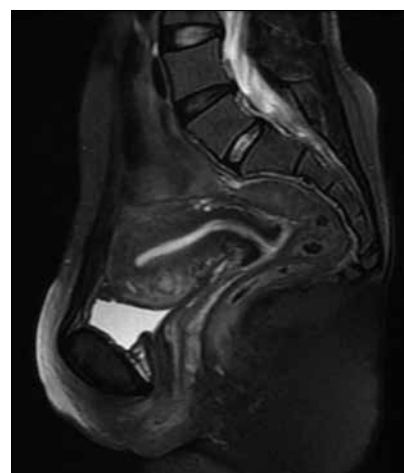


Figure 2: Sagittal T2W spin-echo image image showing well defined hyperintense lesion involving the anterior myometrium

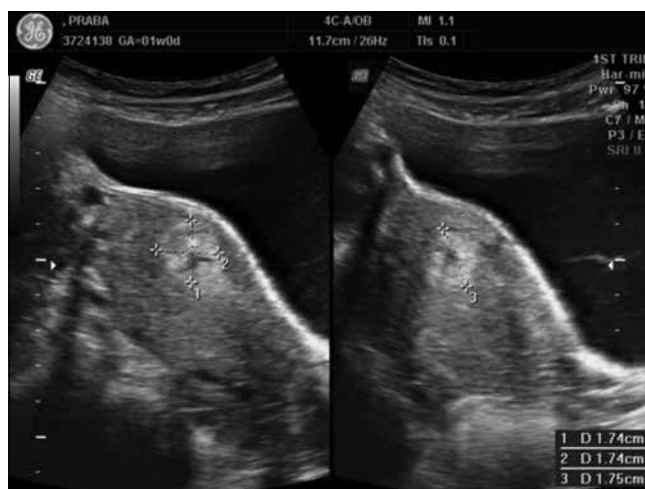


Figure 3: Transabdominal ultrasound images showing well defined lesion in the anterior myometrium with thick decidual reaction. Endometrial stripe is separately visualized with empty uterine cavity

Pelvic pain and uterine bleeding in the presence of a positive pregnancy test are the hallmarks of an ectopic pregnancy. Early diagnosis of intramyometrial gestation is very difficult and is mostly made intraoperatively. Only three cases of intramural pregnancy have been correctly diagnosed preoperatively by ultrasound and one by MRI.^[7] A gestational sac completely surrounded by myometrium is the typical ultrasound appearance of an intramural pregnancy. Ultrasound typically shows a gestational sac with thick decidual reaction with a “ring of fire” appearance suggesting hypervascularity, empty uterine cavity, and no adnexal lesions. MRI confirms the location of the gestational sac and demonstrates no communication with the endometrial cavity and provides better visualization of the myometrium and endometrium separately. Some authors have reported the use of hysteroscopy, which allows direct visualization of the uterine cavity and tubal ostium and confirms the absence of the conceptus in the uterine cavity. Serial beta-HCG assay has been reported to be useful for the diagnosis.^[8]

Prognosis is very poor for fetuses in intramyometrial pregnancies. Treatment options depend on the time of diagnosis. In a hemodynamically stable patient who wants a future pregnancy, this condition can be managed conservatively by local administration of KCL or methotrexate or by systemic methotrexate either in single dose or as multiple dose regimen. Nonradical surgical management by enucleation or wedge resection with myometrial reconstruction can be performed. Uterine rupture with hemodynamic instability warrants a hysterectomy.

Conclusion

Intramyometrial gestation is a very rare type of ectopic gestation and is a life-threatening condition. Early detection

of intramyometrial ectopic pregnancy is needed to prevent complications such as uterine rupture and helps preserve fertility. The closest differential diagnosis is hydatiform mole. Transvaginal ultrasound determines the localization of the gestational sac and choice of management.

Financial support and sponsorship

Nil.

Conflicts of interest

There are no conflicts of interest.

References

1. Larrain D, Marengo F, Bourdel N, Jaffeux P, Aublet-Cuvelier B, Pouly JL, *et al.* Proximal ectopic pregnancy: A descriptive general population-based study and results of different management options in 86 cases. *Fertil Steril* 2011;95:867-71.
2. Boukhanni L, Benkaddour YA, Bassir A, Aboufalah A, Asmouki H, Soummami A, *et al.* Case Report A Rare Localization of Ectopic Pregnancy: Intramyometrial Pregnancy in Twin Pregnancy following IVF. *Case Rep Obstet Gynecol* 2014;2014:10-2.
3. Verghese T, Wahba K, Shah A. An interesting case of intramyometrial pregnancy. *BMJ Case Rep* 2016;2012-4.
4. Maria L, Pirolo A, Larciprete G, Valli E, Montagnoli C, Campora G De, *et al.* Unusual ectopic pregnancy: beyond the tubes. *EC Gynaecology* 2016;1.1S1:12-22.
5. Kirk E, Bottomley C, Bourne T. Diagnosing ectopic pregnancy and current concepts in the management of pregnancy of unknown location. *Hum Reprod Update* 2014;20:250-61.
6. Çalifikan E, Lu Ç, Çorakçi A. Expectant Management of an Intramural Ectopic Pregnancy in a Primigravid Woman. *J Turk German Gynecol Assoc* 2008;9:234-6.
7. Leyder M, Vos M De, Dujardin M, Devroey P. Intramyometrial ectopic pregnancy in an ICSI patient following uterine artery embolization. *Reprod Biomed Online* 2010;20:831-5.
8. Marotta M, Donnez J, Michaux N, Dupont M, Delos M, Donnez O, *et al.* Spontaneous intramyometrial pregnancy mimicking an intramural myoma: A diagnostic challenge. *Gynecol Surg* 2016;6-7.