

CONTRACEPTIVE CONVENIENCE WITH A PRICE - A CASE OF MISSING IMPLANTS (IMPLANON) IN A 30 YEAR OLD WOMAN - A CASE REPORT.

¹Bakare Babatola, ²Olasehinde Olalekan, ¹Akinnawonu Opeyemi,

¹*Department of Obstetrics & Gynaecology, State Specialist Hospital Ondo, Ondo State,*

²*Trauma and Surgical Centre, Ondo, Ondo State.*

ABSTRACT

Background: Advances in contraception has resulted in the development of a long acting reversible contraceptive implants which is user friendly, with good contraceptive effectiveness . This contraceptive advantage however has promote the question: has “convenience” come at a price? with the recent findings that it may be lost in the bodies of hundreds of women, raising fears and concern for their future fertility.

Case: A case of non – palpable Implanon 3 -years after insertion with difficulty at removal at the family planning clinic was presented. Ultrasonographic identification and localisation was done with subsequent removal under general anaesthesia.

Conclusion: Despite the fact that Implanon insertion appears to be an easy procedure, but in a small minority of cases difficulties have been encountered with removal if the rod is impalpable. All health professionals inserting and removing contraceptive implants should have been appropriately trained, frequent and regular palpation during follow up of clients after insertion is also advocated.

Keywords: Contraceptives, Missing Implanon.

INTRODUCTION

It has been clearly demonstrated that, for centuries, women and men have been using various methods of contraception, some of which were pernicious to women's overall health, to prevent pregnancy and control their fertility¹. The recent years however have witnessed a rapid development in contraceptive options both in formulations and their methods of use. This has led to greater acceptance of of contraception among couples worldwide.

Many factors influence women's decisions regarding contraceptive methods^{2,3}. It is important to state that contraceptive choices affect the long-term sexual health and fertility of women and men, particularly when contraception is not used correctly or consistently. For many³ women, the ability to control their fertility has enhanced their ability to control their lives; however, with this power has come a

greater responsibility for contraception in a relationship. Given that the majority of contraceptive methods available are made to be used by women and that the consequences of a contraceptive failure can have a greater impact on the life and health of a woman than on her partner, this is a vital issue in women's health.

Knowledge of a contraceptive method's effectiveness and complication can be an important factor in a woman's choice of methods^{2,3}.

Correspondence: Dr Bakare Babatola

*Department of Obstetrics & Gynaecology,
State Specialist Hospital Ondo, Ondo State,
Nigeria. Email: lobak4christ@gmail.com 2*

CASE REPORT

This case concerns a 30 year old primipara, (2A) with previous twin delivery, who was referred from the family planning clinic following difficulty in palpating and removing the contraceptive implant (Implanon). The implanon was inserted three years earlier for contraceptive purpose following delivery of a set of twins. There was no immediate complications following insertion, she however noticed that the Implanon has been impalpable in the last one year before presentation for removal. There was no relevant medical history. On physical examination of her left arm where the implant had been inserted by the attending staff of the family planning clinic, it was noticed that the implanon was not felt under the skin, attempts at removal was made which however proved abortive and was subsequently referred to the gynae clinic. Positive identification and localization of the implanon was achieved with ultrasound of the left arm with the skin/implant depth of about 1.5cm in the substance of brachialis muscle.

She was scheduled for removal under general anaesthesia, the skin/depth parameter, together with the precise position of the implanon (in muscle), facilitate removal. The cavity where the implant was removed was closed and there was no post -operative complications. Supportive therapy was commenced with analgesics and prophylactic antibiotics and she was discharged home second day post –operation.⁴

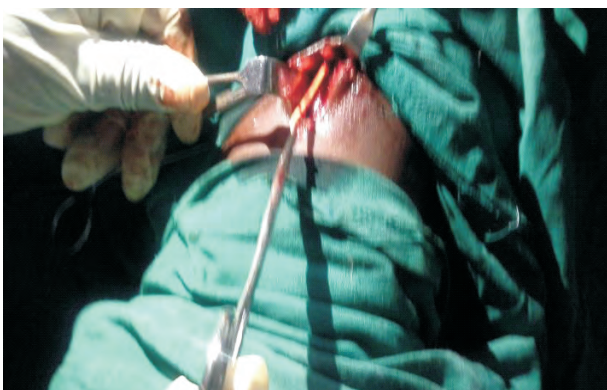

Fig 1: Ultrasound Identification and Location.

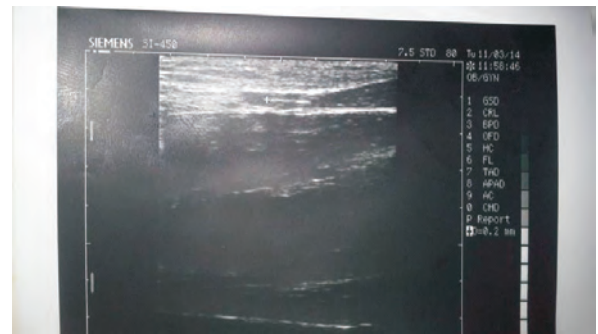

Fig 2: Tissue Dissection and Extraction of Implant. 5

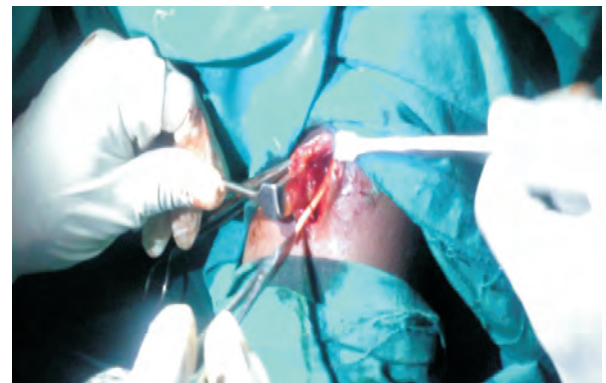


Fig 3: Tissue Dissection and Extra ction of Implant.

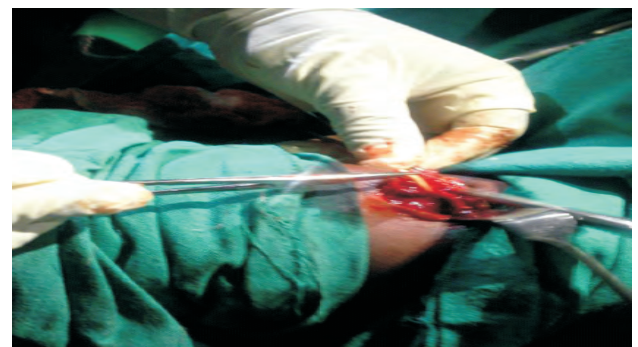

Fig 4: Dissection and Extraction of Implant. 6

DISCUSSION

The past several years have witnessed an expansion in contraception options. Emerging data support the use of long-acting reversible contraception (LARC) such as the intrauterine device and sub- dermal implants as the most effective methods of contraception with the highest continuation rates and very high levels of patient satisfaction.

The World Health Organization characterizes contraceptive methods from the highest efficacy (intrauterine contraceptives, implants, and sterilization) to moderate efficacy (combine

hormonal methods and progesterone-only methods) to least effective such as barrier methods and fertility awareness⁴. Long acting reversible contraceptive methods are highly effective, rivaling sterilization procedures, and last for at least 3 years. The available sub-dermal implant Implanon contain only a single rigid capsule⁵, and are preloaded for ease of insertion⁶, is a single-rod measuring 4cm that releases 68µg of etonogestrel per day. Implanon provides 3 years of contraception with very high efficacy (failure rate <0.1%). The single rod is inserted into the⁷ subcuticular tissue of the inner upper arm under local anesthesia. This method prevent pregnancy primarily by inhibiting ovulation and causing endometrial atrophy. Implanon may also work by inhibiting sperm penetration through the cervix by thickening the cervical mucus. Advantages of the implant include its high effectiveness and ease of use. Contraindications to the implant include pregnancy, undiagnosed abnormal vaginal bleeding, breast cancer, active liver disease, and allergies to any of components of the device.

While there is evidence of the efficacy and safety of implantable contraceptives⁷, both insertion and removal procedure for this implants have been associated with complications. Insertion site complications have been noted in 5.9 % of women within the first year of use⁸. Removal complications were reported in 4.5 % of women, most commonly from implant breakage or embedment in the subdermal plane⁹. Further, 48 % of women experienced significant pain during implant removal¹⁰. Other rare but reported complications include neuropathy which however was not found in this patient on follow up visit. This however is one of the rare complications in which the implant was lost in the substance of the brachialis muscle.

CONCLUSION

Implantable contraceptives are, by and large, safe, well-tolerated, effective, and cost efficient¹¹, but their risks can be significant and should be discussed with the patient prior to insertion and removal. Mandatory training, increasing experience, and the availability of safer products will undoubtedly decrease the risk of insertion- and removal- associated complications.

REFERENCES

1. Walby S. *Theorizing patriarchy*. Cambridge MA: Blackwell publishers; 1990.
2. FORREST JD. U.S . Women perceptions of and attitudes about the IUCD. *Obstet Gynecol. Surv.* 1996; 51: S30-4. [PubMed].
3. STANWOOD NL, BRADLEY KA. Young Pregnant women's knowledge of modern intrauterine devices. *Obstet Gynecol.* 2006;108:1417-22 [PubMed].
4. Family Health International. Comparing effectiveness of family planning methods.[Accessed July 2, 2009]:[http://www.fhi.org/nr/shared/en/FHI/Resources/Effectiveness chart](http://www.fhi.org/nr/shared/en/FHI/Resources/Effectiveness%20chart).
5. Merki-Feld GS, Brekenfeld C, Migge B, et al. Nonpalpable ultrasonographically not detectable Implanon rods can be localized by magnetic resonance imaging. *Contraception.* 2001; 63(6): 325-328. doi:10.1016/s0010-7824(01)00209-8.[PubMed][Cross Ref].
6. Mascarenhas L. Insertion and removal of Implanon. Practical considerations. *Eur J Contracept Reprod Health Care.* 2005;5 (suppl 2): 29-34[PubMed].
7. Coukell AJ, Balfour JA. Levonogestrel subdermal implants. A review of contraceptive efficacy and acceptability. *Drugs.* 1998;55(6):861-887. Doi:10.

- 2165/00003495-199855060-100019.[PubMed][Cross Ref].
8. Klavon SL, Grubb GS. Insertion site complications during the first year of Norplant use. *Contraception*.1990;41(1):27-37.doi:10.1016/0010-7824(90)90124-E.[PubMed][Cross Ref].
9. Dunson TR, Amatya RN, Krueger SL. Complications and risk factors associated with the removal of Norplant implants *Obstet Gynecol*. 1995; 85: 543 - 548.doi:10.1016/0029-7844(94)00458-P.[PubMed][Cross Ref].
10. Frank ML, Ditmore R, Ilegbodu AE, et al. Characteristics and experiences of American Women electing for early removal of contraceptive implants. *Contraception*. 1995; 52: 159 - 165.doi:10.1016/00107824(95)00160C[PubMed][Cross Ref].
11. Wechselberger G, Wolfram D, Pülzl P, et al. Nerve injury caused by removal of an implantable hormonal contraceptive. *Am J Obstet Gynecol*. 2006;195(1):323-326.doi:10.1016/j.ajog.2005.09.016.[PubMed][Cross Ref].