

Efficacy of central-shielding external beam radiotherapy for FIGO stage IB2 carcinoma of the cervix: A case report

Agapiti Chuwa¹

Department of Medical Physiology, Mbeya College of Health and Allied Sciences, University of Dar es Salaam, P. O. Box 608, Mbeya, Tanzania.

Abstract

Introduction: Cervical cancer is now the leading cause of malignancy-related morbidity and mortality in sub-Saharan Africa. Concurrent chemo-radiation using cisplatin alone, or in combination with 5-fluorouracil is considered the main treatment for FIGO stage 1B2 disease or higher for patients who cannot or choose not to have surgery.

Objective: To report the efficacy of central-shielding external beam radiotherapy in the treatment of grade 1, FIGO stage 1B2 carcinoma of the uterine cervix.

Case description: A 55-year-old female reported a history of backache and post-coital pain associated with vaginal bleeding for three months. She was diagnosed with cervical cancer FIGO stage 1B2 and chose not to have surgery.

Method: A computed tomography scan simulation and three-dimensional treatment planning were done, and a total dose of 45Gy of EBRT was administered in fractions for five weeks. Control ultrasonography was then performed to assess the efficacy of CS-EBRT before initiating intracavitary brachytherapy.

Results: Five weeks of CS-EBRT showed significant tumor regression and improvements in health status.

Conclusion: A well-planned central-shielding radiotherapy alone may be curative in selected patients with cervical cancer FIGO stage IB2. Large-scale studies are warranted to compare the efficacy of concurrent chemoradiation with that of radiotherapy in this patient population.

Keywords: Cervical cancer, Human papillomavirus, External beam radiation, Cisplatin.

Introduction

Cancer of the uterine cervix is a major public health concern in sub-Saharan Africa. In 2020, East Africa alone recorded 54,560 new cases of cervical cancer and had unacceptably high age-standardized incidence (40.1) and age-standardized mortality (28.6) rates than anywhere else on earth [GLOBOCAN, 2020]. The HPV (human papillomavirus) oncogenic proteins E5, E6, and E7 crosstalk with PGE₂ (prostaglandin-E₂) signaling and COX-2 (cyclooxygenase-2) are known to attack and weaken the immune response, consequently leading to the development of cervical cancer (Zheng & Ding, 2018).

Carcinoma of the uterine cervix stage IB – IIA is confined to the cervix and upper vagina. Tumors of stage IB1 (≤ 4 cm) are normally treated with CCRT (concurrent chemo-radiation therapy), while those of stage 1B2 (≥ 4 cm) are treated with radical hysterectomy and pelvic lymph node

¹ **Corresponding author:** Agapiti Hipoliti Chuwa, Ph.D., University of Dar es Salaam, Mbeya College of Health and Allied Sciences, P. O. Box 608, Mbeya, Tanzania, +255 719 666717, chuwa.agapiti@udsm.ac.tz

dissection. However, treatment techniques and modalities must be tailored individually based on clinical, anatomic, and social factors. Accumulating data indicate a notable cure rate with radiotherapy alone for small-stage IB or IIA tumors, whereas the addition of hysterectomy had no survival benefit in this group (Grigsby, 1996). This study, therefore, aimed to investigate the efficacy of central-shielding external beam radiotherapy alone in the treatment of FIGO stage IB2 carcinoma of the uterine cervix.

Case presentation

A 55-year-old female patient presented to the gynaecology department with a three-month history of backache and post-coital pain associated with vaginal bleeding. The patient had five living children and her past obstetric history was insignificant.

Clinical findings

The general condition of the patient was fair, not febrile, and there was no clinical anemia. The patient had a body mass index of 26, blood pressure of 135/90mmHg, and pulse rate of 75 beats per minute.

Diagnostic assessment

Laboratory investigation showed normal urine analysis and normal full blood picture; except for mild anemia (Hb 10g/dl). Speculum examination revealed a hyperaemic cervical lesion about 4-5cm in size, that bled easily when touched. A tissue sample was taken from the lesion and sent for histopathological evaluation. Abdominal-pelvic ultrasonography was then performed and revealed a cervical mass measuring 4.5 x 4.4 x 4.2cm, Fig. 1.

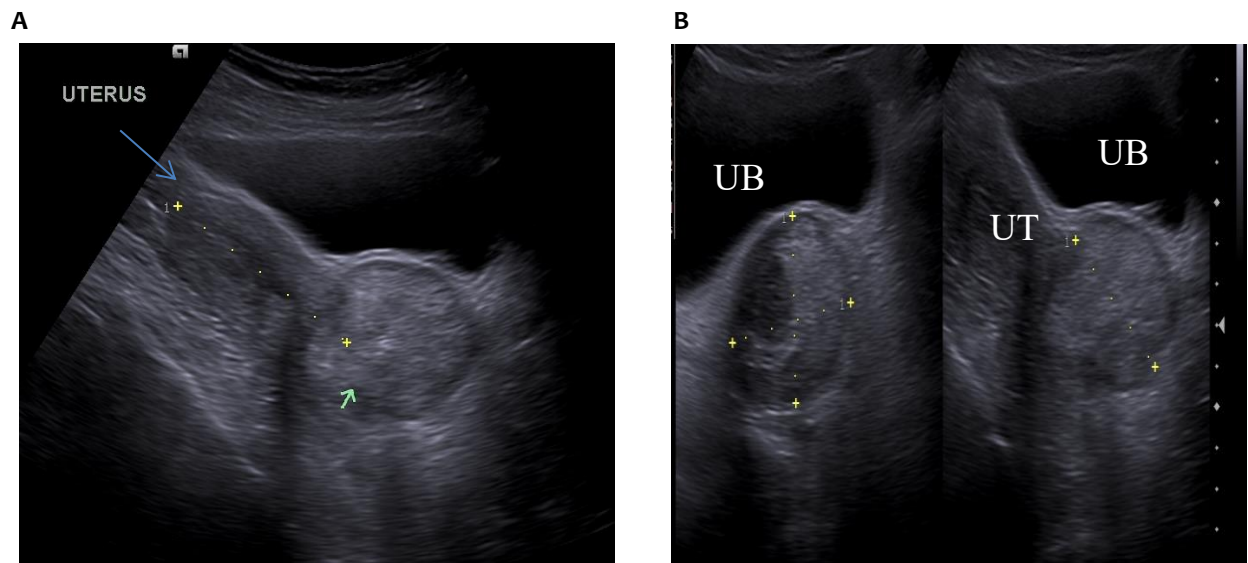


Fig.1 A: An ultrasound image showing a cervical mass (arrow). **B:** Transverse and sagittal images denoting the dimensions of the cervical mass.

There were no signs of hydronephrosis. Biopsy results were positive for a grade 1 invasive squamous cell carcinoma of the uterine cervix. A chest x-ray was ordered to assess for possible lung metastasis but the findings were normal for a chest radiograph. A diagnosis of grade 1, FIGO stage IB2 squamous

cell carcinoma of the uterine cervix was made, and treatment options were explained to the patient and relatives.

Therapeutic intervention

Routine liver and renal function tests were carried out and the patient was simulated on a CT scanner and a three-dimensional conformal RT (3-D CRT) with anteroposterior, and two lateral portals were used for the treatment. The patient received 45Gy of EBRT in 25 fractions of 1.8Gy administered five days a week, for five weeks. The treatment duration was uneventful.

Results

The health status of the patient improved significantly with no backache and without vaginal bleeding. There was a notable regression of the tumor with the size reduced to ≤ 1 cm, Fig. 2.

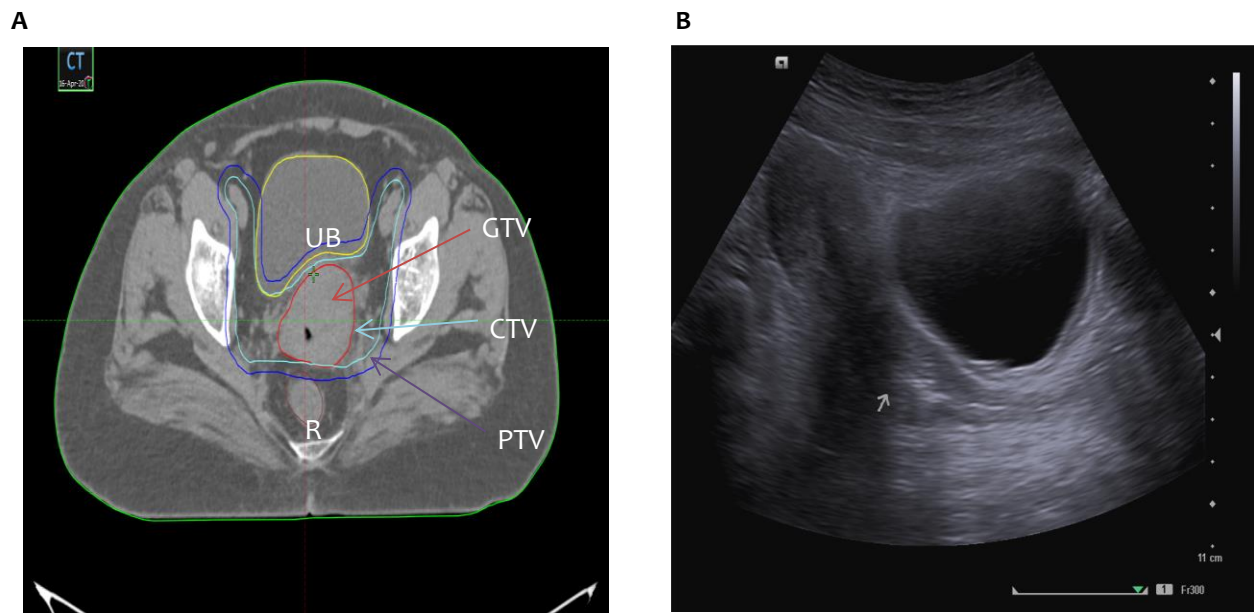


Fig.2. A: Central-shielding EBRT planning. UB- urinary bladder, R- rectum, GTV- gross tumor volume, CTV- clinical tumor volume, PTV- planning tumor volume. **B:** Effect of radiotherapy on the cervical tumor. The arrow shows the place of the original tumor. UT- the uterus.

These findings suggest that the optimal dose of external beam radiotherapy extended to six or seven weeks, plus or minus brachytherapy and without the addition of concurrent weekly cisplatin may be curative for carefully planned patients with carcinoma of cervix stage IB₂.

Discussion

Planning of EBRT with 3-D CRT in the treatment of cervical cancer significantly reduces the dose of ionizing radiation delivered to the organs at risk (OARs) notably; the urinary bladder, rectum, and pelvic joints, consequently lowering the risk for radiation-associated complications. Most treatment protocols now include EBRT and ICBT with CCRT as the standard treatment modality for patients with stages I – IVA carcinoma of the uterine cervix. Definitive radiotherapy for cervical cancer consists of whole-pelvic (WP), CS-EBRT, and brachytherapy.

Our understanding of the benefits of CCRT as the standard treatment for advanced loco-regional cervical tumors has been very dynamic because of the conflicting reports from randomized clinical trials. Eifel and colleagues [Eifel *et al*, 2004] reported a survival benefit and improved local tumor control with concurrent chemo-radiation in 403 patients with carcinoma of cervix FIGO stage IB–IIA (tumor size ≥ 5 cm) who received chemo-radiation with three cycles of cisplatin 75mg/m² and 5-FU 4g/m²/96 hour. On the other hand, Pearcey's group (Pearcey *et al*, 2002) observed no benefit of chemotherapy in 259 patients with similar stages of the tumor who received concurrent chemo-radiation with cisplatin 40 mg/m²/week (up to 6 cycles). This implies that dose and combination factors, as well as patients' characteristics, play a role in the prediction of the outcome in concurrent chemo-radiation therapy. In the case we report here, all such factors were scrutinized and the patient's choice of RT alone was granted, however, with close monitoring.

Treatment recommendations provided by the Group Européen de Curiethérapie–European Society for Therapeutic Radiology and Oncology (GEC-ESTRO) (Haie-Meder *et al*, 2005) provide a clear understanding of the concepts, implications, and terms of the three-dimensional image-guided brachytherapy (3D-IGBT) using computed tomography or Magnetic Resonance Imaging (MRI). These newer technologies make it possible, as in the case presented here, to deliver desired high radiation doses to the tumor while minimizing the doses to adjacent tissues. This addresses not only radiation-associated complications such as fistulas but also increased concerns about chemo-resistance and compliance with chemotherapy.

Conclusions

The findings from this case report suggest a possibility of achieving a curative effect with well-planned radiation therapy alone for a FIGO stage IB₂ carcinoma of the uterine cervix. Large-scale studies and clinical trials are warranted to assess its efficacy versus that of the current practice.

Acknowledgement

The author acknowledges the role played by Dr. Fadhil Selemani, Radiologist, for taking and providing the images used in this case report.

Consent and ethical approval

Permission to publish the case report was obtained from the hospital committee. Written consent was obtained from the patient to report the findings and associated radiological images.

Disclosure

No conflict of interest.

References:

- Eifel PJ, Winter K, Morris M, et al. Pelvic irradiation with concurrent chemotherapy versus pelvic and para-aortic irradiation for high-risk cervical cancer: an update of Radiation Therapy Oncology Group trial (RTOG) 90-01. *J Clin Oncol* 22:872; 2004.
- Grigsby PW. Primary radiotherapy for stage IB or IIA cervical cancer. *J Natl Cancer Inst Monogr*. 1996;(21):61-4.
- Haie-Meder C, Pötter R, Van Limbergen E, et al. Recommendations from Gynaecological (GYN) GEC-ESTRO Working Group (I): concepts and terms in 3D image-based 3D treatment planning in cervix cancer brachytherapy with emphasis on MRI assessment of GTV and CTV. *Radiother Oncol* 2005; 74:235–45.

Pearcey R, Brundage M, Drouin P, et al: Phase III trial comparing radical radiotherapy with and without cisplatin chemotherapy in patients with advanced squamous cell cancer of the cervix. *J Clin Oncol* 20:966, 2002.

World Health Organization: Cervix uteri fact

sheet. <https://gco.iarc.fr/today/data/factsheets/cancers/23-Cervix-uteri-fact-sheet.pdf>.

Zheng Hu., Ding Ma. The precision prevention and therapy of HPV-related cervical cancer: new concepts and clinical implications. *Cancer Med*. 2018 Oct; 7(10): 5217–5236. doi: 10.1002/cam4.1501.