

## CASE REPORT

### Bilateral congenital choanal atresia in a 16-year old girl at Muhimbili National Hospital, Tanzania

ZEPHANIA SAITABAU<sup>1\*</sup>, MARTIN ELIMATH<sup>2</sup>, NDESERUA MOSHI<sup>3</sup>, ENICA RICHARD<sup>3</sup> and DAUDI NTUNAGUZI<sup>3</sup>

<sup>1</sup>Department of Surgery, University of Dodoma, College of Health Sciences, P.O. Box 259, Dodoma, Tanzania

<sup>2</sup>Department of Otorhinolaryngology, Muhimbili National Hospital, Dar es Salaam, Tanzania

<sup>3</sup>Department of Otorhinolaryngology, Muhimbili University of Health and Allied Sciences, Dar es Salaam, Tanzania

#### Abstract

**Background:** Bilateral choanal atresia refers to a congenital anomaly whereby a child is born with bilateral imperforate posterior nares. In most cases the diagnosis is established soon after birth. Establishment of the diagnosis requires a high index of suspicion by clinicians. The objective was thus to report an unusual case which went undiagnosed for many years and review the few available literatures.

**Case presentation:** A 16-year old girl presented to the otorhinolaryngology clinic of Muhimbili National Hospital in Tanzania with a long standing history of bilateral nasal obstruction. The condition was reported to be present since birth and this was accompanied by mouth breathing and persistent bilateral nasal discharge. The patient also reported a history suggestive of respiratory distress after birth which necessitated oxygen therapy and difficulty in breastfeeding where she was kept on expressed breast milk during the first few weeks of life. Nasal endoscopy was done clinic and the diagnosis of bilateral congenital choanal atresia was made. Computerized tomography scan of the nose and paranasal sinuses revealed bilateral choanal atresia of mixed type. Surgical perforation of the atretic choanae without stenting was done endoscopically under general anaesthesia.

**Conclusion:** Bilateral congenital choanal atresia is an otorhinolaryngological emergency and should be established promptly both in resource limited settings and in areas where advanced tools are in situ to prevent its morbidity and mortality if it goes unestablished.

**Keywords:** bilateral, congenital, choanal atresia, Tanzania

#### Background

Choanal atresia is an uncommon anomaly in which a baby is born with imperforate posterior nares. It is due to failure of breakdown of the oronasal membrane at 38 weeks of gestational age. It can be unilateral or bilateral and when it is unilateral, the right nostril is affected more than the left nostril at a ratio of 2: 1 (Anajar et al. 2017). When congenital atresia of the choanae is unilateral, infants may go undiagnosed until unilateral rhinorrhoea and nasal obstruction necessitate seeking medical care. However, bilateral choanal atresia presents with respiratory distress immediately after birth requiring immediate assistance such as establishment of an oral airway because infants are obligate nasal breathers in the first four months of life due to the nature of their larynx where it appears to have high cervical localization at this age. Due to this reason, infants with bilateral choanal atresia are diagnosed in the early postnatal period in nearly all cases (Voegels et al. 2002).

The diagnosis of bilateral choanal atresia in new-borns demands a high index of suspicion, since the symptoms can vary from a mild difficulty in breathing during breastfeeding to severe upper airway obstruction (Voegels et al., 2002). Establishing the diagnosis of choanal atresia can be by nasal endoscopy as a routine evaluation at the clinic in suspected patients and by computerized tomography (CT) scan of the paranasal sinuses. Other bedside tests which may be practicable in resource limited settings include using a piece of thread and alternately putting close to each nostril and observe flipping movement of such thread, introducing a nasal catheter into each nostril and visualize it at the oropharynx if has patent choanae, introducing methylene blue

\* Correspondence Email: [zsaitabau@yahoo.com](mailto:zsaitabau@yahoo.com)

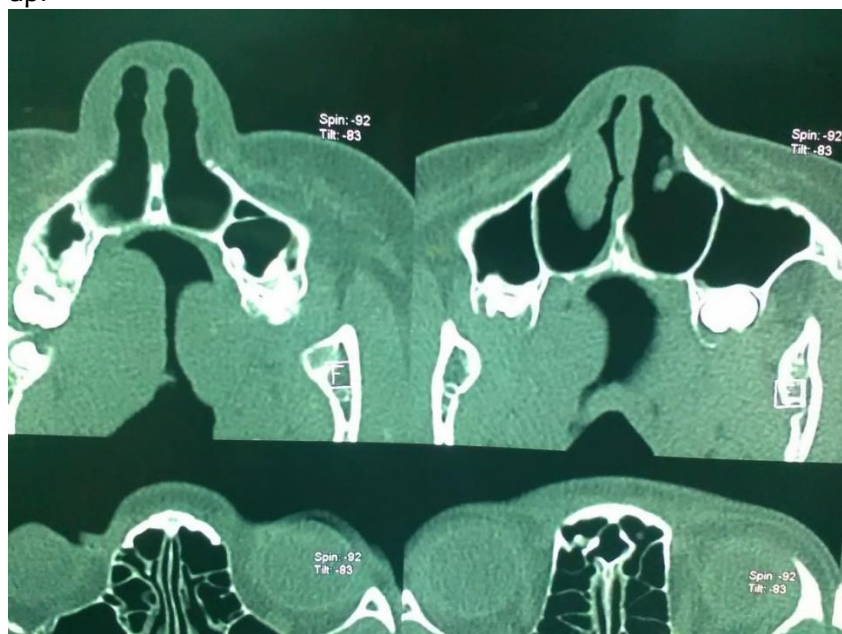
dye into each nostril and observe its presence at the oropharynx and lastly using a mirror alternately where it is placed close to one nostril after the other while observing for the presence of fog on the mirror in presence of patent choanae (Coniglio *et al.*, 1988; Cumberworth *et al.*, 1995; Brown *et al.*, 1996; Anderhuber & Stammberger, 1997; Mays *et al.*, 2013; Yasar & Ozkul, 2016; Panda *et al.*, 2017).

Though nasal endoscopy has been currently advocated as a result of advancement in diagnostic evaluation of surgical patients (Cumberworth *et al.*, 1995; Anderhuber & Stammberger, 1997; Eladl 2010; Gawai & Mail 2016), this may be difficult to perform due to small size of the child's nasal cavity and the extreme discomfort it causes thus can't be tolerated in new-born babies and children without general anaesthesia (Voegels *et al.* 2002). Bilateral congenital choanal atresia is an otorhinolaryngological emergency and should include prompt establishment of oral airway and inserting an orogastric tube while waiting for definitive surgical release of atretic plate. The currently available surgical techniques are microscopic and endoscopic transnasal, transpalatal, transseptal and transantral approaches (Eladl, 2010; Tatar *et al.*, 2012; Saraniti *et al.*, 2016).

We report an unusual case of a teenage girl with bilateral choanal atresia who was diagnosed after presenting at the otorhinolaryngology (ENT) clinic of Muhimbili National Hospital in Dar es Salaam, Tanzania. The objective of the case report was thus to emphasize on the modalities of establishing the diagnosis of bilateral congenital choanal atresia even in resource limited settings and highlight on the current endoscopic technique of choanal atresia release.

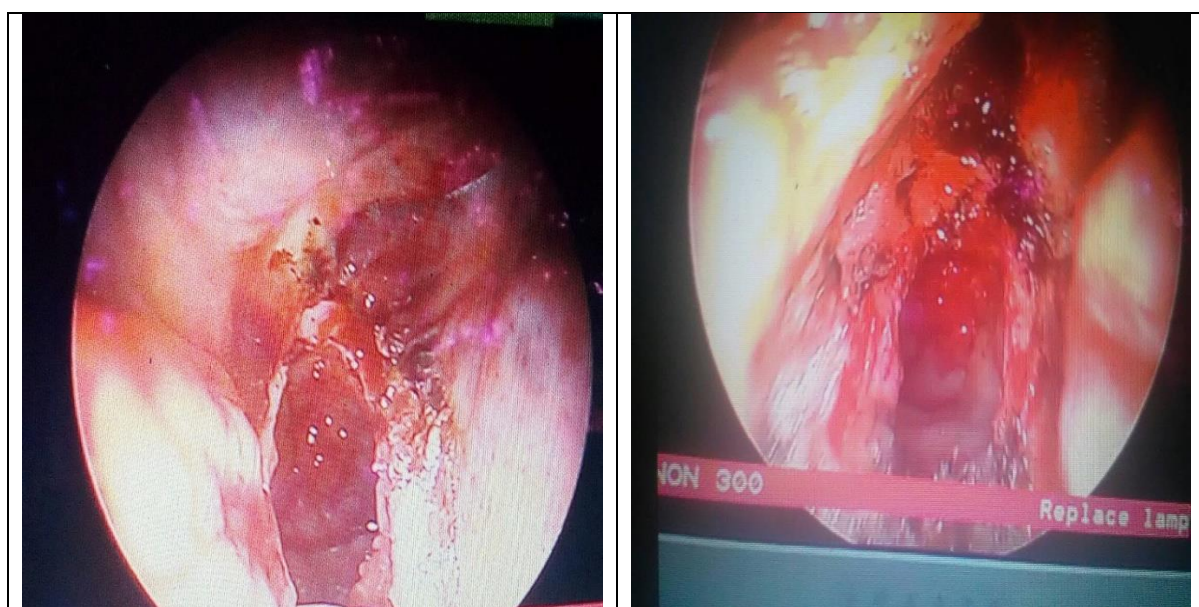## Case Presentation

The 16-year old girl presented to the clinic after being referred from one of the peripheral health facility following a long standing history of bilateral nasal obstruction and running nose associated with mouth breathing. Despite having respiratory distress after birth that necessitated her the provision of supportive medical care such as oxygen therapy for several days and a concurrent history of difficult in breastfeeding for several weeks of life, the clinicians who attended the patient during her early days of life didn't suspect the condition. Nasal endoscopy, computerized tomography (CT) scan of the nose and paranasal sinuses were used to establish the diagnosis and thereafter endoscopic choanal atresia release was performed and the patient was closely followed up.



**Figure 1: CT scan (axial view) showing occlusion of the bilateral posterior choanae confirming bilateral mixed choanal atresia**

Natal history noted was difficulty in breathing and breastfeeding which necessitated oxygen therapy and expressed breast milk for several weeks of life despite being born at term (39 weeks of gestational age). Multiple visits to peripheral health facilities assured the mother that the symptoms of nasal obstruction and running nose would subside with time because they were due to allergy. She was kept on repeated doses of antihistamines, oral and injectable steroids, local nasal steroids and decongestants plus antibiotics without permanent relief. Her mother denied prenatal cigarette smoking or alcohol or caffeine consumption and there was also no reported maternal history suggestive of prenatal thyrotoxicosis. There was also no family history of similar illness. When the patient was presented to the ENT clinic, rigid nasal endoscopy was done and the diagnosis of bilateral choanal atresia was established. CT scan of the nose and paranasal sinuses was ordered and confirmed the diagnosis of bilateral mixed choanal atresia (bony and membranous) (Figure 1).



**Figure 2: Endoscopic appearance of the choanae post release**

After discussing with her mother and completing all the recommended preoperative work, endoscopic choanal atresia release was performed at the operating theatre. Intraoperatively, bilateral imperforate posterior nares were found and release was performed by taking down the vomer and the atretic choanal plate. No stents were kept in situ (Figure 2).

## Discussion

Bilateral choanal atresia is not as common as unilateral choanal atresia and less than half of patients presented with choanal atresia have other associated anomalies such as Coloboma of the eye, heart defects, atresia of the choanae, retardation of growth and/or development, genital and/or urinary defects, ear anomalies (CHARGE) syndrome (Tatar *et al.*, 2012). In the presence of such associated anomalies, management of choanal atresia requires a multidisciplinary approach. In our setting, establishment of these associated anomalies however depends on how knowledgeable the first clinicians consulted by the patient are, usually at a peripheral health facility and the presence of an effective health care referral system that will channel such patients to specialized hospitals where a comprehensive diagnosis and expertise treatment is executed. The atretic plate in such patients may be bony, membranous or mixed and CT scan is recommended to establish the diagnosis and also as a guide during surgical perforation of the atretic choanae (Harner *et al.*, 1981; Cumberworth *et al.*, 1995; Anderhubert & Stammberger, 1997; Ramsden *et al.*, 2009; Eladl *et al.*, 2010; Gawai & Mail, 2016).

Female predominance has been reported in the occurrence of choanal atresia with a male to female ratio being 1:2 (Gawai & Mail, 2016). Incidence is reported to be 1 in 5000 to 1 in 8000 live births (Aksoy *et al.*, 2009; Yasar & Ozkul, 2016). Bilateral choanal atresia is a life threatening condition and an index of suspicion is required during early neonatal life so that definitive interventions may be instituted. Without intervention, in some cases, patients may progress to adulthood but with frequent visits to the hospital for ENT related complaints. Patients classically present paradoxical cyanosis during early neonatal life but later on persistent running nose, snoring and mouth breathing may be the only complaints. Use of oral airways and insertion of a nasogastric tube should be the first line of management of new-born babies with bilateral choanal atresia because new-born babies are obligate nasal breathers thus prone to respiratory distress when the posterior nares are atretic (Aksoy *et al.*, 2009; Tatar *et al.*, 2012; Saraniti *et al.*, 2016).

There are several documented cases of bilateral choanal atresia which were established at older age and all these implies low index of suspicion by health care providers working at levels where Otorhinolaryngologists aren't available. All such cases had unique presentation at birth such as difficulty in breathing and breastfeeding at birth which in most occasions necessitated oxygen therapy (Voegels *et al.*, 2002; Tatar *et al.*, 2012; Mays *et al.*, 2013; Gawai & Mail, 2016; Yasar & Ozkul, 2016). This was overlooked possibly because of not taking thorough natal history when encountering adult patients. When working in resource limited settings where access to CT scan and endoscopic tools aren't available, establishing the diagnosis of bilateral choanal atresia shouldn't go undiagnosed because there are abundant bedside tests available to test the patency of both nostrils including use of methylene blue dye, nasal catheter, use of mirrors by observing fog on the mirror and again by use of a piece of thread alternately in both nostrils where one observe flipping action in case the tested nostril is patent. Moreover, whenever having patients with rhinological complaints, anterior and posterior rhinoscopy are mandatory to avoid missing such important diagnoses which when left unestablished till later ages tend to impair the quality of ones' life through frequent hospital visits.

At the Muhimbili National Hospital, choanal atresia release is performed endoscopically in operating theatre under general anaesthesia. From the case presented, it's clear that clinicians should have a high index of suspicion when faced by patients with rhinological complaints to avoid missing such rare but important diagnoses as bilateral choanal atresia. A timely diagnosis in this case would have alleviated morbidity, save costs incurred in recurrent hospital visits and medications, and the time lost. Clinicians should bear in mind congenital anomalies that may co-exist in life when dealing with adult patients especially those having longstanding complaints that are pertinent with some congenital anomalies. Thorough investigations and cross consultation with specialists should precede reassurance. Surgical intervention of bilateral choanal atresia must be done so as to improve the quality of life of the sufferers of which this was lately done to our patient because the diagnosis was also established at later ages.

### **Ethical considerations**

This case report received approval from Muhimbili University of Health and Allied Sciences. A written informed consent to publish the surgical condition was sought from the patient and her guardian.

### **Competing interests**

The authors declare that they have no competing interests

### **Authors' contributions**

ZAS, MEM participated in operating the patient. ZAS, NM, ER, MEM, DN wrote and proof read the manuscript.

## Acknowledgements

The authors acknowledge Dr. Shubi Matovelo, of the University of Dodoma, College of Health Sciences for his tangible contributions in proof reading the manuscript.

## References

- Aksoy, F., Demirhan, H., Yildirim, Y. S., & Ozturan, O. (2009). Bilateral choanal atresia in an adult-management with mitomycin C and without stents: a case report. *Cases Journal* 2: 9307.
- Anderhuber, W., & Stammberger, H. (1997). Endoscopic surgery of uni-and bilateral choanal atresia. *Auris Nasus Larynx* 24: 13-19.
- Anajar, S., Hassnaoui, J., Rouadi, S., Abada, R., Roubal, M., & Mahtar, M. (2017). A rare case report of bilateral choanal atresia in an adult. *International Journal of Surgery Case Reports*, 37, 127–129. <https://doi.org/10.1016/j.ijscr.2017.05.002>
- Brown, O.E., Pownell, P., & Manning, S. C. (1996). Choanal atresia: a new anatomic classification and clinical management applications. *Laryngoscope* 106: 97–101.
- Tinoco, P., Pereira, J.C.O., Lourenço Filho, R.C., Brito, T.S.C., Pereira, B.M., Carrara, V.L. & Godoy, S.M.F. (2010) Bilateral choanal atresia in 34 year-old patients. *Arquivos Internacionais de Otorrinolaringologia* 14: 481-484.
- Coniglio, J.U., Manzione, J.V. & Hengerer, A.S. (1988) Anatomic findings and management of choanal atresia and the CHARGE association. *Annals of Otology, Rhinology and Laryngology* 97: 448–453.
- Cumberworth, V.L., Djazaeri, B. & Mackay, I.S. (1995) Endoscopic fenestration of choanal atresia. *Journal of Laryngology and Otology* 109: 31–35.
- da Fontoura Rey Bergonse, G., Carneiro, A.F. & Farah Vassoler, T.M. (2005) Choanal atresia, analysis of 16 cases - the experience of HRAC-USP from 2000 to 2004. *Brazilian Journal of Otorhinolaryngology* 71: 730–733.
- Eladl, H.M. (2010). Transnasal endoscopic repair of bilateral congenital choanal atresia: controversies. *Journal of Laryngology and Otology* 124: 387-392.
- Gawai, S.A. & Mail, N.J.S. (2016) Bilateral complete congenital choanal atresia in an adult managed endoscopically with mucosal flaps without stenting. *Otolaryngology Online Journal*.
- Harner, S.G., McDonald, T.J. & Reese, D.F. (1981) The anatomy of congenital choanal atresia. *Otolaryngology-Head and Neck Surgery* 89: 7-9.
- Mays, A.C., Marcum, K.K., & Kirse, D. J. (2013) Late presentation of bilateral choanal atresia in a 10-year-old child with Moyamoya disease. *Journal of Case Reports in Medicine* 1: 1–3.
- Panda, N. K., Simhadri, S., & Ghosh, S. (2004). Bilateral choanal atresia in an adult: is it compatible with life?. *Journal of Laryngology & Otology* 118(3), 244-245.
- Pirsig, W. (1986) Surgery of choanal atresia in infants and children: Historical notes and updated review. *International Journal of Pediatric Otorhinolaryngology* 11: 153–170.
- Ramsden, J.D., Campisi, P. & Forte, V. (2009) Choanal atresia and choanal stenosis. *Otolaryngologic Clinics of North America* 42: 339–352.
- Saraniti, C., Santangelo, M. & Salvago, P. (2016) Surgical treatment of choanal atresia with transnasal endoscopic approach with stentless single side-hinged flap technique: 5 year retrospective analysis. *Brazilian Journal of Otorhinolaryngology* 83: 183–189.
- Tatar, E.Ç., Ozdek, A., Akcan, F. & Korkmaz, H. (2012) Bilateral congenital choanal atresia encountered in late adulthood. *Journal of Laryngology and Otology* 126: 949–951.
- Verma, R.K., Lokesh, P., & Panda, N.K. (2016) Congenital bilateral adult choanal atresia undiagnosed until the second decade: How we did it. *Allergy & Rhinology* 7: 82–84.

- Voegels, R.L., Chung, D., Lessa, M.M., Lorenzetti, F.T.M., Goto, E.Y. & Butugan, O. (2002) Bilateral congenital choanal atresia in a 13-year-old patient. *International Journal of Pediatric Otorhinolaryngology* 65: 53–57.
- Yasar, H. & Ozkul, M.H. (2016) Bilateral congenital choanal atresia in a 51-year-old woman. *American Journal of Rhinology* 21: 716–718.