

SHORT COMMUNICATION

Pattern of presentation and outcome of patients treated for Fournier's gangrene at Kilimanjaro Christian Medical Centre in Moshi, Tanzania

PASCHAL MABULA^{1*}, OBADIA V. NYONGOLE² and KIEN A. MTETA^{1,3}

¹Department of Urology, Faculty of Medicine, Kilimanjaro Christian Medical University College, P.O. Box 2240, Moshi, Tanzania

²School of Medicine, Muhimbili University of Health and Allied Sciences, Dar es Salaam, Tanzania

³Bugando Medical Centre, Mwanza, Tanzania

Abstract

Background: Fournier's gangrene (FG) is a rapidly progressive and potentially fatal infective necrotizing fasciitis which affects the perineal and perianal regions as well as the external genitalia. This study aimed at evaluating the management of FG and its outcomes at Kilimanjaro Christian Medical Centre (KCMC) in Moshi, Tanzania

Methods: This was a retrospective hospital based study involving case notes of all patients who had Fournier's gangrene at KCMC from January 2003 to December 2013. Patients managed for Fournier's gangrene and the medical records of the patients eligible for the study retrieved manually.

Results: A total of 25 case notes of patients treated for Fournier's gangrene during the study period were reviewed. All were males and majority of them (60%) were ≥ 50 years (mean=57.4 years). Hypertension was the commonest reported risk factor (41%). Diabetes mellitus was reported as a risk factor in 20% of all patients with FG. These risk factors were mentioned as comorbid conditions in traumatic urethral catheterization and suprapubic catheterization. All patients received a combination treatment of wound debridement, antibiotics, fluid replacement, analgesics and daily wound dressing. The average hospital stay for patients with FG was about 25 days.

Conclusion: Fournier's gangrene at KCMC is exclusively a male disease affecting those above 50 years. Hypertension and diabetes mellitus were the common comorbid condition in patients with Fournier's gangrene.

Keywords: Fournier's gangrene, management, outcome, Tanzania

Fournier's gangrene (FG) is a rare infective necrotizing fasciitis which affects the perineal, genital or perianal regions as well as the external genitalia (Jones *et al.*, 1979). The infection is commonly confined to Colles' fascia (Norton *et al.*, 2002). Fournier's gangrene is reported to be a synergistic infection involving a mixture of microorganisms, commonly being *Escherichia coli*, *Streptococcus*, *Staphylococcus*, *Bacteroides*, *Pseudomonas* and *Enterococcus* ((Nomikos, 1998; Morpurgo & Galanduk, 2002; Townsend *et al.*, 2004; Bosoglu *et al.*, 2007). Fournier's gangrene has a rapid rate of tissue destruction (necrosis) and is considered as one of the emergences in most Urology departments (Sorensen *et al.*, 2009; Sarwar & Akhtar, 2012).

Causes of Fournier's gangrene are classically classified into four major groups, which are: Ano-rectal causes, Urogenital causes, Dermatologic causes and Surgical trauma. The condition is usually associated with various risk factors which include diabetes mellitus, alcoholism, morbid obesity, hypertension, chronic disease, malnutrition, old age (>50 years), malignancies, systemic lupus erythematosus, immune system disorders like HIV/AIDS and long term steroid therapy (Townsend *et al.*, 2004).

The treatment of Fournier's Gangrene and outcomes in most settings has been reported to depend on combined various treatment options and early diagnosis (Cakmak *et al.*, 2008; Ugwumba *et al.*, 2012). Tissue debridement, multi-antibiotics, hyperbaric oxygen therapy, supportive management like fluid therapy and electrolyte regulation, blood transfusion especially

* Correspondence E-mail: mabula.paschal@rocketmail.com

after extensive tissue debridement, daily dressing of wounds, removal of non-vital organs, reconstructive and grafting in cases of severe tissue destruction have been described as common treatment options (Resnick & Novick, 2003). Treatment of FG requires many days of hospitalization for a patient to attain a good prognosis (Ugwumba *et al.*, 2012).

Fournier's gangrene has various complications as reported by many clinicians. These include septic shock due to overwhelming infection, excessive dehydration due to fluid loss from the destructed skin, electrolyte imbalance, severe anemia, loss of some organs, painful erection due to scaring and death (Clayton *et al.*, 1990; Paty & Smith, 1992; Morpurgo & Galandiuk, 2002; Korkut *et al.*, 2003; Benjeloun *et al.*, 2013). This retrospective, hospital based study aimed at evaluating the management of Fournier's gangrene and its outcomes at Kilimanjaro Christian Medical Centre in northern Tanzania.

This was a retrospective hospital based study conducted at KCMC, which is a tertiary referral hospital receiving patients from districts and regional hospitals from the Central and northern zone. It involved case notes of all patients who had Fournier's gangrene at KCMC from January 2003 to December 2013. Case notes with incomplete information to fulfill the requirement of this study were excluded from the study including case notes of those who were lost to follow up. Checking of the questionnaire for completeness was done and the entered into computer for analysis where SPSS version 18 was used to analyze the information. Cross-tabulations were generated, and where comparisons were made, significance was considered at p-value of less than 0.05.

Ethical clearance number 672 and permission was obtained from Community Department, Kilimanjaro Christian Medical University College and Urology department at KCMC Referral Hospital. All patients' information was kept confidential; no patient's direct identifiers were used in the data collection instrument. Those case notes for review were directly returned to medical records department by the researcher after extracting relevant information to maintain confidentiality.

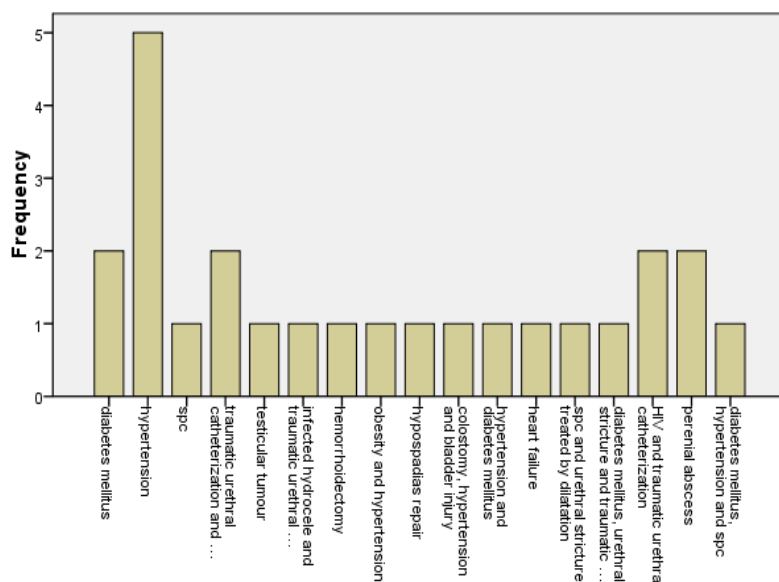


Figure 1: Risk factors and causes of Fournier' gangrene at KCMC

A total of 25 case notes of patients treated for Fournier's gangrene during the study period of ten years were reviewed. All were males (mean age=57.4 years); majority (60%) were +50 years old. Hypertension was the commonest (41%) among patients with FG. Diabetes mellitus was reported in 20% of the patients with FG. Both hypertension and diabetes were common comorbid conditions in traumatic urethral catheterization and suprapubic catheterization (SPC). Other risk factors like hemorrhoidectomy, testicular tumor, perineal abscess, HIV and infected hydrocele as

well as hypospadias were also found to contribute on FG (Figure 1). Incomplete documentation denied review of some case notes.

Majority of study participants (84%) reported scrotal ulcer, scrotal swelling, scrotal abscess and scrotal pain as main presentation. A combination of clinical presentation in most of the patients (28%) was pus discharge, scrotal abscess and fever (Figure 2).

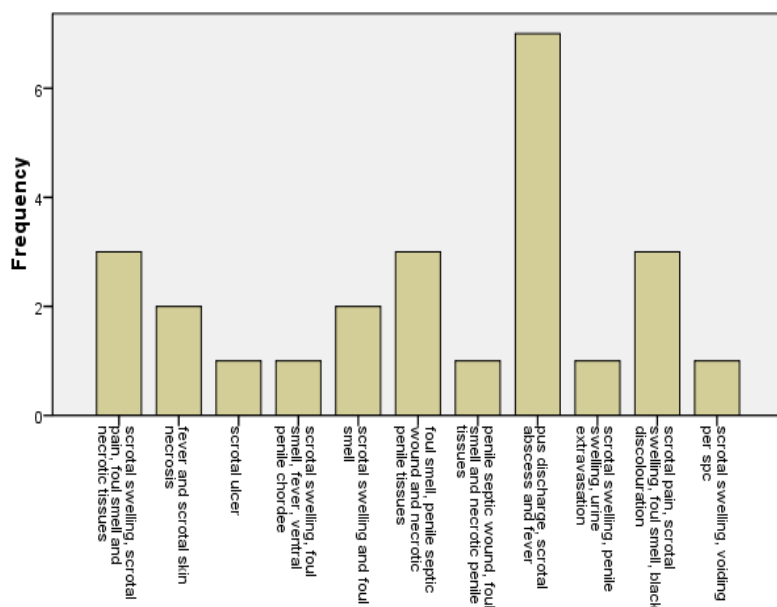


Figure 2: Clinical presentation of Fournier' gangrene among patients at KCMC

Full blood picture was done for 68% followed by HIV serology tests (52%) and other investigations such as random blood sugar, scrotal ultrasound which in 32% of all patients. Tissue biopsy for histopathological examination was done to two patients only. All patients in our study received a combination treatment of wound debridement, antibiotics, fluid replacement, analgesics and wound daily dressing. Blood transfusion was given to 64% of all the patients. Seven patients (28%) had skin grafting done. Orchiectomy was done to one patient. Blood sugar and hypertension were controlled using individualized treatment protocol. The average hospital stays for patients with FG admitted at KCMC was 25 days. Thirty-six percent of all the patients stayed at hospital between 10 and 20 days with an exception of 4 patients (16%) who had a hospital stay of more than 50 days. Thirty-two percent of all patients had good outcomes with few complications reported by 24% of patients. Three patients died mainly due to severe septicemia.

In this study we found FG being exclusively a male disease affecting men aged above 50 years. This could be explained by the fact that as age increases the immunity system becomes weaker predisposing an individual to infections, also with increase in age the risk for diseases such as hypertension and diabetes mellitus these diseases are among risk factors for FG development (Townsend *et al.*, 2004). This is similar to other studies which reported FG being more common among individual aged above 60 years (Sorensen *et al.* 2009).

Hypertension and diabetes mellitus in this study were found to be the commonest risk factors to most of the FG patients. Diabetes mellitus has been reported as one of the common risk factor predisposing to FG as in a study in Kenya (Ayumba & Magoha, 1998). Traumatic urethral catheterization has been found to be among the main causes and risk factor for FG. Other risk factors such as hemorrhoidectomy, hypospadias repair, treatment of urethral stricture by dilatation, infected hydrocele and colostomy have also been described to be associated with FG (Gurfinkel *et al.*, 2005; Al-Ali *et al.*, 2012; Tolga *et al.*, 2014).

In a study in Nigeria, the major clinical presentations for patients with FG were perineal itching and tenderness, fever and drowsiness, genital pain and erythema, crepitant skin, discolored and dead tissues, cellulitis and a rapid tissue destruction (Ugwumba *et al.*, 2012). This is not far from our findings in which scrotal swelling, scrotal ulcer, scrotal pain, foul smell, black discoloration necrotic tissue and fever were the main presentation. Similar to our findings, several combined treatments which includes fluid intake, correction of electrolytes imbalance, multiple antibiotics, debridement, daily wound inspection and dressing with hydrogen peroxide or sodium hypochloride have also been reported from eastern Nigeria (Ugwumba *et al.*, 2012). The average hospital stays of 25 days observed in this study is likely to cause enormous cost for most of FG patients. Similar long hospital stays have been reported elsewhere (Cakmak *et al.*, 2008).

Fournier's gangrene has been associated with a number of complications. Anemia in FG is commonly due to repeated debridement procedures while dehydration and electrolyte imbalance is due to skin destruction which leads to easy loss of fluid from the body (Benjelloun *et al.*, 2013). In Malawi, most patients with FG presented with shorter penis associated with painful erection due to loss of tissues and scarring of the wounds (Lema, 2003). Elsewhere, studies have shown that tissue damage due to FG may extend to the penis, anterior abdominal wall, buttocks, or thighs (Flanigan *et al.*, 1978; Clayton *et al.*, 1990). In our study, most of patients with FG attained good outcomes with the adequate treatment given. The death of the three patients in our study was likely to be due to various complications like heart diseases which restricted the debridement surgical procedures as the patients were unfit for surgery.

In conclusion, FG at KCMC is exclusively a male disease affecting those above 50 years. Hypertension and diabetes mellitus were the common comorbid conditions among patient in this area of northern Tanzania. This study was done at Kilimanjaro Christian Medical Centre in Moshi, thus the findings may not reflect a true image of the magnitude of FG country wise.

Competing interests

No competing interests to the authors

Authors' contributions

PM designed the study, collected data, performed data analysis and wrote the first draft of the manuscript. OVN, AKM participated in the study design and manuscript preparation. All authors read and approved the final version of the manuscript.

Acknowledgements

Authors are thankful to the Department of Community Health of the Kilimanjaro Christian Medical Centre for the help and support.

References

- Al-Ali, B.M., Popper, H. & Pummer, K. (2012) A case of Fournier's gangrene after hydrocelectomy. *Central European Journal of Urology* 65, 92-93.
- Ayumba, B.R. & Magoha, G.A. (1998) Epidemiological aspects of Fournier's gangrene at Kenyatta National hospital, Nairobi. *East African Medical Journal* 75, 586-589.
- Benjelloun, E.B., Souiki, T., Yakla, N., Ousadden, A., Mazaz, K., Louchi, A., Kanjaa, N. & Taleb, K.A. (2013) Fournier's gangrene: Our experience with 50 patients and analysis of factors affecting mortality. *World Journal of Emergency Surgery* 8:13

- Bosoglu, M., Ozbey, I., Atamanalp, S.S., Yildirgan, M.I., Aydinli, B., Polat, O., Ozturk, G., Peker, K., Onbas, O. & Oren, D. (2007) Management of Fournier's gangrene: review of 45 cases. *Surgery Today* 37, 558–563.
- Cakmak, A., Genç, V., Akyol, C., Kayaoğlu, H.A. & Hazinedaroğlu, S.M. (2008) Fournier's gangrene: is it scrotal gangrene? *Advances in Therapy* 25, 1065-1074.
- Clayton, M.D., Fowler, J.E., Sharifi, R. & Pearl, R.K. (1990) Causes, presentation and survival of fifty-seven patients with necrotizing fasciitis of the male genitalia. *Surgery Gynecology and Obstetrics* 170, 49–55.
- Flanigan, R.C., Kursh, E.D., McDougal, W.S. & Persky, L. (1978) Synergistic gangrene of the scrotum and penis secondary to colorectal disease. *Journal of Urology* 119, 369–371.
- Gurfinkel, R., Slovik, Y., Glezinger, R. & Walfisch, S. (2005) Fournier's gangrene as a delayed complication of closed hemorrhoidectomy. *Harefuah* 144, 394-396
- Jones, R.B., Hlrshmann, J.V., Brown, G.S. & Tremann, J.A. (1979) Fournier's syndrome: necrotizing subcutaneous infection of the male genitalia. *Journal of Urology* 122, 279–282.
- Korkut, M., Icoz, G., Dayangac, M., Akgün, E., Yeniay, L., Erdoğan, O. & Çal, Ç. (2003) Outcome analysis in patients with Fourniers gangrene: Report of 45 cases. *Diseases of Colon and Rectum* 46, 649–652.
- Lema, V.M. (2003) Fournier's gangrene complicating vasectomy. *East African Medical Journal* 80, 492-496.
- Morpurgo, E. & Galandiuk, S. (2002) Fournier's gangrene. *Surgical Clinics of North America* 82, 1213–1224.
- Nomikos, I.N. (1998) Necrotizing perineal infections (Fournier's disease): old remedies for an old disease. *International Journal of Colorectal Disease* 13, 48–51
- Norton, K.S., Johnson, L.W., Perry, T., Perry, K.H., Sehon, J.K. & Zibari, G.B. (2002) Management of Fournier's gangrene: an eleven-year retrospective analysis of early recognition, diagnosis, and treatment. *American Surgeon* 68, 709–713.
- Paty, R., Smith, A.D. (1992) Gangrene and Fournier's gangrene. *Urologic Clinics of North America* 19, 149–162.
- Resnick, M.I. & Novick, A. (2003) *Urology Secrets*. 3rd Edition. Elsevier
- Sarwar, U. & Akhtar, N. (2012) Fournier's gangrene developing secondary to infected hydrocele: A unique clinical scenario. *Urology Annals* 4, 131-134
- Sorensen, M.D., Krieger, J.N., Rivara, F.P., Broghammer, J.A., Klein, M.B., Mack, C.D. & Wessells, H. (2009) Fournier's Gangrene: Population Based Epidemiology and Outcomes. *Journal of Urology* 181, 2120-2126.
- Tolga, D., Kayilioglu, S.I., Sozen, I., Yildiz, B.D., Coskun, F. (2014) Fournier's Gangrene as a Postoperative Complication of Inguinal Hernia Repair. *Case Reports in Surgery* 2014, 408217.
- Townsend, C.M., Beauchamp, R.D., Evers, B.M. & Mattox, K.L. (2004) Sabiston Textbook of Surgery: The Biological Basis of Modern Surgical Practice. 19th Edition.
- Ugwumba, F.O., Nnabungwu, I.I., Ozoemena, O.F. (2012) Fournier's gangrene - analysis of management and outcome in south-eastern Nigeria. *South African Journal Surgery* 50, 16-19.