

## Expression of c-myc, bcl-2 and survivin in cutaneous and oral squamous cell carcinoma, basal cell carcinoma and actinic keratosis

Rungsiyanont S<sup>1</sup>, Swasdison S<sup>2</sup> and Chang PL<sup>3</sup>

<sup>1</sup>Assistant Professor, Department of Oral Surgery and Oral Medicine, Faculty of Dentistry, Srinakharinwirot University, Wattana, Bangkok, Thailand.

<sup>2</sup>Associate Professor, Department of Oral Pathology, Faculty of Dentistry, Chulalongkorn University, HenryDunant, Bangkok, Thailand.

<sup>3</sup>Associate Professor, Department of Nutrition Sciences, University of Alabama, Birmingham, Alabama, USA.

Rungsiyanont S, Swasdison S and Chang PL.

Expression of c-myc, bcl-2 and survivin in cutaneous and oral squamous cell carcinoma, basal cell carcinoma and actinic keratosis. *Tanz Dent J* 2010, 16 (1):3-8.

### Abstract

Genes involved in apoptosis are important and over expression of these genes are thought to contribute to carcinogenesis. **Aim:** to evaluate the expression of anti-apoptotic factors in a series of epithelial malignancies and actinic keratosis using immunohistochemistry. **Design:** Laboratory microscopy of stained biopsy specimen. **Materials and methods:** Sections of specimens diagnosed as cutaneous-SCCs (CSCC), oral-SCCs (OSCC), basal cell carcinoma (BCC) and actinic keratosis (AK) were stained by using c-myc, bcl-2 and survivin antibodies. **Results:** In AK, c-myc expression was found in the nuclei of epithelium mostly in basal cell layers. In BCC, CSCC and OSCC, c-myc expression was found in both the nuclear and cytoplasmic regions of the tumor cells. Among all the cancer tissues, OSCC showed the strongest positive staining for c-myc. The expression of bcl-2 and survivin in AK were also found mostly as nuclear staining in the basal cell layer areas, while in the other cancer tissues, positive staining were found in both the nucleus and cytoplasm of the tumor cell. **Conclusion:** c-myc expressions correspond to the survivin expressions. c-myc expression was stronger in OSCC than in CSCC and BCC, and weaker in AK than in other malignant tumors.

**Key Words:** c-myc, bcl-2, suvivin, cancer, immunohistochemistry.

**Correspondence:** Somporn Swasdison, D.D.S., Ph.D., Department of Oral Pathology, Faculty of Dentistry, Chulalongkorn University, Bangkok 10330, Thailand. E-mail: [ssomporn@chula.ac.th](mailto:ssomporn@chula.ac.th)  
Fax: 662-2188798, Phone: 662-2188801

### Introduction

Incidence of human cancers has been increasing in the past decade as shown by many epidemiological studies. For the non-melanoma skin cancer, cutaneous squamous cell carcinoma and basal cell carcinoma are the most studied cancers because of their high incidence and aggressiveness (1-4). Many researches have focused on the biomarkers, molecular biology and clinicopathological parameters of these malignancies in order to better understand disease pathogenesis, behavior and therefore improve diagnosis, prevention and treatment strategies for these malignancies (5,6).

Actinic keratosis, a potentially malignant disorder, has also been a focus of attention due to its high risk of transformation into squamous cell carcinoma. Actinic keratosis is a disorder of the vermillion of the lips that results mainly from the chronic exposure to the ultraviolet (UV). Its histopathological findings

can be varied from hyperkeratosis to varying grades of dysplasia ranging from mild to severe or carcinoma in situ which is considered to be early stage of squamous cell carcinoma (7). Many previous studies have shown data which correlated the actinic keratosis and squamous cell carcinoma by the senses of their biomarkers expression and pathobiology (5,6,8,9).

Malignant tumors are considered the result of a complex process, which involves a number of aberrant genetic events. Multiple oncogenes, regulatory factors and tumor suppressor genes play a key role in the development and progression of these cancers. In recent years, there have been many researches focused on the biomarkers which are involved in the pathogenesis or the progression of cancers, and might affect the cancer behaviors and their prognosis. One of biomarkers which many studies mentioned is c-myc which is a proto-

oncogene and plays a role in many cellular processes, such as cellular proliferation, differentiation and apoptosis. It is also an early response gene necessary for cell cycle progression (G1-S transition) and G0-G1 transition (10-12). C-myc is a transcription factor and is frequently overexpressed in some oral cancers as a result of c-myc gene amplification (13,14). Overexpression and amplification of c-myc are shown to be implicated in the development and progression of some cancers, including squamous cell carcinoma in the head and neck regions. Further, it is associated with the loss of cell differentiation in oral squamous cell carcinoma (15-19).

Another protein which is a well-known as its roles of anti-apoptotic activities is bcl-2. There are some gene transfer experiments have shown that elevated levels of this protein can protect a wide variety of cells from diverse cell death stimuli ranging from growth factor withdrawal and cytotoxic lymphokines to virus infection and DNA damaging agents (20,21). Expression of Bcl-2 protein was reported to increase cellular proliferation in early oral carcinogenesis, increased risk and progression of squamous cell carcinoma of the head and neck (10,20,22).

Survivin is another one of protein which are referred to as a inhibitor of apoptotic protein. It is expressed during the G2/M phase of the cell cycle and is associated with microtubules of the mitotic spindle. (Increases caspase-3 activity is detected when a disruption of survivin-microtubule interactions occurs) (23). Over expression of this protein was shown to result in the increasing of tumor cell proliferation. The correlation between the severity and progression of oral squamous cell carcinoma and the over expression of survivin has been reported (24).

Early detection and treatment are extremely important for patient's prognosis. Therefore, it would be interesting to study these tumor cells behaviors. Our present study aims to investigate the expression of the anti-apoptotic gene such as c-myc, bcl-2 and survivin in different kinds of tumor which are diagnosed as actinic keratosis, basal cell carcinoma and squamous cells carcinoma arising in cutaneous and oral epithelium.

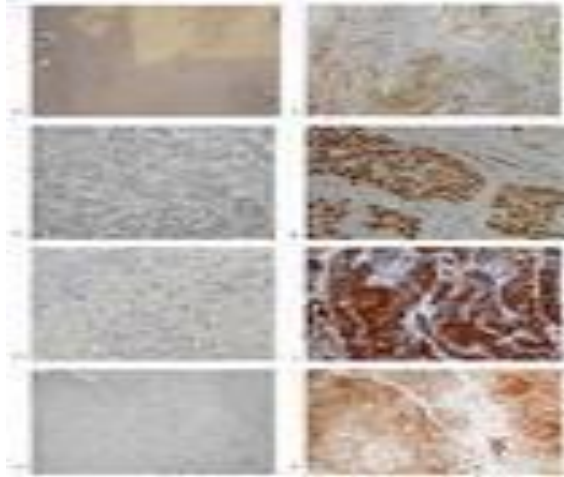
#### **Material and Methods**

In the present study, 5 cases of well-differentiated cutaneous squamous cell carcinoma (CSCC), 5 cases of basal cell carcinoma (BCC), 5 cases of actinic keratosis (AK) were obtained with approval of

Institutional Review Board, Department of Pathology, University of Alabama at Birmingham, USA and 5 cases of well-differentiated oral squamous cell carcinoma (OSCC) were obtained from the Department of Oral Pathology, Faculty of Dentistry, Chulalongkorn University, Thailand. The deparaffinized tissue sections were heated in the steamer in 10mM citrate buffer pH 6.0 for antigen retrieval (buffer was preheated for 15 minutes and then samples were heated in the buffer for 60 minutes). The tissue sections were then immersed in 3% hydrogen peroxide and Cyto-Q blocker (DAKO) for 10 minutes to block endogenous activity. Subsequently, the tissue sections were incubated with mouse anti-human c-myc monoclonal antibody (clone9E10; DAKO, USA), mouse anti-human bcl-2 monoclonal antibody (clone124; DAKO, USA), goat anti-human survivin polyclonal antibody (clone19; Santa Cruz, USA) diluted at 1:100 with antibody diluent (Biogenex) 4°C overnight. For the negative control, the tissue sections were incubated with mouse IgG1, k isotype (Clone400102; biolegend, USA) with the same dilution to the antibodies used. After rinsing and washing in tris buffer saline solution, the tissue sections were incubated with Enhancer (Innivex Bioscience) and secondary antibody conjugated to biotin (Biogenex), Streptavidin-ALK-label (Biogenex) for 1 hour at room temperature. Bound peroxidase was visualized by adding 3,3'-diaminobenzidine tetrahydrochloride (Innovex Bioscience, USA). Specimens were counter stained with Hematoxylin. The staining slides were evaluated using light microscope and photo taking under light microscope. All collecting data were analysed by classified the positive result into mild, moderately and strongly expression and positive cells located areas were concluded, descriptive analysis were performed.

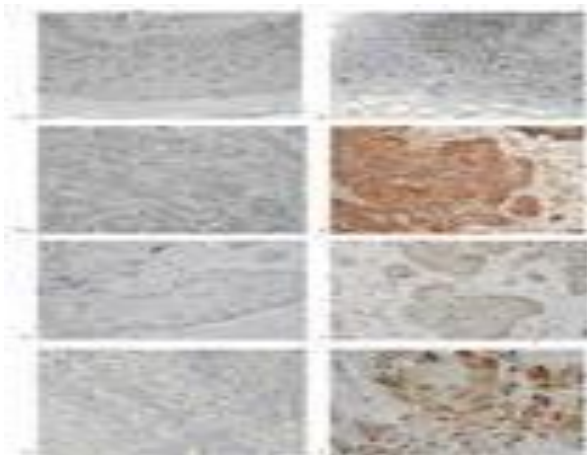
#### **Results**

From C-myc expressions in AK, mild to moderately protein expression (positive result) can be found in the basal cell areas of the epithelium. And positive stains are mostly found in the nucleus. C-myc expression in BCC, CSCC and OSCC, this protein expression is moderately to strongly expressed with the positive result can be found both in the the nucleus and cytoplasm of the tumor cells. Interestingly, in OSCC the staining is lot stronger than in other cancers with the positive cells in the stromal region (figure 1)



**Figure 1** Photomicrographs showing c-myc+ cells (arrows) in actinic keratosis (A) Basal cell carcinoma ( B), oral squamous cell carcinoma (C) and cutaneous squamous cell carcinoma (D) with negative control for each tumor (A1,B1,C1,D1) respectively. (Immunoperoxidase staining, counterstained with hematoxylin, original magnification 100x)

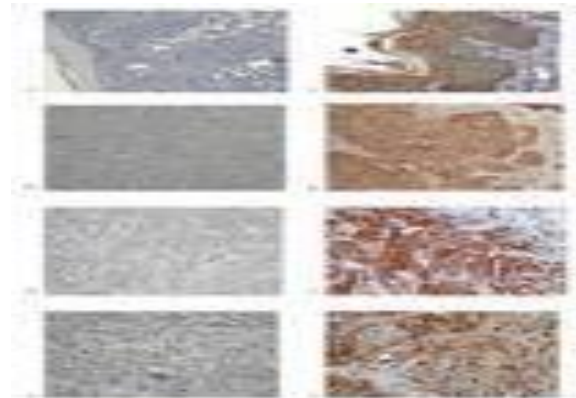
From the bcl-2 expressions in AK can be found in the nucleus mostly in the basal area of the epithelial cells and mild to moderately protein expression was noted. In BCC, CSCC and OSCC, bcl-2 staining can be found in the nucleus and cytoplasm of the tumor cells (figure 2) with moderate to strongly protein expression. Moreover, there are positive cells presented in the stromal cells of both CSCC and OSCC.



**Figure 2** Photomicrographs showing bcl-2 + cells (arrows) in actinic keratosis (A) Basal cell carcinoma (B), oral squamous cell carcinoma (C) and cutaneous squamous

cell carcinoma (D) with negative control for each tumor (A1,B1,C1,D1) respectively. (Immunoperoxidase staining, counterstained with hematoxylin, original magnification 100x)

The expression of bcl-2 in all samples are weaker than c-myc and survivin. With survivin expressions in AK, the positive result can be found mild to moderately protein expression in both the nucleus and cytoplasm of the epithelial cells especially in the basal areas. This protein also can be found in the nucleus and cytoplasm of the tumor cells in the other three cancers with moderately to strongly protein expression. In addition, the hair follicle are show positive result also in BCC (figure 3).



**Figure 3** Photomicrographs showing survivin+ cells (arrows) in actinic keratosis (A) Basal cell carcinoma ( B), oral squamous cell carcinoma (C) and cutaneous squamous cell carcinoma (D) with negative control for each tumor (A1,B1,C1,D1) respectively. (Immunoperoxidase staining, counterstained with hematoxylin, original magnification 100x)

**Discussion**

Our results reveal that c-myc expressions in all samples correspond well to the survivin expressions in terms of location and pattern of protein expression. However, OSCC specimen demonstrated stronger survivin expression than AK, BCC and CSCC. These findings may be caused by many factors. Some previous studies of c-myc expression reported sensitivity of this protein to disturbance. Other factors relate to the function of this protein such as the stages of the tumor or microenvironment within the tumor islands (25). And there are many studies showing the relationship between over expression of c-myc and the aggressiveness and metastasis of the squamous cell carcinoma (11,26,27). Our selected OSCC specimens were from tongue and floor of the

mouth, which show high risk of recurrence and poor prognosis of this cancer (28,29), but we failed to retrieve their grading or staging. Moreover, our current study reveals that c-myc expression is stronger in oral squamous cell carcinoma specimens than those from skin. This could be explained by several uncontrollable factors that could potentially affect the protein expression. These factors include location of the lesion, age of the patients and the difference between primary and recurrent lesion (1,28-30). How c-myc expression correlates with 5-year survival of these diseases is still unclear because the current study is a preliminary observational study. Future studies which include more sample size and information on grading and staging of the diseases will be of value. The expression of bcl-2 in all samples is weaker than c-myc and survivin. In the OSCC and CSCC, those positive for bcl-2 seem to be present mainly in the cytoplasm of the tumor cells. From the expression of bcl-2, some reported that the most aggressive tumors may show decreased expression of this protein and there are correlation between the risk of malignant transformation of some pre-malignant lesion to squamous cell carcinoma by means of its anti-apoptotic activity (31,32). The prognosis of head and neck cancers and the lymphatic nodal involvement are also reported to correlated with the over expression of bcl-2 (22). Aberrant bcl-2 expression may play an important role in the tumor genesis of oral cancers by allowing cells to escape from apoptosis and enabling additional genetic alterations to accrue (33). We also found the expressions of c-myc and bcl-2 protein in the stromal cells of both cutaneous and oral squamous cell carcinoma. By the senses of this protein expression which reflected to the behaviors and aggressiveness of SCC compared with BCC and AK. This results may confirmed the behaviors of squamous cell carcinoma compared with basal cells carcinoma and actinic keratosis that squamous cell carcinoma is more aggressive and the recurrence rate is higher (1, 2, 6).

From our results, survivin expression which appears more intense in the CSCC and OSCC than in BCC and AK. Survivin is a recently described inhibitor of apoptosis and mitotic regulator which is selectively over-expressed in human tumors. Its expression rate is predictive of disease progression, early recurrences and resistance to therapy for oral squamous cell carcinoma. From the senses of this protein expression, the relationship between over expression of survivin and the severity and progression of the cancers was shown (33). Moreover, the increase in survivin expression in some tumors was referred to aggressiveness

behaviors and the recurrence of the tumors (34). Previous study revealed correlation between the increasing of survivin expression and the anti-apoptotic activities of this protein and the malignancy turning rates and late stage of cancers (35).

The expression of c-myc, bcl-2 and survivin in AK are weaker than those found in other malignant tumors. Although, background of AK is an intra-epidermal malignancy precursor form of cutaneous squamous cell carcinoma, which generally occurs in fair-skinned individuals with long-term sun exposure (36). There are some reports show the relationship between AK that closely to SCC than in BCC by means of AgNOR analysis and their clinicopathological aspects (36,37). Our results shown that actinic keratosis exhibits lower expression of all three proteins tested as compared to the three malignancies. This finding is consistent with previous studies and supports that actinic keratosis is not a malignant lesion although a potentially malignant disorder (5,7-9,38,39).

### **Conclusion**

From our present study, it can be concluded that c-myc, bcl-2 and survivin expressions are useful biomarkers for evaluating the tumor cells differentiation and apoptotic activities that relate to tumor aggressiveness and their transformation to the invasive lesions.

### **References**

1. Karagas MR. Occurrence of cutaneous basal cell and squamous cell malignancies among those with a prior history of skin cancer. The Skin Cancer Prevention Study Group. *J Invest Dermatol* 1994; 102:10S-3S.
2. Johnson TM, Rowe DE, Nelson BR, Swanson NA. Squamous cell carcinoma of the skin (excluding lip and oral mucosa). *J Am Acad Dermatol* 1992; 26:467-84.
3. Newman MD, Weinberg JM. Topical therapy in the treatment of actinic keratosis and basal cell carcinoma. *Cutis* 2007; 79:18-28.
4. Poniecka AW, Alexis JB. An immunohistochemical study of basal cell carcinoma and trichoepithelioma. *Am J Dermatopathol* 1999; 21:332-6.
5. Nelson MA, Einspahr JG, Alberts DS, Balfour CA, Wymer JA, Welch KL, et al. Analysis of the p53 gene in human precancerous actinic keratosis lesions and squamous cell cancers. *Cancer Lett* 1994; 85:23-9.



6. Salasche SJ. Epidemiology of actinic keratoses and squamous cell carcinoma. *J Am Acad Dermatol* 2000; 42:4-7.
7. Chou A, Dekker N, Jordan RC. Identification of novel fibroblast growth factor receptor 3 gene mutations in actinic cheilitis and squamous cell carcinoma of the lip. *Oral Surg Oral Med Oral Pathol Oral Radiol Endod* 2009; 107:535-41.
8. Fuchs A, Marmur E. The kinetics of skin cancer: progression of actinic keratosis to squamous cell carcinoma. *Dermatol Surg* 2007; 33:1099-101.
9. Roewert-Huber J, Stockfleth E, Kerl H. Pathology and pathobiology of actinic (solar) keratosis - an update. *Br J Dermatol* 2007;157:18-20.
10. Vora HH, Shah NG, Patel DD, Trivedi TI, Chikhlikar PR. Prognostic significance of biomarkers in squamous cell carcinoma of the tongue: multivariate analysis. *J Surg Oncol* 2003; 82:34-50.
11. Vora HH, Shah NG, Trivedi TI, Goswami JV, Shukla SN, Shah PM. Expression of C-Myc mRNA in squamous cell carcinoma of the tongue. *J Surg Oncol* 2007; 95:70-8.
12. Ying HY, Shen X, Ding RR. [Research progress in natural killer cell receptors]. *Sheng Li Ke Xue Jin Zhan* 2000; 31:25-9.
13. Spandidos DA, Lamothe A, Field JK. Multiple transcriptional activation of cellular oncogenes in human head and neck solid tumours. *Anticancer Res* 1985; 5:221-4.
14. Field JK. The role of oncogenes and tumour-suppressor genes in the aetiology of oral, head and neck squamous cell carcinoma. *J R Soc Med* 1995; 88:35-9.
15. Todd R, Donoff RB, Wong DT. The molecular biology of oral carcinogenesis: toward a tumor progression model. *J Oral Maxillofac Surg* 1997; 55:613-25
16. Saranath D, Panchal RG, Nair R, Mehta AR, Sanghavi V, Sumegi J, et al. Oncogene amplification in squamous cell carcinoma of the oral cavity. *Jpn J Cancer Res* 1989; 80:430-37.
17. Somers KD, Cartwright SL, Schechter GL. Amplification of the int-2 gene in human head and neck squamous cell carcinomas. *Oncogene* 1990; 5:915-20.
18. Merritt WD, Weissler MC, Turk BF, Gilmer TM. Oncogene amplification in squamous cell carcinoma of the head and neck. *Arch Otolaryngol Head Neck Surg* 1990; 116:1394-8.
19. Leonard JH, Kearsley JH, Chenevix-Trench G, Hayward NK. Analysis of gene amplification in head-and-neck squamous-cell carcinoma. *Int J Cancer* 1991; 48:511-5.
20. Kusenda J. Bcl-2 family proteins and leukemia. Minireview. *Neoplasma* 1998; 45:117-22.
21. Adams JM, Cory S. The Bcl-2 protein family: arbiters of cell survival. *Science* 1998; 281:1322-6.
22. Crowe DL, Sinha UK. p53 apoptotic response to DNA damage dependent on bcl2 but not bax in head and neck squamous cell carcinoma lines. *Head Neck* 2006; 28:15-23.
23. De Maria S, Pannone G, Bufo P, Santoro A, Serpico R, Metafora S, et al. Survivin gene-expression and splicing isoforms in oral squamous cell carcinoma. *J Cancer Res Clin Oncol* 2009; 135:107-16.
24. Lo Muzio L, Farina A, Rubini C, Pezzetti F, Stabellini G, Laino G, et al. Survivin as prognostic factor in squamous cell carcinoma of the oral cavity. *Cancer Lett* 2005; 225:27-33.
25. Levens D. How the c-myc promoter works and why it sometimes does not. *J Natl Cancer Inst Monogr* 2008; 41-3.
26. Gasparian NA, Pozharisskii KM, Zharinov GM, Vinokurov VL, Kuznetsova ME, Neklasova N. [Immunohistochemical study of the predictive value of oncoproteins p53, HER-2 and c-myc during radiotherapy for squamous cell carcinoma of the cervix]. *Vopr Onkol* 2007; 53:439-44.
27. Briasoulis E, Tsokos M, Fountzilias G, Bafaloukos D, Kosmidis P, Samantas E, et al. Bcl2 and p53 protein expression in metastatic carcinoma of unknown primary origin: biological and clinical implications. A Hellenic Co-operative Oncology Group study. *Anticancer Res* 1998; 18:1907-14.
28. An SY, Jung EJ, Lee M, Kwon TK, Sung MW, Jeon YK, et al. Factors related to regional recurrence in early stage squamous cell carcinoma of the oral tongue. *Clin Exp Otorhinolaryngol* 2008;1:166-70.
29. Han JM, Wu GH, Zeng ZY, Chen FJ, Chen WK, Li H, et al. [Postoperative recurrence-related factors of 125 patients with cT1-2N0 squamous cell carcinoma of the oral tongue]. *Ai Zheng* 2007; 26:661-5.

30. Mallet Y, Avalos N, Le Ridant AM, Gangloff P, Moriniere S, Rame JP, et al. Head and neck cancer in young people: a series of 52 SCCs of the oral tongue in patients aged 35 years or less. *Acta Otolaryngol* 2009; 129:1503-8.
31. Chen K, Hu Z, Wang LE, Sturgis EM, El-Naggar AK, Zhang W, et al. Single-nucleotide polymorphisms at the TP53-binding or responsive promoter regions of BAX and BCL2 genes and risk of squamous cell carcinoma of the head and neck. *Carcinogenesis* 2007 Sep; 28(9):2008-12.
32. Sun M, Qin Y. [Expression of survivin and its correlation with p53 and bcl-2 expression in laryngeal and hypopharyngeal cancer]. *Lin Chung Er Bi Yan Hou Tou Jing Wai Ke Za Zhi* 2008; 22:346-8, 51.
33. Teni T, Pawar S, Sanghvi V, Saranath D. Expression of bcl-2 and bax in chewing tobacco-induced oral cancers and oral lesions from India. *Pathol Oncol Res* 2002; 8:109-14.
34. Du J, Sun X, Tian C, Geng X, Su Y. [Expression of Survivin, Caspase-3 and p53 in surgical margin of laryngeal squamous cell carcinoma and their relationship]. *Lin Chung Er Bi Yan Hou Tou Jing Wai Ke Za Zhi* 2008; 22(3):117-8, 21.
35. Pannone G, Bufo P, Serpico R, Rubini C, Zamparese R, Corsi F, et al. Survivin phosphorylation and M-phase promoting factor in oral carcinogenesis. *Histol Histopathol* 2007; 22:1241-9.
36. Giuffre G, Barresi V, Catalano A, Cappiello A, Stagno d'Alcontres F, Tuccari G. Actinic keratosis associated with squamous and basal cell carcinomas: an evaluation of neoplastic progression by a standardized AgNOR analysis. *Eur J Histochem* 2008; 52:53-60.
37. Lopez-Tizon E, Mencia-Gutierrez E, Garrido-Ruiz M, Gutierrez-Diaz E, Lopez-Rios F. Clinicopathological study of 21 cases of eyelid actinic keratosis. *Int Ophthalmol* 2009; 29:379-84.
38. Anwar J, Wrone DA, Kimyai-Asadi A, Alam M. The development of actinic keratosis into invasive squamous cell carcinoma: evidence and evolving classification schemes. *Clin Dermatol* 2004; 22:189-96.
39. Ackerman AB, Mones JM. Solar (actinic) keratosis is squamous cell carcinoma. *Br J Dermatol* 2006; 155:9-22.

