

Parental deceptive information: A case of traditional uvulectomy**Kawia H.M¹, Kahabuka F.K¹, Mbawala H.S.¹**¹ Department of Orthodontics Paedodontics Preventive & Community Dentistry, School of Dentistry, Muhimbili University of Health and Allied Sciences (MUHAS)Kawia H.M., Kahabuka F.K., Mbawala H.S. Parental deceptive information: A case of traditional uvulectomy. *Tanz Dent J* 2014; 18(2):76-80**Running Title:** A case of traditional uvulectomy**Abstract**

Traditional uvulectomy (TU) is a partial or radical removal of the uvula by traditional practitioners. Therapeutic uvulectomy is performed as a remedy for various ailments usually; persistent cough, sore throat, dry throat, vomiting, diarrhea, anorexia, rejection of breast by a child and growth retardation. In Tanzania, TU is done secretly as it is an illegal practice thus often parents do not reveal information of the procedure when complications occur and drive them to seek dental or other medical consultations. A case of deceptive information after traditional uvulectomy is presented.

Key words: Traditional practices, uvulectomy, traditional uvulectomy**Correspondence:** Prof. Kahabuka FK, School of Dentistry, P.O. Box 65014, Dar es Salaam, Tanzania. Email: kokukahabuka@yahoo.com**Introduction**

Uvula is a bell-shaped tissue hanging down in the middle at the back of the throat, it is an appendage of the soft palate formed by the fusion of the two halves of the soft palate. Uvula is an important structure in creating a tight seal in the pharynx during speech and feeding. Figure 1 below shows the normal anatomy of the oropharyngeal region displaying the Uvula.

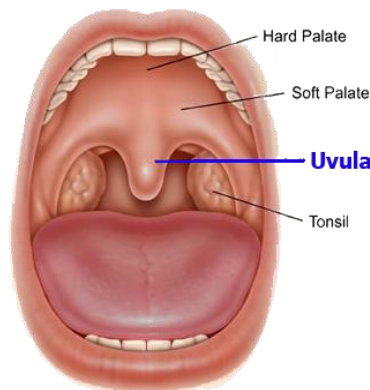


Fig 1: Anatomy of oropharyngeal region showing the uvula (adapted from <http://www.circumstitions.com/uvulectomy.html>)

The uvula has some glandular tissue indicating that it can produce saliva which moistens the throat. Recently the role of the uvula in the moistening of the oropharyngeal mucosa was described as evidenced by the experience of dryness of the throat following Uvulo-palato-pharyngoplasty (UPPP), a surgical procedure done to remove both the tonsils and uvula, (1).

By definition, uvulectomy is a surgical excision of the uvula also called staphylectomy (2). In some parts of the world, uvulectomy is done as part of a combined procedure, uvulopalatopharyngoplasty, to ameliorate conditions like snoring, suffocation and obstructive sleep apnoea which may be secondary to conditions such as Hereditary Angio-neurotic Oedema (HANE) and the like (3). In a study by Conway et al. (4) it was reported that removal of redundant tissue in the oropharynx (UPPP) significantly improved excessive daytime sleepiness, reduced by half the frequency of apneas and hypoxia occurring during sleep, and improved the quality of sleep. Among patients classified as responders, the frequency of apnea was reduced to a level seen in healthy adults of the same age, measures of sleep approached normal, and excessive daytime sleepiness was eliminated. In non-responders, frequency of apnea and consequent disruption of sleep was not reduced, but nocturnal hypoxia was improved.

On the other hand, traditional uvulectomy (TU) is a partial or radical removal of the uvula by traditional practitioners. It has been traced back to Hippocrates (460-355), Galen (129-200), 11th century in Spain, and 19th century in England and France, (5). TU is practiced as a preventive, therapeutic or ritualistic surgical procedure in various African (6-9) and the Middle East countries (10-13). Ritual uvulectomy is performed routinely, usually at birth, often as part of a birth or naming ceremony, whereas, therapeutic uvulectomy is performed as a remedy for various ailments (5). Commonly reported conditions which are regarded

by communities as indications for traditional uvulectomy include; persistent cough, sore throat, dry throat, vomiting, diarrhea, anorexia, rejection of breast by a child and growth retardation. Others include fever, globus pharyngeus, stuttering and suffocation during sleep in the neonatal period (9, 12, 14-17). It is reported that TU is performed among children from one to five years old, majority (68%) at two years (16).

The lay Community believe that an elongated uvula has some association or causes upper respiratory tract problems, mainly persistent cough (18). They believe that traditional uvulectomy is the treatment of choice for these children ailments. Consequently they send their children to the traditional healers for traditional uvulectomy either as a preventive measures or treatment.

Pai et al (18) reported that an elongated uvula can flop down and touch various structures in the upper airway including the posterior pharyngeal wall, epiglottis, and vocal cords and that mechanical irritation of these structures can lead to chronic cough

Traditional uvulectomy is an unnecessary and a potentially dangerous mutilation like traditional male circumcision and female genital cutting (7, 19). It is usually performed without anaesthesia and under non-sterile conditions (15). The procedure is performed by traditional healers, elderly laymen and barbers using either a pair of scissors, sickle shaped knife, a reed fork, twisted strands of horsehair, and/ or a hot knife (12, 17). Conversely, Kunii et al (20) in a study among Congolese refugees in Western Tanzania camps concluded that, only a limited number of the traditional healers self reported to believe that uvulectomy is beneficial for infants and young children.

Reported complications following traditional uvulectomy are hemorrhage, rejecting foods and failure to gain weight (9), anaemia (12, 21), Tetanus (21, 22), Cavemous Sinus Thrombosis (19), septicemia, cellulitis of the neck, pneumothorax, peritonsillar/parapharyngeal/neck abscess and pharyngo-laryngocele (23). Other accounted complications are; unusual hematemesis and melena (12), HIV infection (15), nasal regurgitation of meals and even death (24) have also been reported. Complications reported to occur later in life are; palatal insufficiency due to fibrotic scar formation of the soft palate, obstructive sleep apnoea and snoring (13, 25).

Earlier, Manni (6) reported that the Department of Otorhinolaryngology of the Muhimbili Medical

Centre, University of Dar es Salaam, was regularly treating patients who suffered complications arising from traditional uvulectomy. Three decades later, incidences of complications following TU are seen as one of the major causes for medical emergencies at Muhimbili National Hospital (personal communication) and once in a while children whose uvula has been excised by traditional healers are brought to the Muhimbili University of Health and Allied Sciences (MUHAS) dental clinic for management of complications.

A Case Report

A three years old boy, who is the second born among three children living with his both parents at Wazo Hill, Kinondoni District, Dar es salaam was attended at MUHAS dental clinic on 30th October 2013. He was brought by his father who was apprehensive due to the condition. Chief complaints were difficulties and pain during swallowing food, fluid regurgitated through the nose, and nasal speech following a traumatized uvula while playing for the previous four days. The father reported that the child was fine before the event although he acknowledged a history of frequent cough, flu and runny nose. On the day of injury, the boy and his sister were playing with a sharp ribbon-like piece of metal sheet (*Jalo*). The boy put the piece of the metal into his mouth which incidentally got stuck. Upon being notified, the father immediately forcefully removed the piece of the metal out of the child's mouth which resulted into bleeding from the mouth and through the nose. They consulted a near-by private health facility but no treatment was given because the problem was beyond the scope of the facility. Instead, they were advised to attend at a larger public health facility. Two days later, the child experienced difficulties and pain during swallowing, observed fluid being regurgitated through the nose as well as nasal speech. Therefore, they decided to take the child to Mwananyamala Regional Referral hospital where antibiotics (Amoxicillin syrup) and analgesics (Paracetamol tablets) were prescribed and the child was referred to Muhimbili for further investigations and expertise management.

On extra-oral examination the child had a heavy running nose. Intra-orally, the child had a poor oral hygiene, all deciduous teeth were present and sound. Examination of the oropharyngeal region revealed a small piece of uvula on the right side of the soft palate, a cut infected wound (Fig 2) and swollen left tonsil with pus pockets. There were no ulcers on the tongue, cheek or any other part of the oral cavity which could have occurred by a forceful removal of the piece of metal reported to have caused the injury.

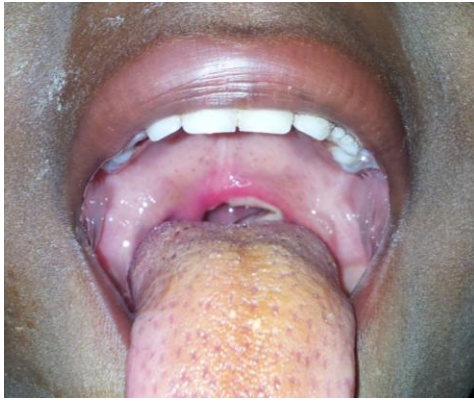

Figure 2: A photograph of the oropharyngeal region of a three years old boy showing a cut uvula, inflamed and infected areas

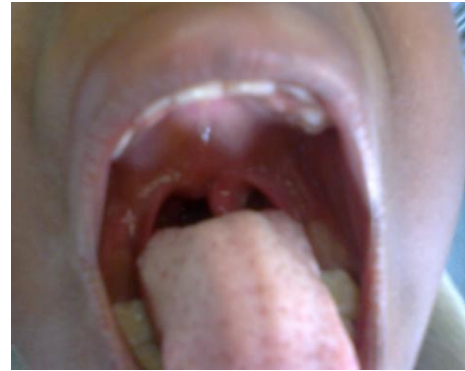

Figure 3: A photograph of a three years old boy showing a distorted and left shifted uvula following traditional uvulectomy.

The parent was calmed down and assured for a feasible good prognosis. Oral hygiene instructions and surgical toilet were done. Metronidazole syrup and Ibuprofen were added to the child's prescription. They were discharged and appointed to come back after four days for a follow up visit. About one week later (i.e. on 7th November 2013), the child was brought to the clinic, his general condition was fair. The inflammation, tonsillar swelling and food regurgitation had subsided, the wound was healing well, whereas, discomfort on swallowing and nasal speech had not improved. Professional tooth brushing was done and oral hygiene instructions were emphasized. Antibiotics were extended for three more days and the child was set on more follow-up visits.

Although the father totally denied taking the child for traditional uvulectomy, at one of the visits during the father's absence from the treatment room, the child informed the attending doctor that he was taken by his parents to a person nearby their home who cut something from his oral cavity after which he observed bleeding from his mouth.

At subsequent visits the father reported that, there were no more problems, the wound had healed, the child could swallow well, he had no more pain, there was no food regurgitation but there was some nasal speech noted during pronouncing some words. The child was discharged and appointed to come after three months for evaluation. At the last visit in March 2014, the child was fine, except that the uvula was distorted in shape and shifted to the left, (Figure 3).

Discussion

The parent, in the current case report did not confirm that his child underwent traditional uvulectomy. Nevertheless, the object reported by the father to have caused the injury is reasonably big to fit in the child's mouth and it is unlikely that forceful removal of the object from the child's mouth did not result into any other lesions/wounds in the oral cavity other than the uvula. In addition, according to the child's explanations, he was taken to a neighbour who cut something from his mouth. Besides, only the father, who is a night guard, escorted the boy to the clinic at all the six visits. This is not common among most contemporary societies in Africa, for the father to accompany the child below five years of age to hospital for several visits without the mother's company. On the grounds of these four explanations we confidently believe that this was a traditional uvulectomy practice. A similar situation was encountered by Al Rashed (12), at King Abdulaziz University Hospital (KAUH) in Riyadh, Saudi Arabia. A three-year-old girl was presented by her parents to the emergency room at KAUH with a chief complaint of hematemesis and passage of melena stools, a diagnosis of acute gastrointestinal bleeding was suggested. On the day of admission the child's hemoglobin level was 3.9 g/dl. She thus required repeated blood transfusion on three occasions. They decided to dig into the history and lately discovered that the father took the child to the traditional healer who performed TU otherwise rare causes of acute gastrointestinal bleeding would have been considered. Al Rashed (12), therefore stated that without good index of suspicion and good history taking the clinician can be deceived easily and rare causes of certain diseases conditions would be thought of. Traditional uvulectomy is still practiced in Tanzania. It is done secretly as it is an illegal practice hence parents hide their children when taking them to traditional practitioners. This is in contrast to reports from West African

countries where the practice is done accompanied by ceremonies of naming the newly born infants (19).

In the current case report, traditional uvulectomy was complicated by the post operative prolonged bleeding, pain, infection (peri-tonsillar pus pockets), difficulties in feeding and nasal regurgitation of foods and drinks and nasal speech. The patient being reported recovered after a ten days dose prescription of Amoxylline and Metronidazole. Complications similar to the findings in this case were previously reported in Tanzania (9, 21, 25), and elsewhere (7, 12, 24).

Conclusion & recommendations

From the current observation we conclude, that traditional uvulectomy is still secretly practiced in our society hence may contribute to increased morbidity among children. In view of the findings of this study we recommend that parents should be advised to seek medical attention from qualified medical personnel when their children have medical conditions instead of going to traditional healers to avoid unfortunate complications. We also recommend that the government should propagate laws against harmful traditional practices similar to the case of female genital mutilation and traditional circumcision.

References

1. Back, G. W., Nadig, S., Uppal, S., & Coatesworth, A. P. Why do we have a uvula?: literature review and a new theory. *Clinical Otolaryngology & Allied Sciences*. 2004; 29.6:689-93.
2. <http://medical-dictionary.thefreedictionary.com/uvulectomy>. The free Dictionary by Farlex(Accessed October 2014)
3. <http://www.circumstitions.com/uvulectomy.html>. Uvulectomy "If it sticks out, cut it off"? (Accessed October 2014)
4. Conway, W. A., Scklesteel, J. M., Wittig, R. M., Fujita, S., Zorick, F. J., Roehrs, T. A., & Roth, T. Evaluation of the effectiveness of uvulopalatopharyngoplasty. *The Laryngoscope*. 1985; 95:70-74.
5. Hunter, L. Uvulectomy-the making of a ritual. *SAMJ* 1995; 85.9.
6. Manni, J. J. Uvulectomy, a traditional surgical procedure in Tanzania. *Annals of tropical medicine and parasitology* 1984; 78:49-53.
7. Prual A, Gamatie Y, Djakounda M, Huguet D. Traditional uvulectomy in Niger: a public health problem? *Soc Sci Med*. 1994;39:1077-82
8. Einterz E.M., Einterz R.M., Bates M.E. Traditional uvulectomy in northern Cameroon. *Lancet* 1994;343:1644.
9. Machumu R.S., Fabian-Taylor F.M. Practice of uvulectomy and related complications among children aged below 6 years in Ilemela district, Mwanza, Tanzania. *Tanz Dent J* 2008; 15:10-4.
10. Nathan H, Hershkoritz I and Arensbury B, et al. Mutilation of the uvula among Bedouins of the South Sinai. *Isr J Med Sci* 1982;18:774-8.
11. Abdullah MA. Traditional practices and other socio-cultural factor affecting the health of children in Saudi Arabia. *Ann Trop Pediatr* 1993;13:227-32
12. Al Rashed, A. Unusual cause of hematemesis and melena. *Saudi journal of gastroenterology: official journal of the Saudi Gastroenterology Association* 4.3 1998: 179.
13. Ravesloot, M. J. L., and N. De Vries. "A good shepherd, but with obstructive sleep apnoea syndrome": traditional uvulectomy case series and literature review." *The Journal of Laryngology & Otology* 2011; 125:982-6. DOI: <http://dx.doi.org/10.1017/S0022215111001526>
14. Asefa M, Hewison J, Drewett D. Traditional nutritional and surgical practices and their effects on the growth of infants in south-west Ethiopia. *Paediatric and Perinatal Epidemiology* 1998; 12:182-98
15. Tshifularo M, Joseph CA, Ogunbanjo GA. Post-tonsillectomy haemorrhage following traditional uvulectomy in an adult patient. *SA Fam Pract* 2005;47:46
16. Mboneko K.V. Fabian F.M. Traditional uvulectomy and reported complications in under five children in Mkuranga district, Pwani region, Eastern Tanzania. *Tanz Dent J* 2006; 12:65-9.
17. Jacobson R., Ladizinski B., Lee K.C. Uvulectomies and associated complications. *JAMA Dermatol*. 2013; 149(1):32. doi:10.1001/jamadermatol.2013.1128.
18. Pai, V., Thomas H., and Stewart C. "Long uvula: an unusual cause of chronic cough." *Postgrad Med J* 2004;80.940:116-116. doi:10.1136/pmj.2003.011205.
19. Chukuezi A. Cavernous Sinus Thrombosis Complicating Traditional Uvulectomy: Case Report. *The Internet Journal of Head and Neck Surgery*. 2007; 2(2).
20. Kunii O., Tanaka Y., Lewis A., Wakai S.: Uvulectomy and other traditional healing practices: Traditional healers "perceptions and practices in a Congolese Refugee camp in Tanzania. [Http://dx.doi.org/10.2149/tmh.34.159](http://dx.doi.org/10.2149/tmh.34.159). *JST.JSTAGE/tmh.34.159* Accessed October 2014.
21. Wind J. Cross cultural and anthropological reflection on African uvulectomy. *Lancet* 1984;ii:1267-8
22. Eregie C.O. Uvulectomy as an epidemiological factor in neonatal tetanus mortality: Observations from a cluster survey.

- Department of Paediatrics, Specialist Hospital, Yola, Adamawa State, Nigeria. *West Afr J Med.* 1994;13:56-8.
23. Olu Ibekwe, A. Complications of the 'treatment' of tonsillar infection by traditional healers in Nigeria. *The Journal of Laryngology & Otology* 1983; 97.09: 845-849.
 24. Adoga A.A., Nimkur T.L. The Traditionally amputated uvula amongst Nigerians: Still an Ongoing Practice. *ISRN Otolaryngol.* 2011 Nov 22;2011: Article ID 704924, <http://dx.doi.org/10.5402/2011/704924>. Print 2011.
 25. Manni, J. J. "[Uvulectomy in Dar-es-Salaam (Tanzania)]." *Medizinische Welt* 1983; 34.19: 584-6.