

EFFECTS OF ETHANOLIC EXTRACT OF *ARISTOLOCHIA REPENS* ON BIOCHEMICAL AND HISTOLOGICAL CHANGES IN HIGH-FAT DIET AND STREPTOZOTOCIN-INDUCED RATS

*¹Omar S.A., ²Abubakar F.A. and ¹Onemola K.R.

¹Phytomedicine, Toxicology and Reproductive Biochemistry Research Laboratory, Department of Biochemistry, University of Ilorin, Nigeria

²Department of Science Laboratory Technology, Kogi State Polytechnic, Lokoja, Nigeria

*Corresponding Author Email Address: olaoye.sa@unilorin.edu.ng

Phone: +2348064434074

ABSTRACT

The study evaluated the lipid profile, electrolytes and histological changes in diabetic Wistar rats treated with stem bark extract of *Aristolochia repens*. Type 2 diabetes was induced in rats with high-fat diet and low dose of streptozotocin (35 mg/kg body weight). A total of thirty-five Wistar rats were fed with high-fat diet for eight (8) weeks, while five (5) Wistar rats (Sham control) were fed with low-fat diet. Non-induced male Wistar rats were treated with distilled water (Sham control); while the induced male Wistar rats were treated with distilled water, metformin (100 mg/kg), 50, 100 and 200 mg/kg ethanolic extract of *Aristolochia repens* stem bark for 28 days. The rats were sacrificed; liver, kidney and serum were collected and analyzed for serum glucose, lipid profile, electrolytes and histological changes. Treatment with ethanolic extract of *Aristolochia repens* stem bark significantly reduced the body weight, glucose level, total cholesterol concentration, triglycerides, low-density lipoprotein concentration and atherogenic indices. Mild pathological alterations were observed in the liver and kidney of diabetic rats at dosage above 50 mg/kg. However, the extract reduced the blood glucose, lipids and improve the selected electrolyte balance. This study suggests that ethanolic extract of stem bark of *A. repens* possesses antihyperglycaemia and antilipidaemic potential and might not be safe at dosage above 50 mg/kg.

Keywords: *Aristolochia repens*, Diabetes mellitus, Streptozotocin, High-fat diet.

INTRODUCTION

Diabetes mellitus is a chronic metabolic disease that is characterized by hyperglycaemia associated with alterations in carbohydrate, protein and fat metabolism, and is due to insulin deficiency or target organ insensitivity to insulin (Dilworth *et al.*, 2021). Persistently, high blood sugar (fasting blood glucose \geq 126 mg/dl, random plasma glucose \geq 200 mg/dl) puts a person at risk of both type 1 diabetes (T1D) and type 2 diabetes (T2D) (Hershey, 2017). Over time, diabetes can damage blood vessels in the kidneys, eyes, heart and nerves. Diabetes increases the risk of various diseases, such as heart attack, stroke and kidney failure. Damaged blood arteries in the eyes can lead to permanent loss of vision loss (WHO, 2023). Diabetes is a significant burden on health systems, with estimates from the International Diabetes Federation (IDF) suggesting that 537 million people worldwide had diabetes in 2021 (IDF, 2017; Sun *et al.*, 2022). Nigeria is one of the countries in sub-Saharan Africa (SSA) currently experiencing an increasing incidence of diabetes mellitus. A recent meta-analysis found that about 5.8% (about 6 million) of Nigerian adults are living with

diabetes. The rising prevalence of Type 2 Diabetes (T2D) among Nigerians is primarily attributed to increased obesity rates and decreased physical activities, resulting in insulin resistance (Uloko *et al.*, 2018). Dyslipidaemia encompasses alterations in High-Density Lipoprotein Cholesterol (HDL-C), Low-Density Lipoprotein Cholesterol (LDL-C) size and density, total cholesterol, and triglyceride levels. Abnormal lipid profiles are common in diabetes due to insulin resistance or deficiency impacting crucial lipid metabolism enzymes and pathways. Hyperglycaemia, obesity, and impaired insulin function significantly hasten atherosclerosis (Dixit *et al.*, 2014).

Electrolyte disorders are prevalent among diabetic patients, particularly in decompensated cases like diabetic ketoacidosis or non-ketotic hyperglycaemia hyperosmolar syndrome (Liamis *et al.*, 2013). Electrolytes, such as sodium, potassium, chloride, and bicarbonate, regulate fluid levels, pH balance, nerve conduction, blood clotting and muscle contraction. Imbalances due to kidney failure, dehydration, fever, or vomiting are implicated in diabetes and other endocrine complications (Husain *et al.*, 2009). Hyperglycaemia induces osmotic diuresis and dilutes electrolyte concentrations, contributing to electrolyte imbalances.

There are several classes of oral hypoglycaemic drugs that exert antidiabetic effects through different mechanisms, namely sulfonylureas (e.g. Glibenclamide), biguanides (e.g. Metformin), α -glucosidase inhibitors, thiazolidinediones (e.g. Lobeglitazone) and non-sulfonylureas secretagogues. However, some of these classes of drug have been reported to cause serious side effects such as liver problems, lactic acidosis, diarrhoea, toxicity, among others (Salehi *et al.*, 2019). Therefore, the search for more effective drugs with low cost and low side effects derived from plant source has continued to be a necessary area of research because of their ready availability, affordability and low adverse side effects (Salehi *et al.*, 2019).

Aristolochia repens, known as "Akogun" among the "Yoruba" people of Nigeria and as "Dumandutsee" in the northern party of Nigeria, is a perennial plant of the family Aristolochiaceae and a climbing shrub native to tropical America but is now grown in most West African countries (Bankole *et al.*, 2021). In many parts of the world, the plant is used in the management of several diseases. (Obode *et al.*, 2020). In Southwestern Nigeria, the root is used to cure diarrhoea and asthma (Afolayan *et al.*, 2020), while the stem is used to treat diabetes mellitus and its complications (Ariyo *et al.*, 2020). Based on phytochemical study, the primary bioactive ingredients in this plant are various forms of aristolochic acid. These include aristolochic acid I, aristolochic acid II, and

aristolochic acid IV (Okhale *et al.*, 2019). Although this plant has been reported to be used in the treatment of a number of illnesses, little is known about its hypoglycaemic properties or its ability to modulate certain biochemical changes associated with diabetes mellitus. Therefore, the objective of this study was aimed to evaluate effects of ethanolic extract of *A. repens* on biochemical and histological changes in high-fat diet and streptozotocin-induced male Wistar rats.

MATERIALS AND METHODS

Plant materials

Fresh stem bark of *Aristolochia repens* obtained at Oja Oba in Ilorin Nigeria was identified and authenticated at the Herbarium section, Department of Plant Biology, University of Ilorin, Ilorin, Nigeria.

Experimental animals

Forty-two healthy (150.50 ± 2.70 g each) of Male Wistar rats were obtained from the Animal Holding Unit of the Department of Biochemistry. The rats were housed in well ventilated cages and allowed to acclimatize to animal housing condition of temperature 28 – 31 °C, 12 hours of natural light and 12 hours darkness and humidity (50 – 55%) for fourteen (14) days. The rats were fed with rat pellets (Vita Feed produced by Grand Cereals from Vom, Jos, Nigeria) and allowed free access to water.

Assay kits and Reagents

Streptozotocin (STZ) was a product of Sigma-Aldrich, St Louis, Mo, USA. AccuChek Glucometer strips was a product of Nature's Choice™ Wholefood specialist, Meyerton, South Africa. Metformin was a product of Austell laboratories Pvt. Ltd., Johannesburg, South Africa. Total cholesterol, triglycerides and high density lipoprotein cholesterol, assay kits were product of Fortress Diagnostics Limited, Antrim Technology, United Kingdom. Potassium, sodium, chloride, bicarbonate assay kits used were products of Randox Laboratories Ltd., Antrim, UK. All other chemicals were of analytical grades.

Plant Preparation

Fresh lumps of stem bark of *Aristolochia repens* were collected, washed to remove all contaminants, air dried to a constant weight and then ground into fine powder using a mechanical grinding machine. The powdered form of the stem bark was pretreated and air dried, then it was stored in a cool dry container prior to analysis.

Ethanol Extract Preparation of *Aristolochia repens* Stem Bark

A known weight of five hundred grams (500 g) of the powdered stem bark of *Aristolochia repens* stems was percolated in 2000 ml of ethanol for 48 hours with continuous stirring at intervals. It was filtered using Whatman (no. 1) filter paper. The resulting filtrate was lyophilised with a Zirbus Lyophiliser, (Model VaCo 5-11, Zirbus Technology, Stephensonstraat, Germany) to obtain 15.90 g corresponding to a yield of 3.18%.

Proximate Analysis

Proximate analysis was carried out using the standard procedures of the Association of Official Analytical Chemists (AOAC) (1990).

Diet Constituents

Corn, soybeans and maize husk were purchased from Olufadi Market, Ilorin, Nigeria. Lard was obtained from a pig abattoir at

Obbo Road Ilorin, Kwara State. Salt was a product of Bayswater Industries Limited, Sango Ota, Ogun State, Nigeria. Saint Louis Sugar was a product of Sudzucker group, France. Soybean oil was a product of Sunola Foods Limited, Isolo, Lagos. Vitamin and mineral mix was a product of Wealth Agro Allied, Ibadan, Oyo State, Nigeria.

Diet Formulation

The maize seed was rinsed and drenched for 48 hours. It was then milled, dispensed into a cheese cloth to drain overnight and air dried. The soybean seeds were soaked for 6 hours to remove the coat of the seed. After dehulling, it was air-dried and milled. The lard was melted to remove dirt and allowed to cool at 35°C. The diet was compounded by adopting Bortolin *et al.* (2018) method with slight modifications (Table 1).

Induction of Type II diabetes

A total of thirty-five Wistar rats were fed with high-fat diet for eight (8) weeks, while five (5) Wistar rats (Sham control) were fed with low-fat diet. At the end of the eight weeks of administration of high-fat diet, the animals were feed-deprived overnight and each of the high-fat fed animals were injected intraperitoneally with a low dose STZ (35 mg/kg). After three days of STZ injection, the fasting blood glucose of the animals were checked using AccuChek active glucometer and compatibility strips by withdrawing blood from the caudal vein of each rat's tail. Rats showing glucose concentration above 200mg/dl were considered diabetic

Table 1: Diet constituents of the control and high-fat diets

Feed components	Control Diet (g/kg)	High fat diet
Corn Starch	546	246
Lard	-	300
Soy protein	200	200
Soybean oil	40	40
Sucrose	100	100
Corn husk	50	50
Methionine	4	4
Lysine	10	10
Vitamin mix	10	10
Mineral mix	40	40
Total	1000	1000

Experimental Design

Animal groupings and ethanolic extract treatment of *Aristolochia repens* stem barks were done as shown in Table 2. The experimental animals were treated for 4 weeks.

Table 2: Animal grouping and administration

Groups	Treatment
Sham Control	Sham control
High-fat Diet + STZ (Negative control)	High-fat diet + STZ
Metformin (Positive control)	High-fat diet + metformin (100 mg/kg)
HFD + 50 mg/kg ethanolic extract	High-fat diet +50 mg/kg body weight of ethanolic extract of <i>A. repens</i> stem bark
HFD + 100 mg/kg ethanolic extract	High-fat diet + 100 mg/kg body weight of ethanolic extract of <i>A. repens</i> stem bark
HFD + 200 mg/kg ethanolic extract	High-fat diet + 200 mg/kg body weight of ethanolic extract of <i>A. repens</i> stem bark

Preparation of Serum and Tissue Supernatant

The method described by Yakubu and Omar (2019) was used. Animals were sacrificed 24 hours after the last day of treatment and they were feed-deprived overnight. They were anaesthetized with diethyl ether and sacrificed by simply incising the jugular vein. Blood samples were collected into plain sample bottles for biochemical serum analysis then subjected to centrifugation using a centrifuge for 10 minutes to obtain the serum which was the supernatant. After the sacrifice, the rats were dissected in order to isolate the organs (liver and kidney). The isolated organs were weighed and immediately placed into a 0.25M of sucrose solution and stored in an ice cold condition. The organs of interest (liver and kidney) were then homogenized in ice-cold 0.25M sucrose solution. Each supernatants was transferred into a plain bottle and stored in the freezer until required for further analysis.

Determination of body weight and blood glucose

The body weight was determined using the method described by Poudyal *et al.* (2010); while the fasting blood glucose was determined by adopting Agwaya and Nandutu (2016) method.

Determination of Biochemical Parameters

The total cholesterol and triglycerides concentration was determined using the method described by Carr *et al.* (1993). High-density lipoprotein (HDL) concentration was determined by the method described by Gordon *et al.* (1977). The Friedewald *et al.* (1972) method was adopted for low-density lipoprotein (LDL) determination. Cardiac index was determined by the method expressed by Kang *et al.* (2004). Atherogenic and coronary artery indices were determined as expressed by Kayamori and Igarashi (1994). Potassium ion concentration was determined using the method described by Terri and Sesin (1958). Sodium ion concentration was determined using the method described by Mauma (1958). Chloride ion concentration was determined using the method described by Skeggs and Hohestrasser (1964).

Histological Examination

The organs of interest (liver and kidney) were dissected out and immediately fixed in 10% normal saline. Using standard tissue processor, the tissues were then dehydrated in ascending grades of alcohol: 70, 95% and absolute alcohol after which clearing was done with xylene/absolute alcohol (50:50 v/v). This was followed by infiltration in molten paraffin wax at 60°C. Sections taken at 0.4-0.6 μ thickness from each specimen were further processed for staining with Haematoxylin and Eosin (H & E) (Kiernan, 2015). Photomicrographs of the slides (x100) were used for histological examination. Test slides were compared with that of the control for any histoarchitectural variation.

Statistical Analysis

Data are mean triplicate determination \pm standard deviation (SD) values for proximate analysis. While other data are expressed as the mean of five replicates \pm standard error of mean (SEM). The results obtained were analyzed with IBM SPSS Statistics 20 using one-way ANOVA (Analysis of Variance) by Duncan's post HOC test for multiple comparisons. Values were considered statistically significant at $p \leq 0.05$

RESULTS

Proximate Analysis

Table 3 shows the proximate analysis of *A. repens* stem bark. Moisture, ash, crude protein, crude fibre, lipid content and carbohydrate content were observed to be present in the following percentages of: 13.69%, 3.92%, 3.28%, 40.09%, 8.77% and 30.92% respectively. The result shows that the content with the highest percentage is fibre while crude protein content was the least.

Table 3: Proximate analysis of ethanolic extract of *Aristolochia repens* stem bark

Proximate Analysis	Percentage (%)
Moisture content	13.69 \pm 0.01
Ash content	3.92 \pm 0.005
Crude protein	3.28 \pm 0.01
Crude fiber	40.09 \pm 0.005
Lipid content	8.77 \pm 0.005
Carbohydrate content	30.92 \pm 0.015

Data are mean triplicate determination \pm SD values

Body weight

Figure 1 shows the body weight of the experimental rats, which reveals increase in body weight after inducing rats with STZ and high-fat diet and significant reduction in weight after treatments with ethanolic extract of *A. repens* and metformin positive control. Treatment with 50, 100 and 200 mg/kg significantly reduced ($p < 0.05$) the body weight when compared with the negative control group. Treatment with 200 mg/kg of the ethanolic extract of *A. repens* compared favourably with the sham control and metformin positive control.

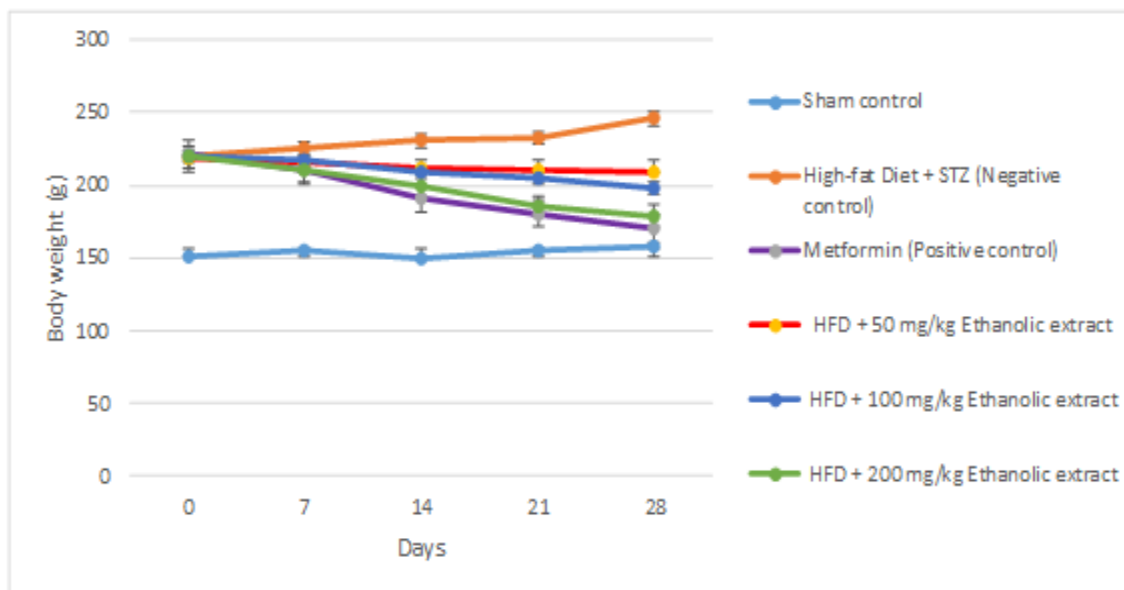


Figure 1: Body weight of streptozotocin and high-fat diet induced diabetic rats treated with ethanolic extracts of *A. repens* stem bark. Values are mean \pm SEM of seven determinations. HFD= High-fat diet

Fasting blood glucose

The fasting blood glucose (FBG) concentration of STZ and high-fat diet-induced diabetic rats with *A. repens* extract is shown in Figure 2. The FBG concentration of animals induced with high-fat diet and STZ (negative control) was significantly increased when compared

to the Sham control. Treatment with the ethanolic extracts of *A. repens* significantly reduced ($p < 0.05$) the FBG concentration when compared with the negative control. However, treatment with 200 mg/kg of ethanolic extract of *A. repens* stem bark compared favourably with the reference drug.

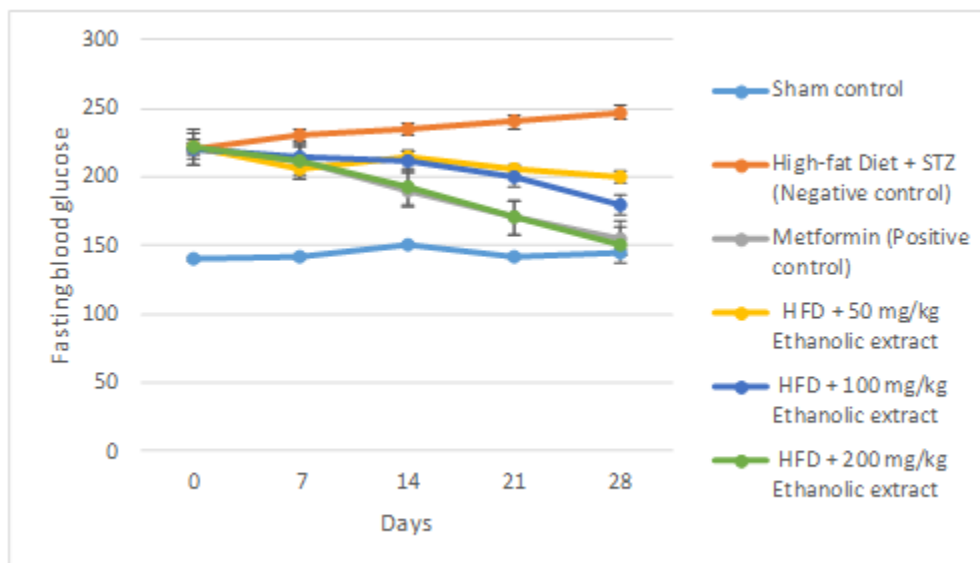


Figure 2: Fasting blood glucose concentration of streptozotocin and high-fat diet induced diabetic rats treated with ethanolic extracts of *A. repens* stem bark.

Values are mean \pm SEM of seven determinations, HFD = High-fat diet

Lipid Profile

The total cholesterol concentration of male Wistar rats treated with STZ and high-fat diet negative control was significantly ($p < 0.05$) increased when compared with the Sham control. Treatment at 50, 100 and 200 mg/kg of ethanolic extracts of *A. repens* stem bark

significantly ($p < 0.05$) reduced the concentration of total cholesterol when compared with negative control. Nevertheless, the treatment with 200 mg/kg of ethanolic extracts of *A. repens* stem bark did not significantly ($p > 0.05$) alter the concentration of total cholesterol when compared with the Sham and Metformin (positive control)

(Table 4). However, treatment at 200 mg/kg produced the most profound cholesterol reduction.

Compared with the Sham control, experimental animals treated with negative control had significant ($p < 0.05$) increase in the concentration of serum triglycerides. Treatment at 50, 100 and 200 mg/kg of ethanolic extracts of *A. repens* stem bark significantly ($p < 0.05$) reduced the triglycerides concentration when compared with negative control. Whereas treatment at 50, 100 and 200 mg/kg of ethanolic extracts of *A. repens* stem bark was not significantly ($p > 0.05$) altered when compared with sham control and metformin (positive control). However, treatment with 200 mg/kg body weight produced the most profound reduction in the concentration of triglycerides (Table 4).

The high-density lipoprotein-cholesterol concentration of male Wistar rats treated with negative control was significantly ($p < 0.05$) reduced compared with the Sham and Metformin (positive control). Treatment at 50, 100 and 200 mg/kg of ethanolic extracts of *A. repens* stem bark significantly ($p < 0.05$) increased the concentration of high-density lipoprotein-cholesterol concentration when compared with negative control. However, treatment at 200 mg/kg of ethanolic extracts of *A. repens* stem bark did not significantly ($p > 0.05$) altered the high-density lipoprotein-cholesterol concentration when compared with Sham and Metformin (positive control) (Table 4).

The low-density lipoprotein-cholesterol concentration of male Wistar rats treated with negative control was significantly ($p < 0.05$) increased when compared with the Sham and Metformin (positive

control). Treatment at 50, 100 and 200 mg/kg of ethanolic extracts of *A. repens* stem bark significantly ($p < 0.05$) reduced the concentration of low-density lipoprotein-cholesterol concentration when compared with negative control. However, the low-density lipoprotein-cholesterol concentration at 200 mg/kg compared favourably with Sham and Metformin (positive control) (Table 4).

Treatment with negative control significantly ($p < 0.05$) increased the cardiac index when compared with the Sham and Metformin (positive controls). Following treatment at 50, 100 and 200 mg/kg of ethanolic extracts of *A. repens* stem bark significantly ($p < 0.05$) reduced the cardiac index when compared with negative control. Also, the treatment with negative control, significantly increased the atherogenic index when compared with the Sham and Metformin (positive control). The atherogenic index of rats treated with 50, 100 and 200 mg/kg of ethanolic extracts of *A. repens* stem bark was significantly ($p < 0.05$) reduced when compared with the Sham and Metformin (positive control) (Table 5).

Following the treatment with negative control, the coronary artery index was significantly ($p < 0.05$) increased compared with the Sham and Metformin positive controls. The coronary artery index of rats treated at 50, 100 and 200 mg/kg body of ethanolic extracts of *A. repens* stem bark was significantly ($p < 0.05$) reduced when compared with negative control. The coronary artery index of male Wistar rats treated at 200 mg/kg of ethanolic extracts of *A. repens* stem bark compared favourably with the Sham and Metformin (positive controls) (Table 5).

Table 4: Lipid profile of streptozotocin and high-fat diet induced diabetic rats treated with ethanolic extracts of *A. Repens* stem bark

Groups/ Parameters	Total Cholesterol (mmol/l)	Triglycerides (mmol/l)	High-density lipoprotein cholesterol (mmol/l)	Low-density lipoprotein cholesterol (mmol/l)
Sham Control	20.59 ± 4.45 ^a	7.04 ± 4.04 ^a	17.62 ± 2.68 ^a	5.81 ± 2.14 ^a
High-fat Diet + STZ (Negative control)	80.50 ± 4.42 ^b	15.21 ± 13.42 ^b	5.40 ± 1.24 ^b	13.18 ± 4.25 ^b
Metformin (Positive control)	25.96 ± 3.41 ^c	7.93 ± 5.22 ^a	15.34 ± 3.89 ^a	6.75 ± 4.53 ^a
HFD + 50 mg/kg ethanolic extract	40.20 ± 1.50 ^a	9.01 ± 3.02 ^a	7.18 ± 2.89 ^b	10.29 ± 6.43 ^c
HFD + 100 mg/kg ethanolic extract	38.28 ± 2.19 ^a	7.64 ± 6.49 ^a	9.34 ± 4.48 ^c	7.81 ± 4.32 ^d
HFD + 200 mg/kg ethanolic extract	35.12 ± 5.41 ^a	6.44 ± 4.05 ^a	11.96 ± 1.06 ^a	6.28 ± 2.99 ^a

Values are mean ± SEM of seven determinations. Values with different superscripts across the row are significantly different ($p < 0.05$). HFD = High-fat diet

Table 5: Atherogenic, cardiac and coronary artery indices of STZ and high-fat diet induced diabetic rats treated with ethanolic extracts of *A. Repens* stem bark

Groups / Parameters	Cardiac index	Atherogenic Index	Coronary artery index
Sham Control	1.13± 0.05 ^a	1.01 ± 0.11 ^a	0.38± 0.03 ^a
High-fat Diet + STZ (Negative control)	16.04 ± 0.19 ^b	15.02 ± 2.26 ^b	2.75 ± 0.07 ^b
Metformin (Positive control)	1.66 ± 0.11 ^a	0.47 ± 0.04 ^c	0.44 ± 0.01 ^a
HFD + 50 mg/kg Ethanolic extract	4.71 ± 0.02 ^c	4.01 ± 0.18 ^d	0.71 ± 0.01 ^c
HFD + 100 mg/kg Ethanolic extract	4.22 ± 0.07 ^c	3.21 ± 0.11 ^d	0.78 ± 0.05 ^c
HFD + 200 mg/kg Ethanolic extract	3.18 ± 0.05 ^c	2.10 ± 0.07 ^e	0.37 ± 0.01 ^a

Values are mean ± SEM of seven determinations. Values with different superscripts across the row are significantly different (p<0.05). HFD = High-fat diet.

The chloride ion concentration was significantly increased in the negative control when compared with the Sham and Metformin (positive controls). Whereas, chloride ion concentration of the treatment groups (50, 100 and 200 mg/kg) of ethanolic extract of *A. Repens* was not significantly (p>0.05) altered when compared with Sham and Metformin (positive control) (Table 6).

The sodium and potassium ion concentration was significantly reduced in the negative control when compared with the Sham and Metformin (positive control). The treatment with the 50, 100 and 200 mg/kg of ethanolic extract of *A. Repens* significantly (p<0.05)

increased the concentration of Na⁺ and K⁺ when compared with the negative control (Table 6).

The bicarbonate ion concentration was significantly increased in the negative control when compared with the Sham and Metformin (positive control). Following the administration of 50, 100 and 200 mg/kg of ethanolic extract of *A. Repens*, the bicarbonate ion concentration significantly reduced when compared with the negative control. However, at 200 mg/kg dose the bicarbonate ion concentration was not significantly altered when compared with the Sham and positive control (Table 6).

Table 6: Changes in electrolyte concentration of STZ and high-fat diet induced diabetic rats following administration ethanolic extracts of *A. Repens* stem bark

Groups / Parameters	Cl ⁻ (mg/dl)	Na ⁺ (mg/dl)	K ⁺ (mg/dl)	HCO ₃ ⁻ (mg/dl)
Sham control	8.53 ± 1.75 ^a	19.84 ± 2.10 ^a	27.60 ± 2.05 ^a	15.85 ± 1.92 ^a
High-fat Diet + STZ (Negative control)	14.27 ± 1.83 ^b	11.60 ± 3.25 ^b	11.15 ± 1.84 ^b	35.30 ± 2.11 ^a
Metformin (Positive control)	10.73 ± 1.13 ^a	19.27 ± 2.51 ^a	21.73 ± 2.25 ^c	16.27 ± 2.95 ^a
HFD + 50 mg/kg ethanolic extract	9.30 ± 1.90 ^a	19.13 ± 1.78 ^a	21.54 ± 2.44 ^c	21.15 ± 2.14 ^c
HFD + 100 mg/kg ethanolic extract	9.18 ± 1.65 ^a	21.25 ± 1.69 ^a	20.58 ± 1.87 ^c	20.58 ± 1.85 ^c
HFD + 200 mg/kg ethanolic extract	8.75 ± 1.24 ^a	20.84 ± 2.40 ^a	22.69 ± 0.96 ^c	18.87 ± 1.17 ^a

Values are mean ± SEM of seven determinations. The values carrying superscript different from the control are significantly different (p < 0.05) with comparisons done down the column

Histology of Liver

The liver cross-section of Sham control (Plate 1) presented the hepatic tissue with preserved architecture composed of cords of normal hepatocytes, there is moderate periportal lymphocytic infiltration. No features of acute or chronic damage.

High-fat diet induced STZ (negative control): Plate 2 shows

choleostatic liver with typical hepatocyte density, staining intensity and cellular distribution. The hepatocytes appear to have halo spaces around them. This suggests mild pathological alteration. Metformin(positive control): Plate 3 shows typical presentation of liver histomorphology with no pathological alteration. Density and staining intensity appear normal with halo spaced central vein. ETH 50 mg/kg (50 mg/kg ethanolic extract of *A. repens*): Plate 4

shows choleostatic liver with typical hepatocyte density, staining intensity and cellular distribution. The hepatocytes appear to have halo spaces around them. This suggests mild pathological alteration

ETH 100 mg/kg (100 mg/kg ethanol extract of *A. repens*): Plate 5 shows choleostatic liver with typical hepatocyte density, staining intensity and cellular distribution. The hepatocytes appear to have halo spaces around them. This suggests mild pathological alteration.

ETH 200 mg/kg (100 mg/kg ethanol extract of *A. repens*): Plate 6 shows choleostatic liver with typical hepatocyte density, staining intensity and cellular distribution. The hepatocytes appear to have halo spaces around them. This suggests mild pathological alteration.

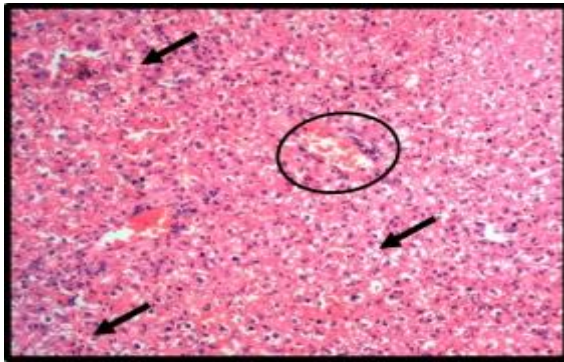


Plate 1: Cross-section of liver of male Wistar rat administered distilled water (Sham control) showing the central vein (black circle) and surrounding hepatocytes (black arrow). Hematoxylin eosin (H&E) stain at x100 magnification

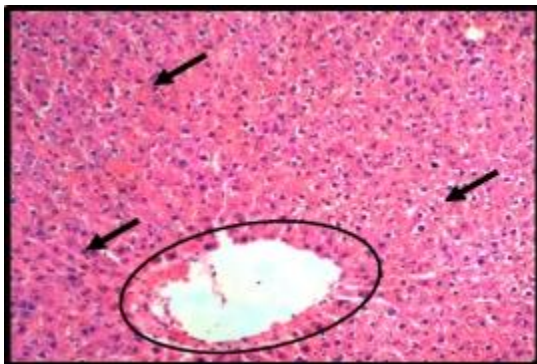


Plate 2: Cross-section of liver of male Wistar rat administered High-fat induced STZ (negative control) showing the central vein (black circle) and surrounding hepatocytes (black arrow). Hematoxylin eosin (H&E) stain at x100 magnification.

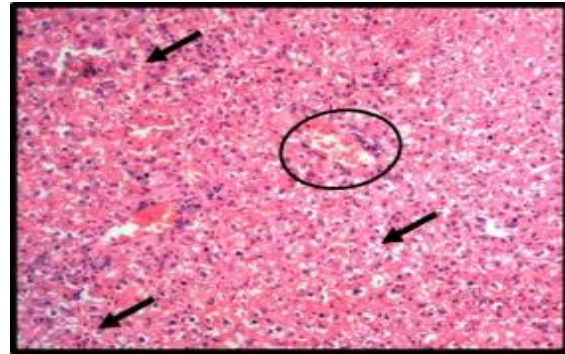


Plate 3: Cross-section of liver of male Wistar rat treated with Metformin (positive control) showing the central vein (black circle) and surrounding hepatocytes (black arrow). Hematoxylin eosin (H&E) stain at x100 magnification.

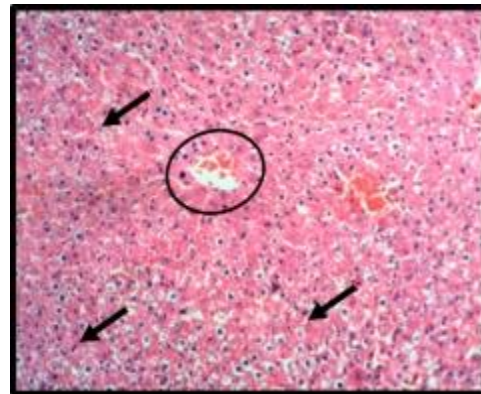


Plate 4: Cross-section of liver of male Wistar rat treated with 50 mg/kg of ethanolic extract of *A. repens* showing the central vein (black circle) and surrounding hepatocytes (black arrow). Hematoxylin eosin (H&E) stain at x100 magnification.

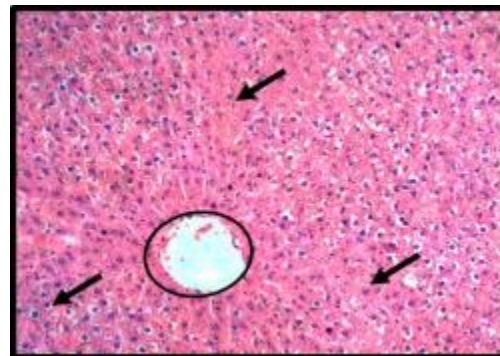


Plate 5: Cross-section of liver of male Wistar rat treated with 100 mg/kg of ethanolic extract of *A. repens* showing the central vein (black circle) and surrounding hepatocytes (black arrow). Hematoxylin eosin (H&E) stain at x100 magnification.

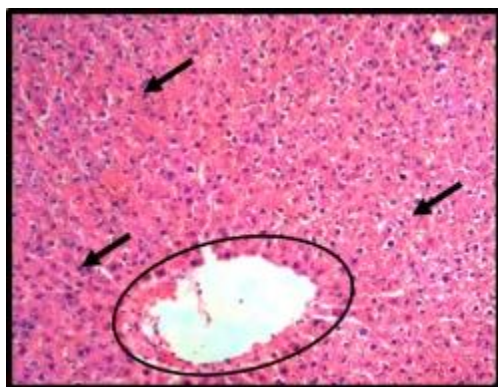


Plate 6: Cross-section of liver of male Wistar rat treated with 200 mg/kg of ethanolic extract of *A. repens* showing the central vein (black circle) and surrounding hepatocytes (black arrow). Hematoxylin eosin (H&E) stain at x100 magnification.

Histology of kidney

Representative cross-sections of the renal cortex showing the constituents intact renal corpuscles (yellow circles) with surrounding convoluted tubules (halo spaces). Degenerated or degenerating tubules presents as large halo spaced corpuscles or black spotted corpuscles (red circles). Hematoxylin and eosin stain at x100 magnification the photomicrographs show the panoramic structure of the renal corpuscle with its surrounding bowman space.

The kidney cross section of Sham control (Plate 7) shows a normal corpuscular histomorphology showing intact bowman's capsule and characteristically normal convoluted tubules. The histoarchitectural assortment of component part and staining intensity appear normal with no histopathological alterations.

High-fat diet induced STZ (negative control): Plate 8 shows corpuscular degeneration suggesting pathological alterations

Metformin (positive control): Plate 9 shows a normal corpuscular histomorphology showing intact Bowman's capsule and characteristically normal convoluted tubules. The histoarchitectural assortment of component part and staining intensity appear normal with no histopathological alterations

ETH 50 mg/kg (50 mg/kg ethanol extract of *A. repens*): Plate 10 shows a normal corpuscular histomorphology showing intact bowman's capsule and characteristically normal convoluted tubules. The histoarchitectural assortment of component part and staining intensity appear normal with no histopathological alterations

ETH 100 mg/kg (100 mg/kg ethanol extract of *A. repens*): Plate 11 shows a corpuscular degeneration suggesting pathological alterations.

ETH 200 mg/kg (200 mg/kg ethanol extract of *A. repens*): Plate 12 shows a corpuscular degeneration suggesting pathological alterations.

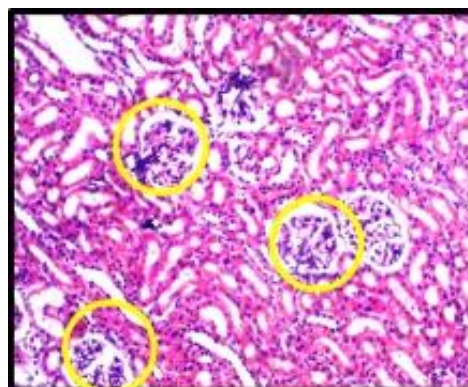


Plate 7: Cross-section of kidney of male Wistar rat administered distilled water. Hematoxylin eosin (H&E) stain at x100 magnification.

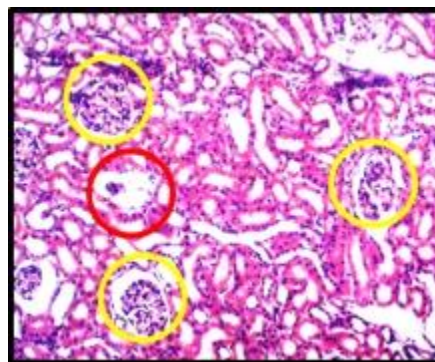


Plate 8: Cross-section of the kidney of high-fat diet and STZ induced group. Hematoxylin eosin (H&E) stain at x100 magnification.

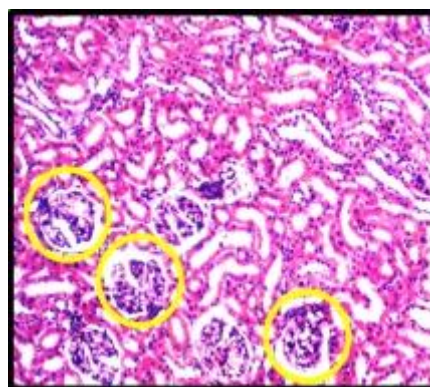


Plate 9: Cross section of kidney of male Wistar rat treated with Metformin (positive control) . Hematoxylin eosin (H&E) stain at x100 magnification.

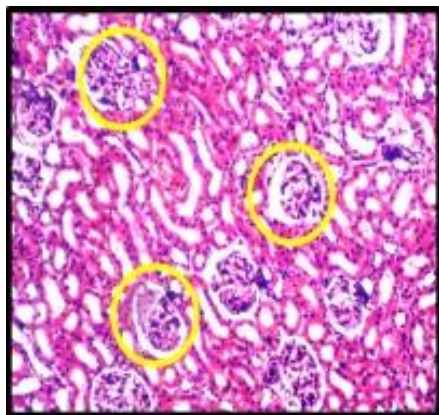


Plate 10: Cross-section of kidney of male Wistar rat treated with 50 mg/kg of ethanolic extract of *A. repens*. Hematoxylin eosin (H&E) stain at x100 magnification.

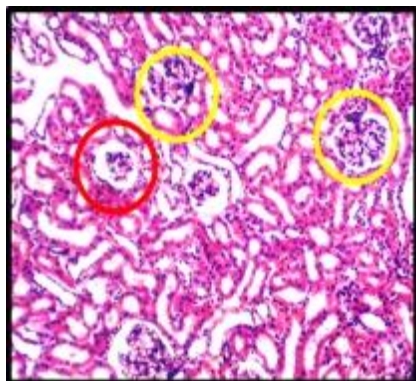


Plate 11: Cross-section of kidney male Wistar rat treated with 100 mg/kg of ethanolic extract of *A. repens*. Hematoxylin eosin (H&E) stain at x100 magnification.

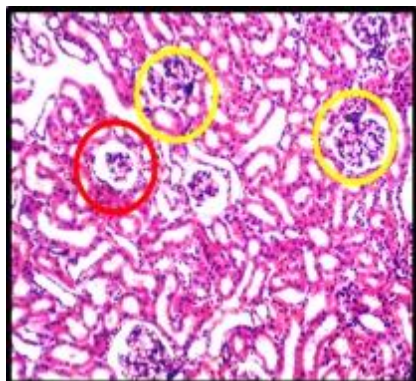


Plate 12: Cross-section of kidney of male Wistar rat treated with 200 mg/kg of ethanolic extract of *A. repens*. Hematoxylin eosin (H&E) stain at x100 magnification.

DISCUSSION

The proximate analysis result of *A. Repens* stem shows that moisture, ash, protein, fibre, lipid and carbohydrates contents (on dry weight basis) were observed to be present in the following percentage of: 13.69%, 3.92%, 3.28%, 40.09%, 8.77%, 30.92% respectively. Moisture content is a widely used parameter in the

processing and testing of food samples. It is an index of the water activity of many food and helps in maintaining protoplasmic content of the cell and content of the stem (Kumari *et al.*, 2022). The observed value implies that *A. repens* stem could live a long shelf life due to its low moisture content since microorganisms that causes spoilage mostly thrive in food having high moisture content. Dietary fibre is an important factor in diet as it is involved in many physiological functions such as the regulation of the peristalsis, prevention of constipation, regulation of glucose and blood lipid levels and etc. (He *et al.*, 2022). Fibre is the component of *A. repens* stem with the highest percentage content, the crude fibre in *A. repens* may prove useful as a good source of dietary fibre. Dietary fibre can function to reduce blood glucose levels as it speeds up digestion thereby reducing glucose absorption. Fibres are known to slow down glucose absorption and reduce insulin secretion which is of great importance to diabetic patients (He *et al.*, 2022). This high level of fibre in *A. repens* may be responsible for its anti-diabetic properties (Sonibare *et al.*, 2006). The low oil yield which is typical of a lot leafy vegetables may be beneficial to individual requiring low fats diets, this is an advantage because the plant would not add to fat consumption. Excess fat consumption is associated with cardiovascular disorders such as atherosclerosis and cancer (Sonibare *et al.*, 2006). Ash content, defined as the measure of inorganic matter in samples, which implies that the low ash content of *A. repens* stem bark, might suggest that the stem bark is a poor source of mineral. The crude protein content of 3.28% was found in *A. repens* stem. This percentage is low, as it implies that its protein content is low. The stem bark of *A. repens* is a poor source of lipid. This is an advantage because the stem will not add to fat consumption, as excess of fat consumption is implicated in cardiovascular disorders such as atherosclerosis and cancer (Sonibare *et al.*, 2006). The level of carbohydrate present in *A. repens* was 30.97%. This means that the carbohydrate level is high.

The rats placed on high-fat diet shows significant increase in body weight over the course of the 28 days, this result may be due to hyperglycaemia and accumulation of triglyceride in body tissue. (Mestry *et al.*, 2017). In the present study, it is observed that loss of body weight increases with increase in composition of *A. repens* extracts. This may be due to the antilipidemic activities of the stem extract which thus leads to decrease in body weight.

Streptozotocin is used as an agent to induce diabetes mellitus by selective cytotoxicity effect on pancreatic beta cells. Thus it affects endogenous insulin release and as a result increases blood glucose level (Rehman *et al.*, 2023). Therefore, the determination of concentration of glucose in the blood of diabetic laboratory animals induced with streptozotocin is a useful quantitative index of diabetes. On the other hand, the reference anti-diabetic agent, Metformin, is a commonly used drug which acts via several mechanisms and in the process increases insulin sensitivity of extra-pancreatic tissues and lowers blood glucose level (Rena *et al.*, 2017). The continuous administration of ethanol extract of *A. repens* at 50, 100 and 150mg/kg doses significantly reduced the blood glucose concentration in STZ induced diabetic rats. Therefore, the reduction in the blood glucose levels of STZ induced diabetic animals by the administration of *A. repens* suggests anti hyperglycaemia effect of the stem.

Alterations in the concentration of total cholesterol, triglyceride, HDL and LDL in the serum can give useful information on lipid

metabolism as well as predisposition of subjects to atherosclerosis disease (Linton *et al.*, 2019). High plasma cholesterol concentrations are important risk factor for cardiovascular diseases. An increase in 1% serum cholesterol concentration is reported to result in a 3% increase in atherosclerotic disease (Tauchen *et al.*, 2023). Therefore, the similarity in total cholesterol levels observed in the groups treated with extract of *A. repens* when compared with the positive control shows that the hypocholesterolemic condition may be attributed to its increased ability to excrete cholesterol. Triglyceride have clinical values in assessing atherosclerosis disease (Rasposeiras-Roubin *et al.*, 2021). The rats in the sham and positive control group had low triglyceride level. The group of rats treated with ethanol extract of *A. repens* showed low triglyceride values which suggests that administration of ethanol extract of *A. repens* stem bark reduced the hydrolysis of fats. This implies that ethanolic extract of *A. repens* stem bark mitigated the excessive buildup of fats. High density lipoprotein mediates the removal of cellular cholesterol and its secretion into bile in the liver (Ouimet *et al.*, 2019). High density lipoprotein value in the groups treated with ethanolic extract of *A. repens* was not significantly different in comparison to the positive control group. This indicates that *A. repens* ethanolic stem extract helps normalize the HDL concentration which helps increase excretion of cholesterol. As a risk indicator and the main goal of treatment for hyperlipidaemia, low-density lipoprotein cholesterol (LDL-C) has now mainly supplanted total cholesterol (Wadhera *et al.*, 2016). High levels of low-density lipoprotein cholesterol (LDL-C) are one of the main causes of atherosclerosis risk. Reducing LDL-C lowers the incidence of ischaemic stroke, myocardial infarction, and coronary artery disease (Zafir *et al.*, 2023). The LDL levels of *A. repens* extract administered group showed no significant increase when compared to the positive control group which suggests that ethanol extract of *A. repens* has the potential to lower LDL levels. Atherogenic index has been used as an indicator of atherosclerosis disease. The value for atherogenic index observed in the group treated with ethanol extract of 200mg suggests that extract of 200mg has highest anti-atherosclerotic potential compared to the positive control and other extracts, having the sharpest reduction or decrease in atherosclerotic index value.

Serum electrolytes including Na^+ , K^+ , Cl^- and HCO_3^- are often used to assess acid-base imbalance and monitor the effect of treatment on a known imbalance that is affecting body organ (kidney) function (Karuna, *et al.*, 2021). Chloride, being the primary extracellular anion, plays a critical role in regulating body fluids, a function that becomes particularly pertinent in diabetes. In diabetic conditions, increased urine output (polyuria) can occur, leading to fluid loss and subsequent disruptions in electrolyte balance. Chloride's involvement in maintaining fluid balance becomes crucial in counteracting these disruptions, as alterations in chloride levels can affect overall electrolyte equilibrium, influencing conditions related to dehydration or electrolyte imbalances often seen in diabetes (Billah *et al.*, 2018.). The observed lack of significant alteration in chloride ion concentrations following treatment with varying doses of the *A. Repens* extract presents intriguing implications. The absence of significant changes in chloride levels compared to the Sham and Metformin control groups suggests that the extract might not exert a substantial influence on chloride balance in the same manner as observed in the negative control group. This finding implies a potential distinct mechanism of action

or a lack of direct impact on chloride regulation by the *A. Repens* extract.

The decrease in sodium and potassium levels observed in the negative control group suggests an electrolyte imbalance, which can be particularly common in certain metabolic disorders or dysfunctions. The capability of *A. repens* extract to significantly elevate Na^+ and K^+ concentrations signifies a potential restorative effect on electrolyte balance. This suggests the extract's ability to restore or maintain these crucial electrolyte levels, which are fundamental for various physiological functions, including nerve transmission, muscle contraction, and osmotic balance (Soetan *et al.*, 2010)

Bicarbonate ions play a critical role in maintaining the body's acid-base equilibrium. In diabetes, disturbances in acid-base balance can occur, particularly in conditions like diabetic ketoacidosis (DKA), where increased ketone production leads to acidosis (Gosmanov *et al.*, 2021). The reduction in bicarbonate ion concentration by the *A. Repens* extract suggests its potential influence on regulating pH balance, possibly impacting the body's ability to counteract acidity. The extract's ability to lower bicarbonate ion concentrations, especially at lower doses, may have implications for therapeutic interventions targeting acid-base disturbances.

The histological architecture of the kidney showed corpuscular histomorphology showing intact bowman capsule and characteristically convoluted tubules (Murray and Paolini, 2023). The histological architecture of the kidney in the 50 mg/kg *A. repens* ethanol extract administered group showed normal corpuscular histomorphology showing intact bowman capsule and characteristically normal convoluted tubules, the histoarchitectural assortment of component appears normal with no histopathological alterations. However, 100 mg/kg ethanol extract showed presence of corpuscular degeneration suggesting pathological alterations which leads to the conclusion that although at a higher dose of 100 mg/kg ethanolic extract of *A. repens* have an effect on the liver, it may also lead to renal dysfunction.

Conclusion

In conclusion, ethanolic extract of *A. repens* stem bark was effective in the management of diabetes mellitus with the dose at 200 mg/kg body weight and might have acted via regeneration of the pancreas, enhancement of glucose utilization and reduction of blood glucose as well as reduced fats accumulation. From the data obtained in the present study, it has also shown that administration of the extract above 50mg/kg might cause liver and kidney histopathological alterations. Further biochemical investigation to elucidate the mechanism of antidiabetic and antilipidemic effect of this plant at lower dosage will be needed to justify its ethno-medicinal usage.

REFERENCES

- Afolayan, F.I., Sulaiman, K.A. & Okunade, W.T. (2020). Ethnobotanical survey of plants used in cancer therapy in Iwo and Ibadan, South-Western of Nigeria. *Journal of Pharmacology and Pharmaceutical Research*, 8(5), 346-367.
- Agwaya, M.S. & Nandutu, A.M. (2016). Hypoglycemic activity of aqueous root bark extract *Zanthoxylum chalybeum* in alloxan-induced diabetic rats. *Journal of Diabetes Research*, 2016 (Article ID 8727590).

- AOAC (1990). Official Method of Analysis Association of Official Analytical Chemists. 15th Edition, AOAC International Publisher, Washington DC.
- Ariyo, O., Usman, M., Emeghara, U., Olorukooba, M.M., Fadele, O.K., Danbaki, C.A., Olagunju, O.E., Suleiman, R. & Ariyo, M.O. (2020). Indigenous Curative Plants used in the Treatment of Piles from Akinyele Local Government Area, Ibadan, Oyo State, Nigeria. *Annual Research Review in Biology*, 13, 78-89.
- Bankole, H.A., Kazeem, M.I., Maliki, M.A., Oladokun, T.I., & Fatai, A.A. (2021). Ethanol Extract of *Aristolochia repens* Mill. Stem Inhibits the Activities of some Enzymes Targeted in the Treatment of Diabetes Mellitus. *Tropical Journal of Natural Product Research*, 5(1), 194–198.
- Billah, M.M., Rana, S.M., Akter, N., & Hossain, M.S. (2018). Analysis of serum electrolyte and lipid profile in young Bangladeshi female with Type II Diabetes. *Cogent Biology*, 4(1), p.1431474.
- Bortolin, R.C., Vargas, A.R., Gasparotto, J., Chaves, P.R., Schnorr, C.E., Martinello, K.B. & Moreira, J.C. F. (2018). A new animal diet based on human Western diet is a robust diet-induced obesity model: comparison to high-fat and cafeteria diets in term of metabolic and gut microbiota disruption. *International Journal of Obesity*, 42(3), 525-534.
- Carr, T.P., Andresen, C.J., & Rudel, L.L. (1993). Enzymatic determination of triglyceride, free cholesterol, and total cholesterol in tissue lipid extracts. *Clinical Biochemistry*, 26(1), 39-42.
- Dilworth, L., Facey, A., & Omoruyi, F. (2021). Diabetes Mellitus and its Metabolic Complications: The Role of Adipose Tissues. *International Journal of Molecular Sciences*, 22(14), 7644.
- Dixit, A.K., Dey, R., Suresh, A., Chaudhuri, S., Panda, A.K., Mitra, A., & Hazra, J. (2014). The prevalence of dyslipidemia in patients with diabetes mellitus of ayurveda Hospital. *Journal of Diabetes & Metabolic Disorders*, 13, 1-6.
- Friedewald, W., Levy, R. & Frederickson, D. (1972). Estimation of the concentration of low density lipoprotein cholesterol in plasma, without the use of preparative ultracentrifuge. *Clinical Chemistry*, 15, 920-924.
- Gordon, T., Castelli, W.P., Hjortland, M.C., Kannel, W. Bm, Dawber, T.R. (1977). High density lipoprotein as a protective factor against coronary heart disease. The Framingham Study. *American Journal of Medicine*, 62(5), 707-714.
- Gosmanov, A.R., Gosmanova, E.O., & Kitabchi, A.E. (2021). Hyperglycemic crises: diabetic ketoacidosis and hyperglycaemia hyperosmolar state. *Endotext [Internet]*.
- Hershey, D. S. (2017). Diabetic peripheral neuropathy: evaluation and management. *Journal of Nurse Practitioners*, 13, 199–204.
- He, Y., Wang, B., Wen, L., Wang, F., Yu, H., Chen, D., Su, X., & Zhang, C. (2022). Effects of dietary fiber on human health. *Food Science and Human Wellness*, 11(1), 1-10.
- IDF. International Diabetes Federation. (2017). IDF Diabetes Atlas. 8th ed.
- Hussain, F., Maan, M.A., Sheikh, M.A., Nawaz, H., & Jamil, A. (2009). Trace elements status in type 2 diabetes. *Bangladesh journal of medical science*, 8(3), 52.
- Kang, M.J., Lee, E.K., Lee, S.S. (2004). Effects of two P/S ratios with same peroxidizability index value and antioxidants supplementation on serum lipid concentration and hepatic enzyme activities of rats. *Clinica Chimica Acta* 350, 79–87.
- Kayamori, F., & Igarashi, K. (1994). Effects of dietary nasunin on the serum cholesterol level in rats. *Bioscience, Biotechnology, and Biochemistry*, 58(3), 570-571.
- Kiernan, J.A. (2015). *Histological and Histochemical Methods: Theory and Practice*. 5th edition, Scion Publishing, 571.
- Kumari, V.V., Banerjee, P., Verma, V., Sukumaran, S., Chandran, M.S., Gopinath, K., Venkatesh, G., Yadav, S. K., Singh, V., & Awasthi, N.K. (2022). Plant nutrition: An effective way to alleviate abiotic stress in agricultural crops. *International Journal of Molecular Sciences*, 23(15), 8519.
- Linton, M.F., Yancey, P.G. & Davies, S.S. (2019). The Role of Lipids and Lipoproteins in Atherosclerosis. *Endotext*. <https://www.ncbi.nlm.nih.gov/books/NBK343489/>
- Maruna, R. (1958). Colorimetric determination of sodium in human serum and plasma. *Clinical Chemistry*, 2,581.
- Mestry, S.N., Dhodi, J.B., Kumbhar, S.B., & Juvekar, A.R. (2017). Attenuation of diabetic nephropathy in streptozotocin-induced diabetic rats by *Punica granatum* Linn. Leaves extract. *Journal of Traditional and Complementary Medicine*, 7(3), 273–280.
- Murray, I.V., & Paolini, M.A. (2023). Histology, Kidney and Glomerulus. In: StatPearls [Internet]. <https://www.ncbi.nlm.nih.gov/books/NBK554544/>
- Obode, O.C., Adebayo, A.H., Omonhinmin, C.A., & Yakubu, O.F (2020). A systematic review of medicinal plants used in Nigeria for hypertension management. *International Journal of Medicinal Plant Research*, 12(4).
- Okhale, S., Egharevba, H., Okpara, O., Ugbabe, G.E., Ibrahim, J.A., Fatokum, O.T., Sulyman, A.O., & Igoli, J.O. (2019). Aristolochic acids in herbal medicine: Public health concerns for consumption and poor regulation of botanical products in Nigeria and West Africa. *Journal of Medicinal Plants Research*, 13(3), 55-65.
- Ouimet, M., Barrett, T.J., & Fisher, E.A. (2019). HDL and Reverse Cholesterol Transport. *Circulation Research*, 124(10), 1505–1518.
- Poudyal, H., Campbell, F., Brown, L. (2010). Olive leaf extract attenuates cardiac, hepatic, and metabolic changes in high carbohydrate-, high fat-fed rats. *Journal of Nutrition*, 140, 946–953.
- Raposeiras-Roubin, S., Rosselló, X., Oliva, B., Fernández-Friera, L., Mendiguren, J.M., Andrés, V., Bueno, H., Sanz, J., De Vega, V.M., & Fuster, V. (2021). Triglycerides and residual atherosclerotic risk. *Journal of the American College of Cardiology*, 77(24), 3031–3041.
- Rehman, H.U., Ullah, K., Rasool, A., Manzoor, R., Yuan, Y., Tareen, A.M., Kaleem, I., Riaz, N., Hameed, S.A., & Bashir, S. (2023). Comparative impact of streptozotocin on altering normal glucose homeostasis in diabetic rats compared to normoglycemic rats. *Scientific Reports*, 13(1).
- Rena, G., Hardie, D.G., & Pearson, E.R. (2017). The mechanisms of action of metformin. *Diabetologia*, 60(9), 1577–1585.
- Salehi, B., Ata, A., Sharopov, F., Ramirez-Alarcón, K., Ruiz-Ortega, A.M., Ayatollahi, S.A., Fokou, P.V.T., Kobarfard, F., Zakaria, Z.A., Iriti, M., Sharifi-Rad, J. (2019). Antidiabetic potential of medicinal plants and their active components. *Biomolecules*, 9(10), 551.
- Skeggs, L. & Hochstrasser, H. (1964). Colorimetric method of chloride estimation. *Clinical Chemistry*, 10,918-920.

- Soetan, K.O., Olaiya, C.O., & Oyewole, O.E. (2010). The importance of mineral elements for humans, domestic animals and plants: A review. *African journal of food science*, 4(5), 200-222.
- Sonibare, M.A., Ogunwande, L.A., Walker, T.M., Setzer, W.N., Soladoye, M.O., & Essen, E. (2006). Volatile constituents of *Aristolonchia repens*. *Natural Production Communications*, 1,763-765.
- Sun, H., Saeedi, P., Karuranga, S., Pinkepank, M., Ogurtsova, K., Duncan, B.B., Stein, C., Basit, A., Chan, J.C., Mbanya, J.C. & Magliano, D.J. (2022). IDF Diabetes Atlas: Global, regional and country-level diabetes prevalence estimates for 2021 and projections for 2045. *Diabetes Research and Clinical Practice*, 183, 109119.
- Tauchen, J., Fraňková, A., Maňourová, A., Valterová, I., Lojka, B., & Leuner, O. (2023). *Garcinia kola*: a critical review on chemistry and pharmacology of an important West African medicinal plant. *Phytochemistry Reviews*, 22(5), 1305–1351.
- Terri, A. & Sesin, P. (1958). Determination of serum potassium by using sodium tetraphenylborate method. *American Journal of Clinical Pathology*, 29(1),86-90
- Uloko, A., Musa, B.M., Ramalan, M., Gezawa, I., Puepet, F., Uloko, A.T., Borodo, M. M., & Sada, K. (2018). Prevalence and Risk Factors for Diabetes Mellitus in Nigeria: A Systematic Review and Meta-Analysis. *Diabetes Therapy*, 9(3), 1307–1316.
- Wadhwa, R.K., Steen, D.L., Khan, I., Giugliano, R.P., & Foody, J.M. (2016). A review of low-density lipoprotein cholesterol, treatment strategies, and its impact on cardiovascular disease morbidity and mortality. *Journal of clinical lipidology*, 10(3), 472-489.
- WHO. World Health Organization (2023). Diabetes. <https://www.who.int/news-room/fact-sheets/detail/diabetes>
- Yakubu, M.T., & Omar, S.A. (2019). Physicochemical characteristics of Groundwater samples and leachate from Gbagede dumpsite Amoyo, Kwara State, Nigeria. *Al-Hikmah Journal of Pure & Applied Sciences*, 7, 3137.
- Zafir, B., Aker, A., Naoum, I., & Saliba, W. (2023). Guideline-Directed Low-Density Lipoprotein Cholesterol Management After Acute Ischemic Stroke: Findings from a National Health Care Service. *The American Journal of Cardiology*, 203, 332-338