

Congenital mesenteric defects in an adult: A case report

Tamirat Bugie, Zinabu Abraham, Louis Marko and Sewnet Ejigu

Department of General Surgery and
College of Health Sciences and Medicine,
Wolaiat Sodo University, Ethiopia.

Correspondence:

Louis Marko

Email: louismarko13@gmail.com

Submitted: February 2023

Accepted: April 2023

Published: May 2023

ABSTRACT

A congenital mesenteric defect in an adult is very rare, but can cause an internal hernia with small bowel obstruction. Awareness of congenital mesenteric defects is important to the general surgeon when faced with an acute abdominal condition. We report a case of a congenital mesenteric defect in a 40-year-old man who presented to the emergency department with acute abdominal pain. An X-ray revealed multiple air fluid levels with dilatation of small and large bowels suggestive of bowel obstruction or bowel ischaemia, or bowel perforations. He underwent an emergency laparotomy through a midline incision. A large mesenteric defect was discovered with viable small and large bowel. A primary repair of the defect was carried out. The patient had an uneventful recovery. Early diagnosis and treatment are essential to avoid bowel ischaemia and decrease the mortality and morbidity.

Keywords: congenital mesenteric defect, hernia, surgery, Ethiopia

INTRODUCTION

Trans-mesenteric internal hernias are aptly named because they involve herniation through a gap in the mesentery. Although surgeons are aware of the acquired type of trans-mesenteric hernia after bowel anastomosis, the congenital form is quite rare. It is most likely due to failure of mesenteric development secondary to an ischaemic insult in utero. Intestinal atresia is also found in 50% of infants presenting with a trans-mesenteric defect. The pericaecal and sigmoid mesenteries and the duodenojejunal junction are the commonest locations for such defects. Approximately 30% of cases remain asymptomatic throughout life.^[1]

CASE REPORT

A 40-year-old Ethiopian man presented to the emergency department with a history of about 16 hours of periumbilical cramping non-radiating pain associated with nausea, and four episodes of non-bloody and non-bilious vomiting. He had absolute constipation. There was no report of fevers or chills. He had no previous abdominal surgery and no chronic conditions.

On examination: temperature 37.6°C, pulse 130/minute, blood pressure 100/66 mm Hg, respiratory rate 22/minute. There was no jaundice. The abdomen was distended and mildly tender on palpation with visible bowel peristalsis and hyperactive bowel sounds. A white blood cell count was elevated at 17,000/l and an abdominal X-ray (Figure 1) showed dilated small and large bowel with multiple air fluid levels. He was admitted for surgery. A nasogastric tube was placed for decompression. Intravenous normal saline 0.9% was started and intravenous ceftriaxone and metronidazole antibiotics were given.

Informed consent was obtained. The abdomen was opened through a midline incision. About 400 ml of peritoneal fluid were drained. The proximal (jejunum) small bowel had herniated through a mesenteric defect at the proximal level of the mesosigmoid colon mesentery about 15cm from the ligament of Treitz

Citation: Bugie et al., Congenital mesenteric defects in an adult: A case report, South Sudan Medical Journal, 2023;16(2):72-74 © 2023 The Author(s)
License: This is an open access article under [CC BY-NC](https://creativecommons.org/licenses/by-nc/4.0/) DOI: <https://dx.doi.org/10.4314/ssmj.v16i2.8>

Figures 2a and 2b). All the small bowel was viable with pulsations of the mesenteric vessels. There was no evidence of malrotation. The mesenteric defect was repaired using vicryl suture number 0 simple continuous (Figure 3).

The small bowel loop was repositioned, and the abdomen was closed in layers. The patient tolerated the procedure well. Bowel function resumed on the third postoperative day, and diet (tea and porridge) was initiated and tolerated. He was discharged on the tenth postoperative day. A follow-up check at one month showed that he was progressing well.

DISCUSSION

A mesenteric defect is a known cause of internal herniation with potential for intestinal strangulation. A congenital mesenteric defect most often occurs in the small bowel mesentery and less commonly in the colonic mesentery. Most cases have been reported in infants and children, often associated with another intra-abdominal anomaly. Murphy found, in a series of eleven infants presenting with herniation of the small intestine through a mesenteric defect, ten had an associated anomaly the commonest being intestinal atresia.^[2] The preoperative diagnosis of a mesenteric defect with herniation is difficult because of the wide range of abdominal symptoms. There are no specific radiographic findings apart from those of bowel obstruction. It has been reported that CT-scanning may suggest the presence of an internal hernia.^[3]

Due to their infrequency, congenital internal hernias are rarely suspected preoperatively and frequently diagnosed intraoperatively. The term congenital is not synonymous with childhood in this instance because these hernias are often diagnosed later in life. Mortality associated with congenital internal hernias is associated with delayed diagnosis and the septic complications of bowel ischaemia. Treatment involves reduction of the herniated bowel, resection of necrotic bowel and closure of the mesenteric defect. Closure can be performed with absorbable or non-absorbable sutures running or interrupted. The risk of mesenteric herniation is increased after laparoscopic procedures with bowel anastomoses, specifically in gastric bypass procedures, because the closure of the mesenteric defect can be difficult. There should be a high index of suspicion in such cases.^[1,4] Most cases, although suspected clinically, are found during surgery or upon autopsy.^[5]

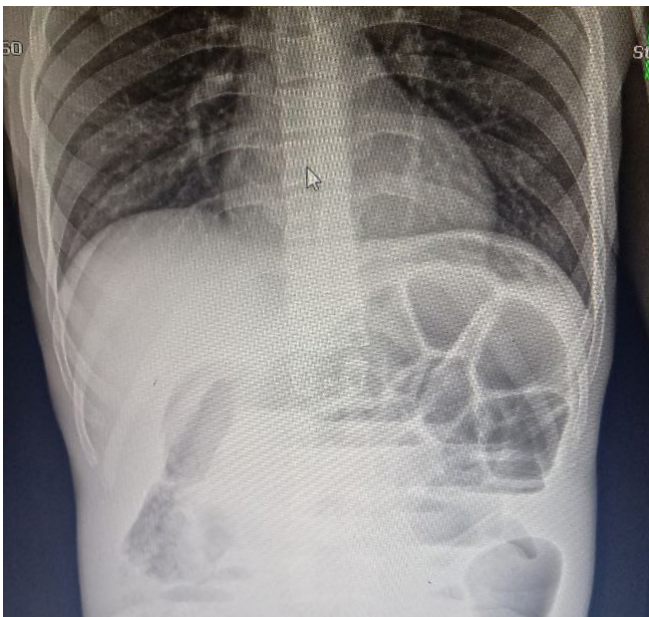


Figure 1. Abdominal X-ray showing dilated small and large bowel with significant multiple air-fluid levels (Credit: Dr Derilo Legesse)

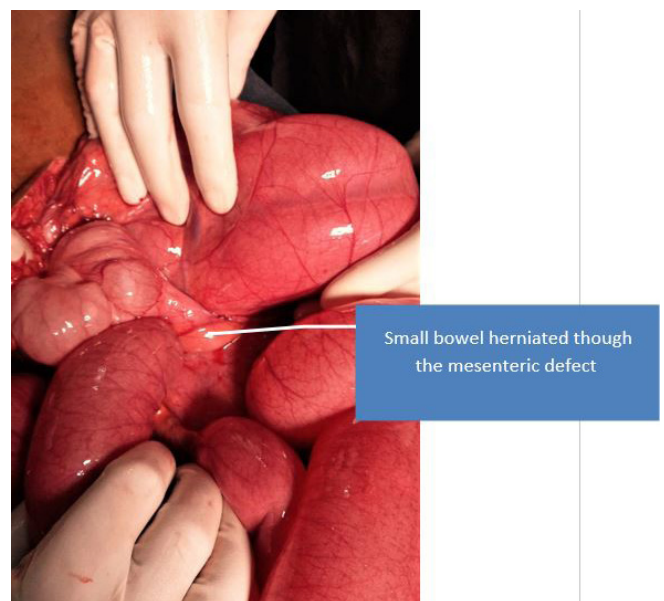
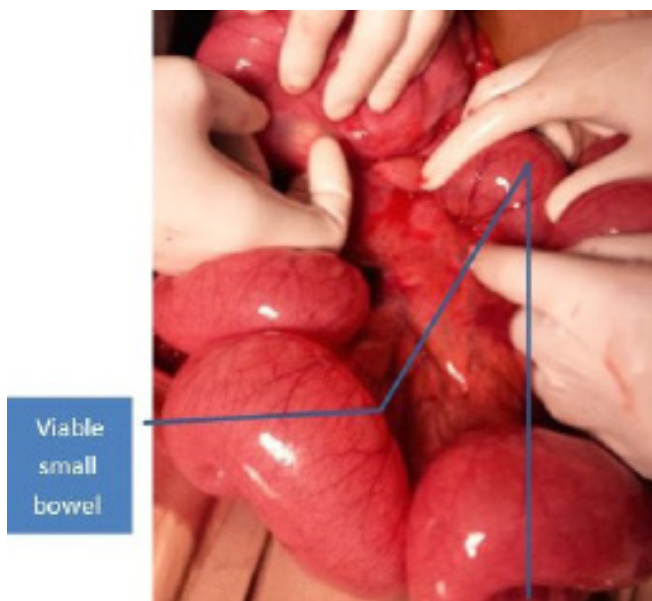


Figure 2a and b. Intraoperative finding showing viable small intestine herniated through a mesenteric defect (Credit: Dr Derilo Legesse)

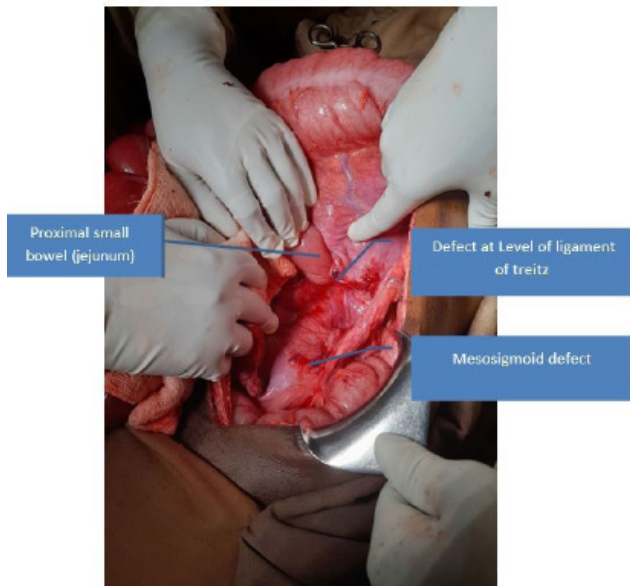


Figure 3. Large mesenteric defect closed from mesosigmoid to the level of ligament of Treitz (Credit: Dr Derilo Legesse)

The true incidence of mesenteric defects is unknown as many are asymptomatic. Mesenteric herniation as a cause of death is occasionally discovered at autopsy.^[6]

CONCLUSION

Mesenteric defect is rare, but the surgeons should be aware of the possibility and management to avoid the bowel necrosis and high mortality and morbidity

References

1. Wilkes J, Cullen JJ. Internal hernias; congenital and acquired. Shackelfords Surgery of Alimentary Tract 2019 8th Edition, p 860-862, Editors: Charles J.Yeo et al. <https://doi.org/10.1016/B978-0-323-40232-3.00074-1>
2. Murphy DA. Intestinal hernias in infancy and childhood. Surgery 1964;55:311-6.
3. Gyedu A, Damah M, Baidoo PK, Yorke J. Congenital transmesenteric defect causing bowel strangulation in an adult. Hernia 2010; 14:643-5.
4. Stehr W, Gingalewski CA. Other Causes of Intestinal obstruction. Pediatric Surgery 2012 Seventh edition p 1132, Editors: Arnold G. Coran et al.
5. Akyildiz H, Artis T, Sozuer E, Akcan A, Kucuk C, Sensoy E, et al. Internal hernia; complex diagnostic and therapeutic problem. Int J Surg. 2009;7:334-7.
6. Byard RW, Wick R. Congenital mesenteric defects and unexpected death-a rare finding at autopsy. Pediatr Dev Pathol 2008;11:245-8.