

# Brachial plexus block for the resection of a chondrosarcoma during COVID-19: A case report

Ehssan Mohamed<sup>1</sup> and Hassan Elbahri<sup>2</sup>

1. Department of Anaesthesia, Future Hospital, Khartoum, Sudan
2. Department of Orthopaedics, Faculty of Medicine, International University of Africa (IUA), Future Hospital, Khartoum, Sudan

Correspondence:

Ehssan Mohamed

Email: [ziyada@gmail.com](mailto:ziyada@gmail.com)

Submitted: March 2023

Accepted: March 2023

Published: May 2023

## ABSTRACT

A case report of a 35-year-old female with a large low-grade chondrosarcoma of the left humerus. Resection was performed under regional anaesthesia (interscalene brachial plexus block): this is a useful technique where there are limited resources and during the COVID-19 pandemic.

**Keywords:** Brachial plexus block, chondrosarcoma, COVID-19, resource limited setting

## INTRODUCTION

The severe acute respiratory syndrome, COVID -19, first appeared in December 2019 in Wuhan, China. The infection spread rapidly around the globe.<sup>[1]</sup> It manifests as a respiratory illness with a variety of presentations and outcomes.<sup>[2,3]</sup>

Transmission of this virus is from person to person through direct contact and respiratory droplets.<sup>[4]</sup> The spread was fast so it was advised that once the community spread is significant all cases may be presumed to be COVID-19 positive (patients may test negative during the incubation period which is 2-14 days).<sup>[5]</sup>

In Sudan the first case (and death) of COVID-19 was diagnosed on 13th March 2020 in Khartoum. A total lockdown of the Khartoum state was announced on 13th April.

## ANAESTHESIA AND CANCER SURGERY

Anaesthetic techniques are related to mortality and recurrence of certain types of cancers by an effect on the immune system.<sup>[6]</sup> Anaesthetic agents may have both direct and hormone mediated effects on many facets of immunocompetence.

Anaesthesia induced activation of the hypothalamic-pituitary- adrenal (HPA) axis and sympathetic nervous system (SNS) may facilitate metastasis through several tumour – derived soluble factors.<sup>[7]</sup>

Volatile anaesthetics and opioids suppress cell mediated immunity (CMI) and promote cancer cell proliferation and angiogenesis whereas propofol inhibits tumour angiogenesis and does not suppress the CMI.<sup>[8,9]</sup> Regional anaesthesia preserves the CMI and decreases surgically induced neuroendocrine responses by attenuating afferent neural transmission activation of the HPA axis and SNS response. Thus, reduction in opioid and volatile anaesthetic use may reduce cancer recurrence.<sup>[10]</sup>

Regional anaesthesia should be preferred whenever possible as it lowers the risk of postoperative complications. This becomes more important in the context of respiratory infections.<sup>[11,12]</sup> General anaesthesia (GA) with airway intervention leads to aerosol generation, which exposes the health care team to a risk of transmission of COVID-19 both during intubation and extubation.<sup>[13]</sup>

**Citation:** Mohamed and Elbahri, Brachial plexus block for the resection of a chondrosarcoma during COVID-19: A case report, South Sudan Medical Journal, 2023;16(2):68-71 © 2023 The Author(s)  
**License:** This is an open access article under [CC BY-NC](https://creativecommons.org/licenses/by-nc/4.0/) DOI: <https://dx.doi.org/10.4314/ssmj.v16i2.7>

**CASE PRESENTATION**

A 35-year-old female (ASA (American Society of Anaesthesiology) class 1) presented complaining of a left shoulder painful swelling and restricted movement for the last four months. A low-grade chondrosarcoma staging was based on X-ray of the left shoulder, CT chest and MRI of the entire humerus (Figure 1). Histological examination was done on a core needle biopsy. No other investigation carried out apart from the general pre-

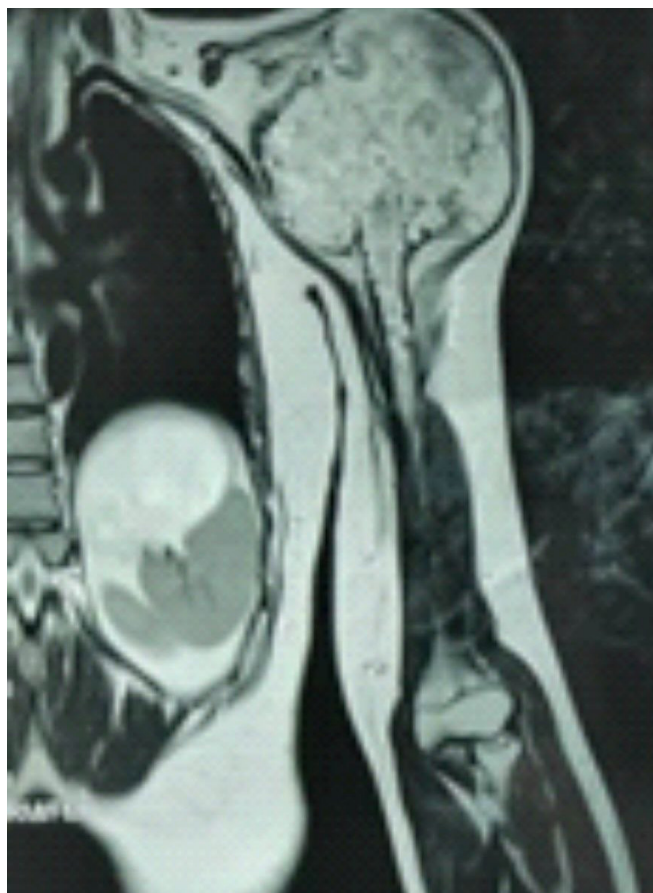

Figure 1. MRI shows heterogeneity large volume low grade chondrosarcoma tumour on proximal left humerus.

operative assessment laboratory investigations.

Surgery was considered to be urgently needed even during the COVID-19 pandemic. A wide resection and reconstruction with bone cement spacer build on Rush pin (an intramedullary stainless steel device) was planned. A prolonged operation was expected due to the large volume tumour as well as the preparation of the bone cement spacer over the Rush pin and stabilization to the glenoid and the remnant of the capsule by using prolene mesh. (Figures 2a and b).

In spite of these factors a regional anaesthetic brachial plexus block was considered appropriate.

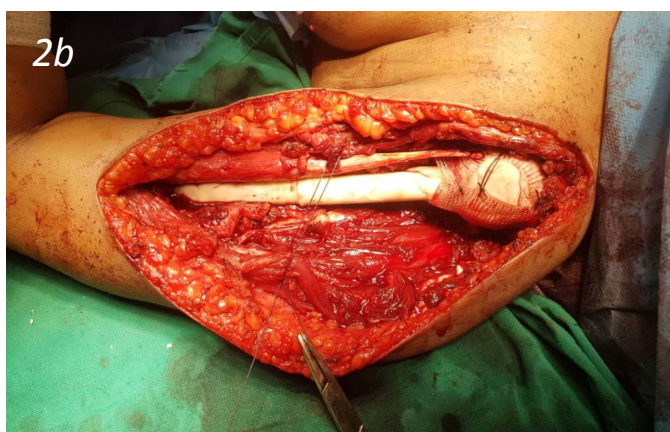
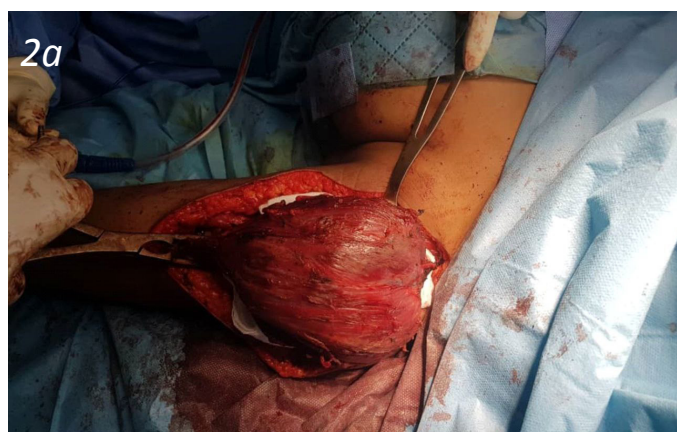Written informed consent was obtained from the patient. Standard ASA monitors were attached: non-invasive blood pressure, pulse oximeter and ECG, and two 18G intravenous canulae were inserted. Baseline vital signs were: BP:130/70; PR: 85; RR:15; SPO2: 98%.

The patient received 50 mcg of fentanyl and 1mg of midazolam as anxiolytic before performing the block. Oxygen saturation was monitored closely and ranged between 95% to 98% without oxygen supplementation.

**ANAESTHESIA PROCEDURE**

The anaesthetic procedure was explained to the patient. The left side of the neck, the site for the anaesthetic injections, was cleaned with 0.5% chlorhexidine in 70% alcohol. A mixture of 15 ml of plain marcaine 0.5% plus 10 ml of lignocaine with adrenaline 1% plus 2 ml of dexamethasone of 8 mg was used. With ultrasound guidance the interscalene brachial plexus was identified. This step was carried out with 12ml of the local anaesthetic mixture which was injected around C5 and C6 roots. Then a subclavian perivascular block was performed with 15 ml of the local anaesthetic.

Regional anaesthesia was performed using an old version of an ultrasound device (Alpinion-Ecube 5). (Figure 3a and b).



Figures 2a and b. Resection and reconstruction by cement spacer

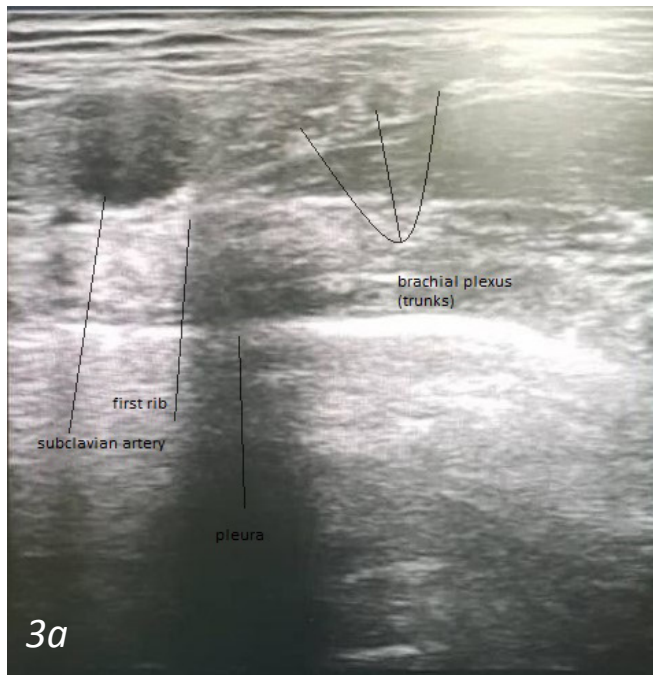


Figure 3a. Supraclavicular brachial plexus block

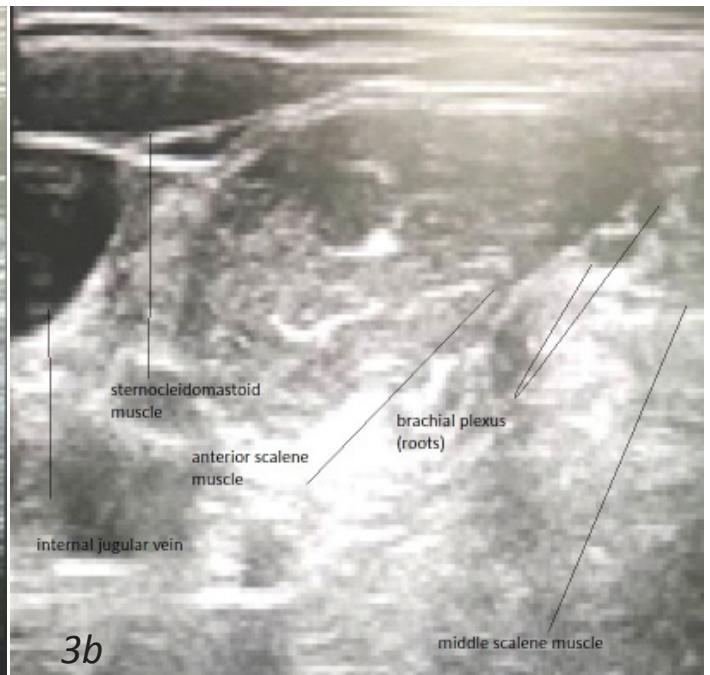


Figure 3b. Interscalene brachial plexus block

After fifteen minutes the site for the incision, which was expected to extend to the tip of the shoulder, was checked and found to have sensory and motor block. Paracetamol 1gm iv and sodium diclofenac 75mg im were given and fifteen minutes later the surgery started and continued for five hours, during which the patient was completely pain free (using a visual analogue scale). Vital signs remained stable throughout.

The surgery was done through the deltopectoral approach. The neurovascular bundle was identified, and isolated. The deltoid muscle was detached from the proximal humerus as well as the whole rotator cuff muscles. Resection of 17 cm of humerus was done with a 3 cm free margin from the distal end of the intramedullary extension of the lesion according to the preoperative MRI.

The block lasted for eight hours post-operatively. The patient was monitored for 24 hours for pain and given paracetamol 1 gm 6 hourly (i.v) and sodium diclofenac 75 mg (i.m) 8 hourly as the only analgesics.

## CONCLUSION

The brachial plexus block as regional anaesthesia was found to be a safe method. Also, it was safe for operating room staff especially during the risk of respiratory virus spread as in this COVID-19 pandemic. It should be considered as alternative for ill patients instead of general anaesthesia. Regional anaesthesia is an accepted alternative for cancer surgery with decreased mortality and recurrence rate. In

our case only brachial plexus block was needed, in spite of a large tumour size, prolonged surgery and an extensive incision. Conventional ultrasound without nerve stimulation can be used successfully to guide the block in limited resource settings. Postoperatively the patient needed only simple analgesics.

## References

1. World Health Organization. Coronavirus disease 2019 (COVID-19) Situation report-77 [https://www.who.int/docs/default-source/coronaviruse/situation-reports/20200406-sitrep-77-covid-19.pdf?sfvrsn=21d1e632\\_2](https://www.who.int/docs/default-source/coronaviruse/situation-reports/20200406-sitrep-77-covid-19.pdf?sfvrsn=21d1e632_2).
2. Huang C, Wang Y, Li X, Ren L, Zhao J, Hu Y, et al. Clinical features of patients infected with 2019 novel coronavirus in Wuhan, China. *Lancet*. 2020; 395(10223):497–506.
3. Chersich MF, Gray G, Fairlie L, Eichbaum Q, Mayhew S, Allwood B, English R, Scorgie F, Luchters S, Simpson G, Haghghi MM. COVID-19 in Africa: care and protection for frontline healthcare workers. *Globalization and Health*. 2020 Dec; 16:1-6
4. Shereen MA, Khan S, Kazmi A, Bashir N, Siddique R. COVID-19 infection: origin, transmission, and characteristics of human coronaviruses. *Journal of Advanced Research*. 2020 Mar 16.

5. Uppal V, Sondekoppam RV, Lobo CA, Kolli S, Kalagara HK. Practice recommendations on neuraxial anesthesia and peripheral nerve blocks during the COVID-19 pandemic. *ASRA/ESRA COVID-19 Guidance for Regional Anesthesia* March. 2020 Mar 31;31:31. Kim R. Anesthetic technique and cancer recurrence in oncologic surgery: unraveling the puzzle. *Cancer and Metastasis Reviews*. 2017 Mar 1; 36(1):159-77.
6. Zappalà G, McDonald PG, Cole SW. Tumor dormancy and the neuroendocrine system: an undisclosed connection? *Cancer and Metastasis Reviews*. 2013 Jun 1; 32(1-2):189-200.
7. Gottschalk A, Sharma S, Ford J, Durieux ME, Tiouririne M. The role of the perioperative period in recurrence after cancer surgery. *Anesthesia & Analgesia*. 2010 Jun 1; 110(6):1636-43.
8. Neeman E, Ben-Eliyahu S. Surgery and stress promote cancer metastasis: new outlooks on perioperative mediating mechanisms and immune involvement. *Brain, behavior, and immunity*. 2013 Mar 15; 30:S32-40.
9. Horowitz M, Neeman E, Sharon E, Ben-Eliyahu S. Exploiting the critical perioperative period to improve long-term cancer outcomes. *Nature reviews Clinical oncology* 2015 Apr; 12(4):213.
10. Warren J, Sundaram K, Anis H et al. Spinal anesthesia is associated with decreased complications after total knee and hip arthroplasty. *J Am Acad Orthop Surg*. 2020; 28:e213-e221 <http://doi.org/10.5435/JAAOS-D-19-00156>
11. Von Ungern-Sternberg BS, Boda K, Chambers NA et al. Risk assessment for respiratory complications in paediatric anaesthesia: A prospective cohort study. *Lancet*. 2010; 376:773-83.
12. World Health Organization. *Infection prevention and control of epidemic-and pandemic-prone acute respiratory diseases in health care*. Geneva: WHO; 2014.