

Case Report: Necrotizing fasciitis of the neck with odontogenic origin

**Ernesto Carmona Fernández
and Dalia Leidys Echevarria
Gonzalez**

Department of Dentistry,
Oshakati Intermediate Hospital,
Namibia.

Correspondence:
Ernesto Carmona Fernández
ernesto847@yahoo.com

Submitted: September 2019
Accepted: December 2019
Published: February 2020

Citation:
Fernandez and Gonzalez, Necrotizing fasciitis of the neck with odontogenic origin. *South Sudan Medical Journal* 2020; 13(1):24-28
© 2020 The Author (s)
License: This is an open access article under [CC BY-NC-ND](https://creativecommons.org/licenses/by-nc-nd/4.0/)

Necrotizing fasciitis is a severe and rare infectious disease. There is extensive necrosis of subcutaneous tissues and fascia layers, and gangrene. To reduce mortality, a rapid diagnosis, aggressive surgical treatment, and appropriate antibiotic therapy are essential. Usually the underlying cause is dental and especially common in immunologically compromised patients.

This case report is an example managed by the authors.

Keywords: cervical necrotizing fasciitis, infection, immunology, depressed patients

INTRODUCTION

Necrotizing fasciitis is an uncommon condition arising from bacterial infection. It leads to skin and soft tissue destruction, affecting fascia that cover muscles and subcutaneous fat. *Streptococcus pyogenes* is a common cause but a number of other bacteria may be involved.^[1-3]

Any part of the body may be affected. Common sites are the feet, lower legs, hands and genital regions (Fournier's gangrene). It also occurs in the mouth (Ludwig's angina) and neck region. The most susceptible individuals include those with immunocompromise caused by HIV infection, chemotherapy, steroid treatment and radiotherapy; chronic diseases such as diabetes mellitus, cancer, liver or kidney diseases, malnutrition, and alcohol abuse.^[4, 5]

CASE REPORT

A 23-year old male, who had no significant past medical or surgical history, was admitted to our Maxillofacial Department, having attended another hospital where a tracheostomy was performed. He had dysphagia, odynophagia, and a fever of 39°C. There was cervical necrosis on the right side extending over the midline to the left side and on to the clavicular region. These whole areas were painful to touch and swollen as was the face with palpable gaseous crepitus.

Oral endoscopy was difficult because of trismus and odontogenic infection in the left lower mandible. The colour changes on the skin of the neck; were caused by the presence of necrotic tissue, associated with a lot of pus and debris (Figure 1).

The results of investigations are shown in Table 1. The chest X-ray was normal; the pulse rate was 129 beats/min and blood pressure 70/40 mmHg.

The patient was prepared for emergency surgery. Meanwhile hydration therapy was instituted using Ringer lactate 500ml six times a day, until the patient clinically stabilized. Electrocardiogram was normal, apart from a tachycardia.

At surgery multiple bilateral cervical incisions were made from the inferior border of the mandible to the clavicles, including the parotid region and part of the cheek. All necrotic tissue was removed. Hydrogen peroxide and iodine solution were used to clean the areas. This procedure was carried out four times under general anaesthesia every second day, until the infection was controlled, based on blood tests results and clinical review of the wound. (Figures 2a and b). On admission

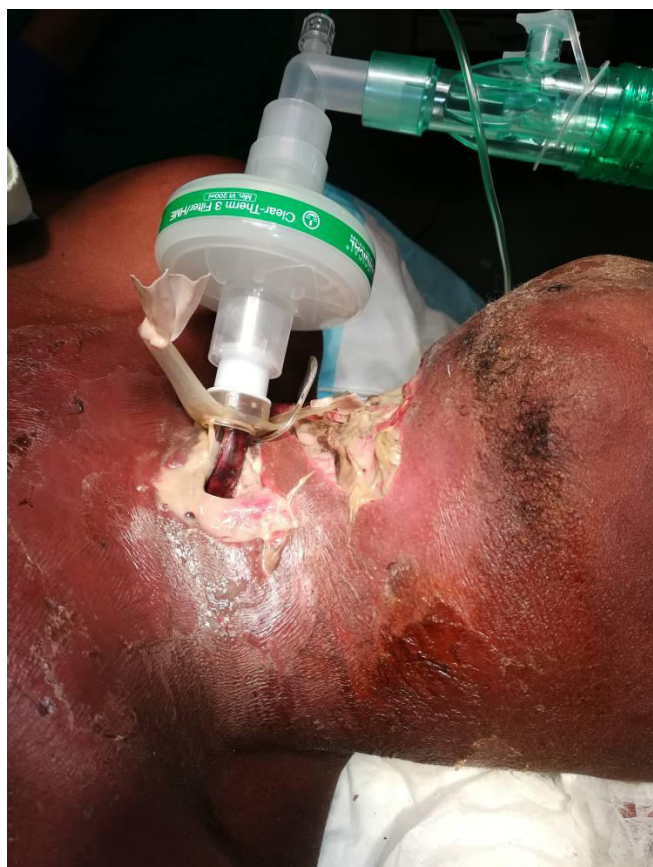

Figure 1. Clinical appearance of the patient

Table 1. Blood test values

Tests	Results	Normal ranges
White Cells Count	13x 10 ⁹ /L	5 to 10 × 10 ⁹ /L
Neutrophils	80.0 %	40–70%
Haematocrit	34.30 %	40 to 50%
Haemoglobin	10.1 g/dl	13.5 to 17.5 g/dl
Glucose	5.3 mmol/L	4.0 to 5.4 mmol/L
ESR	59 mm/hr	0 and 15 mm/hr
C reactive protein (CRP)	200mg/l	0-10.0 mg/l
Albumin	2.2g/l	3.4 -5.4 g/dl
Creatinine	1.1 mg/dL	0.6-1.2 mg/dl.
ALP	67	44-147 IU/l
GGT	24	9–48 U/l
Pulse Rate	129 b/min	60-100 b/min
Tests for hepatitis B (anti-HBs)	Non-reactive	Non-reactive/ Reactive
Tests for hepatitis C	Non-reactive	Non-reactive/ Reactive
HIV Rapid Test	Negative	Negative/Positive

the patient received broad spectrum antibiotic therapy consisting of meropenem 1g 3 times a day, vancomycin 1g 2 times a day and metronidazole 500mg 3 times a day. In addition, rehydration was continued, antipyretics: paracetamol 1g IV 4 times a day, vitamin C 200mg IV 3 times a day, and multivitamins intramuscularly were administered as well. Before antibiotic therapy, microbial cultures were taken and an antibiogram was performed. Empiric treatment was instituted. The microbiological examinations were negative, assuming these results could be wrong because there were not trained personal in the hospital to carry out these procedures. During the surgery, the cause of the infection (first and second molar on the lower jaw of the right hemi mandible) was removed and various samples were taken for pathological examination.

The patient was monitored with blood tests (showing CRP decreased to 15 mg/l, neutrophils to 11%), and clinical progression watched. Daily dressing was continued without anaesthesia once the infection was controlled and all the necrotic tissue removed.

CT scanning was done 8 days after admission, when the patient was stable and controlled, excluding other source of infection, such as: sinusitis, parapharyngeal space abscess, peritonsillar abscess, submandibular gland abscess, abscessed lymph node.

The cervical and thoracic regions revealed the subcutaneous tissue was extensively oedematous. Multiple lymph nodes were visible in the submandibular spaces. A right submandibular gland was oedematous, caused by the infection. The thoracic images with and without contrast medium were normal.

The clinical parameters improved with the antibiotic therapy, hydration and debridements.

The tracheostomy tube was removed after the second surgery, because the patient was able to breathe normally.

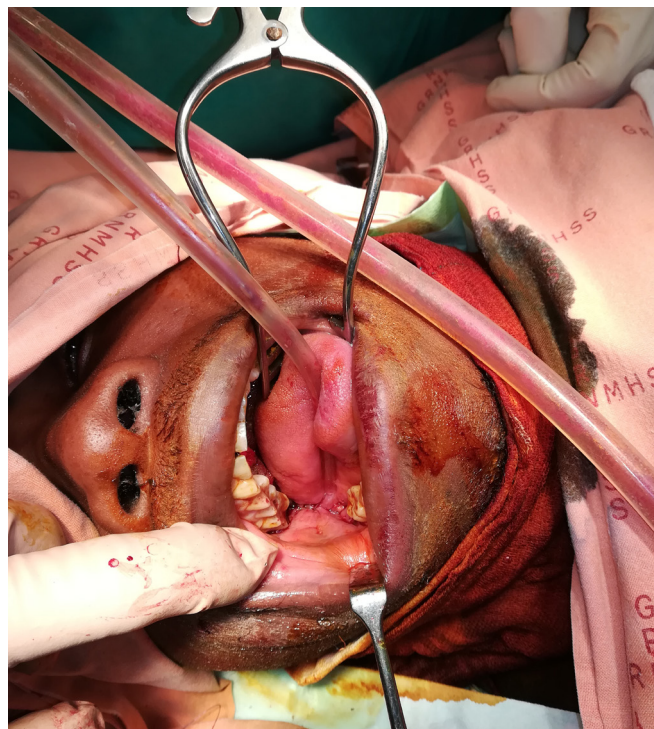
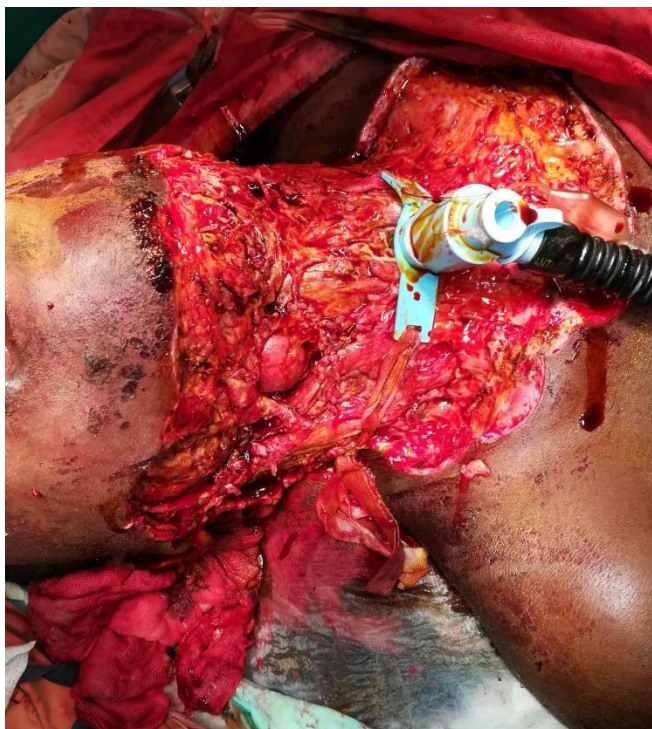Healthy granulation tissue grew satisfactorily over the operative site and the tracheostomy healed (Figure 3). Skin grafting was carried out after 20 days of the first surgery, when there were no signs of infections and there was enough granulation tissue. (Figure 4)

The patient wore a cervical collar for two months to prevent wound retraction.

After the second week of being grafted, the patient was discharged and follow-up arranged.

DISCUSSION

There are few case reports of cervical necrotizing fasciitis. [6] Although immunocompromised patients are at increased risk of developing this condition our patient was not immunocompromised. [1, 3, 5] The causative organism may be a single agent, commonly Group A β -haemolytic streptococcus or staphylococcus aureus



Figures 2a and b. Necrectomy debridement and dental extractions.

or may be a polymicrobial involving Gram-positive and Gram-negative aerobic and anaerobic bacteria and fungi. However, many authors have failed to identify any organisms on culture.^[6]

Initially, there is cellulitis extending into the deeper tissues. Clinically, there is cutaneous erythema and oedema. As necrosis increases more bacterial flora gain access. This bacterial overgrowth reduces oxygen tension causing local ischaemia and proliferation of anaerobic organisms. In 4-5 days, gangrene becomes evident and after 8-10 days necrotic tissue separates.^[6, 7]

As the disease progresses, signs of necrotizing fasciitis appear "...a dusky discoloration of skin appearing as small purplish patches with ill-defined borders. Concomitantly blisters or bullae of a few millimetres in diameter appear on the skin of the involved area. The skin beneath blisters becomes necrotic and blue in colour. Localized necrosis of skin is secondary to thrombosis of nutrient vessels as they pass through the zone of involved fascia."^[7, 8]

Cervical necrotizing fasciitis of dental origin commonly involves the mandibular second and third molars, as the apices of these teeth extend below the mylohyoid muscle insertion. Infection from these teeth easily extends into the submandibular space. In our case, the maxillary second molar was the infection focus, which was consistent with findings of many authors.^[9]

Necrotizing fasciitis of dental origin invades deep tissue planes in the early stage. It is only when the infection reaches the superficial fascia, spread becomes rapid and the

typical features of necrotizing fasciitis appear. This mode of presentation can be misleading to the unsuspecting clinician, making early diagnosis difficult.^[10]

However, some findings may present clinically when suspecting cervical necrotizing fasciitis:

1. Odontogenic infection that spreads to neck and anterior chest.
2. Accumulation of gas in the tissue.
3. Very rapid progression of infection.
4. "Orange peel" appearance of the involved skin which changes to a dusky discoloration.

Overlying oedematous tissue or the absence of gas may obscure subcutaneous crepitus

The key to prompt diagnosis of necrotizing fasciitis and institution of urgent treatment depend on a thorough clinical history and examination and the clinician having a high index of suspicion.^[11]

The cornerstone of treatment is surgical debridement. All necrotic tissue must be removed to healthy bleeding tissue. Reluctance to debride facial soft tissues adequately, hoping to avoid unsightly disfigurement often leads to under treatment. Multiple surgical debridements are usually needed.^[12]

Meropenem, vancomycin and metronidazole, was the triple therapy chosen because in our experience good results have been obtained. This antibiotic regime also

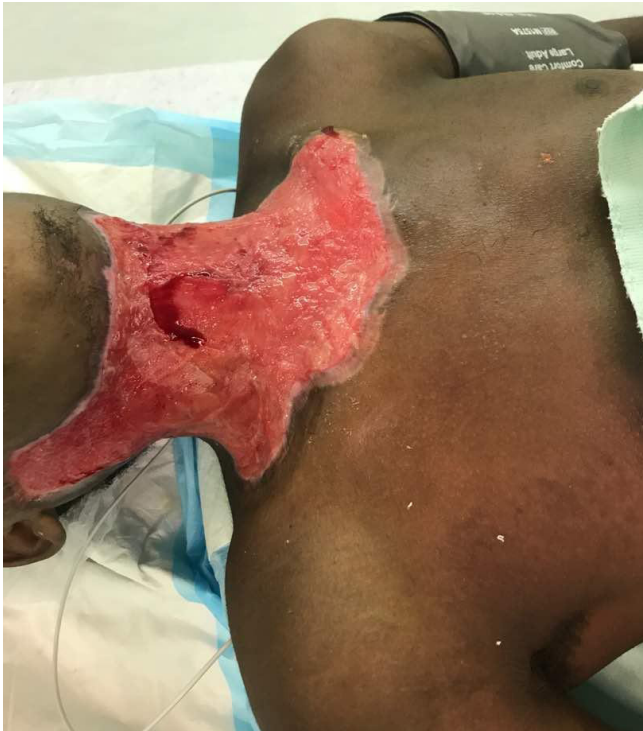

Figure 3. Surgical defect ready for grafting

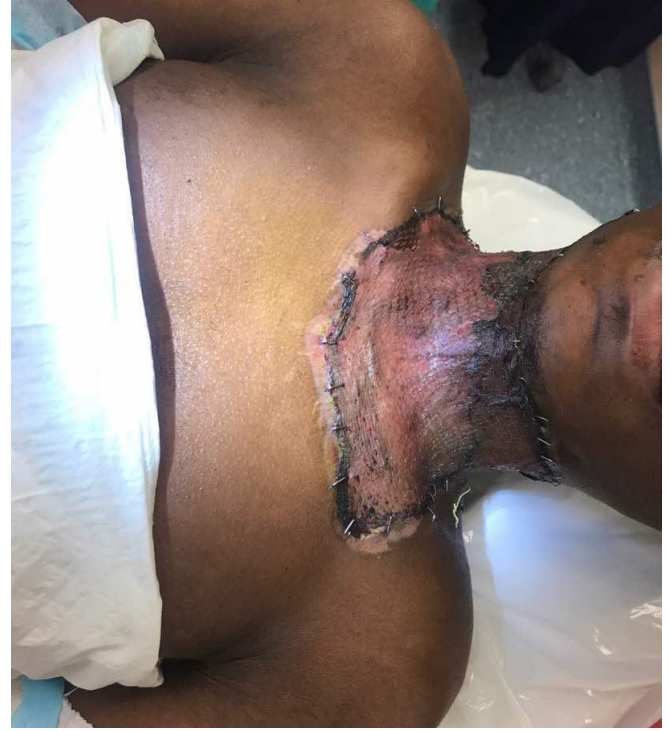

Figure 4. Skin graft

covers most of the micro-organisms known to be associated with necrotising fasciitis. However, the most important action is to bring the patient to surgery as soon as possible to control and eliminate the source of infection, that is to remove all the necrotic tissue plus extraction of the causative tooth.

On the other hand, the use of vitamin c it is demonstrated to have a good result in the satisfactory progression of the disease since this vitamin acts like an antioxidant, which is very important, since during infection, a lot of toxins are released into the blood stream. Multivitamins are used as a supplementary to increase and help immune responses.^[12-14]

Povidine-iodine (Bethadine), a complex of iodine, the bactericidal component, with polyvinylpyrrolidone (povidone), a synthetic polymer Povidone-iodine, without the detergent, is distributed most commonly as a 10% solution. When diluted to a 1% concentration or lower, it can be applied safely to wounds retaining its bactericidal activity.

Hydrogen peroxide (3% H₂O₂) was used to clean wounds With advances in research, H₂O₂ at μ M levels has been reported to act as a signalling molecule which drives redox-sensitive signalling mechanisms to improve dermal wound healing.^[13-15]

After surgical debridement, wounds are left open and packed with povidine moisturized gauze, which is changed frequently. It is important to prevent pooling of secretions in the wound that may provide a culture medium for

further bacterial growth. Along with debridement, appropriate antibiotic coverage is imperative.^[14, 15]

Hyperbaric oxygen therapy has gained support as an adjunctive treatment for necrotizing fasciitis. Published reports cite a 50% reduction in mortality when this is used along with surgery,^[5] but its role in necrotizing fasciitis has been questioned by other authors.^[14]

Once the infection has been resolved, the defect can initially be covered with a split thickness skin graft and reconstructed secondarily by advancement flaps or revascularized free flaps if necessary.^[15]

CONCLUSION

Cervical necrotising fasciitis is an uncommon, life-threatening disease which can present with deceptively innocuous symptoms and signs. Early diagnosis and aggressive management are critical to reducing the associated morbidity and mortality.

References

1. López Aparicio E, Gómez Arcila V, y Carmona Meza Z. [Fascitis Necrotizante de origen dental: Reporte de Caso](#). Rev. CES Odont. 2017; 30(1): 68-74.
2. Alan Y, Martínez C, Mc Henry Y. y Meneses L. [Fascitis necrotisante cervicofacial: una infección severa que requiere tratamiento quirúrgico temprano](#). Rev Esp Cirug Oral y Maxilofac. 2016 Mar; 38(1): 23-28.

- Barría T, Abarca A, Cancino M, Chávez C, Parra J. y Rahal M. [Fascitis necrotizante cervical: Consideraciones para el manejo precoz.](#) Rev. Otorrinolaringol. Cir. Cabeza Cuello. 2018 Sep; 78(3): 294-299.
- Sandoval M, Fernández M.Á. y Donoso F. [Complicaciones infecciosas severas del territorio maxilofacial: presentación de casos clínicos.](#) Rev. Clin. Periodoncia Implantol. Rehabil. Oral. 2017 Dic; 10(3): 169-172.
- Calderón Peñalver PA, Rodríguez Miranda OG, Señor Castañeda S. y García Céspedes D. [Angina de Ludwig. Presentación de un caso.](#) Rev. Med. Electrón. 2016 Feb; 38(1): 87-96.
- Padilla Rosas M, Nava Villalba M, Robles Gomez C, Puebla Mora AG. y Godinez Rubi J.M. [Quiste dentigero bilateral. Tratamiento conservador seguimiento a seis meses.](#) Impacto odontológico. 2017; 2(3): 72-75.
- Arruda JA, Figueiredo E, Álvares P, Silva L, Silva L, Caubi A, et al. [Cervical Necrotizing Fasciitis Caused by Dental Extraction. Case Reports in Dentistry.](#) 2016 [cited: 2018 Dic 14]; 2016(s/n)
- Manish Tiwari M, Meshram V, Lambade P, Fernandes G. [Cervicofacial necrotizing fasciitis of odontogenic origin: A case report.](#) Mouth Teeth [serial on the Internet]. 2018; 2(2)
- López Aparicio E, Gómez Arcila V, Carmona Meza, Z. Fascitis [Necrotizante de origen dental: Reporte de Caso.](#) CES odontol. [serial on the Internet]. 2017 June; 30(1)
- Mosaa K, Alqahtani N, Shata R, Quraishi H, Algorashi A. [Necrotizing Fasciitis of Neck due to Third Molar Infection: Case Report.](#) Authors Journal. 2017
- Pasternack MS. [Cellulitis, necrotizing fasciitis, and subcutaneous tissue infections.](#) In: Mandell D and Bennett. Principles and practice of infectious diseases. (Eighth Edition). 2015.
- Hall BS, Meredith MD, Allen MD. [Orbital necrotizing fasciitis.](#) Ophthalmology and Visual Sciences. 2016; 36(2): 67-72
- Gore, M. R. [Odontogenic necrotizing fasciitis: a systematic review of the literature.](#) BMC Ear, Nose and Throat Disorders [serial on the Internet]. 2018; 18(1): 14
- Abdurrazaq TO, Ibikunle AA, Braimah RO. [Cervical necrotizing fasciitis: A potentially fatal disease with varied etiology.](#) African Journals Online (AJOL). 2016; 6(4): 14
- García FG, Fuentes GC, Arcos HG, y Brito DM. [Fascitis Necrotizante de la pared torácica. A propósito de 3 casos.](#) Rev Esp Patol Torac. 2016; 28(4): 229-233.

All images by Ernesto Carmona Fernández. The patient gave consent for his information and images to be published in SSMJ.

The Double Burden of Malnutrition

The double burden of malnutrition is the coexistence of overnutrition (overweight and obesity) alongside undernutrition (stunting and wasting), at all levels of the population—country, city, community, household, and individual. On December 16th 2019 The Lancet published a four-paper series which explores how this coexistence is affecting low-income and middle-income countries.

Malnutrition in its many forms has previously been understood and approached as a separate public health issue, but the new emergent reality is that undernutrition and overnutrition are interconnected and, therefore, double-duty actions that simultaneously address more than one dimension must be implemented for policy solutions to be effective. In addition to policy recommendations, the Series includes a focus on both historical and biological contexts, and new economic analysis.

See: <https://www.thelancet.com/series/double-burden-malnutrition>