

Bladder exstrophy – epispadias complex in a newborn: a case report and review of literature

Paul N. Tolefac^{b,f}, Eugene Yeike^{c,f}, Calypse Ngwasiri^f, Gregory Ekane Halle^{a,d} and Alain Mefire Chichom^d

a Department of Obstetrics and Gynaecology, Douala General Hospital, Douala, Cameroon

b Faculty of Medicine and Biomedical Sciences, University of Buea, Cameroon

c St Elizabeth General Hospital Shishong, Kumbo, Cameroon

d Faculty of Health Sciences, University of Buea, Cameroon

e Service of Paediatric Surgery, Douala Gynaeco-Obstetric and Paediatric Hospital, Douala, Cameroon

f Clinical Research Education Networking and Consultancy

Correspondence: Paul N. Tolefac, ptolefac15@gmail.com

Submitted 2 August 2017 Accepted: 10 October 2017 Published: 15 February 2018

Background: Bladder exstrophy-epispadias complex (BEEC) is a rare congenital malformation of the genitourinary system usually associated with other malformations.

Case summary: We report the case of a new born delivered vaginally at 39 weeks and 2 days of gestation with BEEC. Three prenatal ultrasound scans missed the diagnosis. Medical management was provided and the patient was discharged against medical advice 48 hours later upon refusing surgical intervention.

Conclusion: The diagnosis and management of BEEC is a challenge in sub-Sahara Africa. Radiologists doing prenatal ultrasounds should check routinely to exclude foetal anomalies.

Reporting: Care 2016 guideline.

Key words: bladder exstrophy, epispadias, congenital malformation, prenatal ultrasound

INTRODUCTION

Bladder exstrophy-epispadias complex (BEEC) is a congenital anomaly of the genitourinary system with a spectrum of congenital malformations ranging from isolated epispadias, to classical bladder exstrophy, to cloacal exstrophy as the most severe—and rarest—presentation.

The malformation may extend to involve the genitalia, the abdominal wall muscles, the pelvic floor musculature, and the bony pelvis ^[1,2]. The incidence as estimated by Nelson et al ^[3] is 2.15 per 100,000 live births with classical bladder exstrophy estimated at 1:10,000 to 1:50,000 live births and epispadias estimated at 1:117,000 live births ^[4].

BEEC results from an insult during the development of the urogenital system during which there is a disorder leading to cloacal membrane overgrowth preventing medial migration of mesenchymal tissue ^[1]. The main stay in the management of BEEC is surgery. This varies depending on the type and severity of the defect. Currently, a staged approach is the most commonly used strategy. In the standard-staged repair, a primary closure of the bladder without osteotomy, and genital reconstruction, is attempted in the first 72 hours of life in males. Then

between 6 and 12 months of age, the epispadias is repaired. Bladder neck reconstruction follows around the age of 5 years, if a reasonable bladder capacity is reached ^[5].

We present a case of a child delivered vaginally at 39 weeks and 2 days of gestation with BEEC. All three prenatal ultrasound scans missed the diagnosis. Medical management was given and the patient was discharged against medical advice 48 hours later upon refusing surgical intervention.

CASE PRESENTATION

A new-born male was delivered vaginally at 39 weeks + 2 days of gestation to a 29 year old mother gravida 3 para 2. Her pregnancy was uneventful. Prenatal ultrasounds done at 12 weeks, 23 weeks and 31 weeks of pregnancy did not detect any foetal anomaly. Apart from routine sulfadoxine – pyrimethamine and iron and folic acid taken, the mother did not take any other drug during pregnancy.

Following delivery, the new-born presented with a genitourinary defect as shown in Figures 1 and 2. There was an abdominal wall defect with an exposed and everted bladder draining urine which was clearly visible

immediately below the umbilical stump (Figure 1); a complete dorsally opened urethral plate running from the bladder neck down to the open glans (Figure 2); left and right corpora cavernosa were clearly visible beneath and alongside the urethral plate (Figure 2); the scrotum was normally developed, with descended testes (Figure 1). There was no associated anorectal malformation (ARM), the anus was present, normally located and patent.

Other aspects of the physical examination were normal. This genitourinary anomaly was consistent with the bladder exstrophy–epispadias complex (BEEC). The defect was covered in delivery room with sterile silicon gauze and transparent waterproof dressing and the baby transferred to the neonatal unit. Trans-fontanel, cardiac, pelvis, and renal ultrasounds were then performed and found to be normal. Biological investigations including full blood count, serum electrolytes, urea and creatinine were performed and reported to be normal. The baby spent 48 hours in the neonatal unit and the parents signed for discharge against medical advice.

DISCUSSION

Epidemiology

BEEC is a rare congenital malformation of the genitourinary system with an incidence estimated by Nelson et al [3] in 2.15 per 100,000 live births, with an even male-to-female ratio (OR = 0.989; 95% CI = 0.88–1.12), and a significantly increased incidence in Caucasians compared with other neonates (incidence, 2.63 vs. 1.54 per 100,000; $p < 0.0001$). This incidence varies depending on the geographical location and socioeconomic status [3]. The clinical syndrome includes bladder exstrophy, epispadias and cloacal exstrophy. Classic bladder exstrophy occurs in 1:10,000 to 1:50,000 live births [4]; epispadias is estimated to occur in 1:117,000 live births [6], and cloacal exstrophy in 1:250,000 births [7]. The incidence is not known in our sub region.

Embryology

The embryology of the BEEC has been long studied, yet debate still exists over the specific origins of the anomaly [8]. It is thought to be derived from a derangement in the fusion of the mesoderm during the first week of life [1]. Normally, at the end of third week of life, intermediate mesoderm invaginate to form the genitourinary system, while the lateral plate mesoderm will contribute to forming the primitive gut tube [1,2]. A disruption in this interaction, linked to cloacal membrane overgrowth preventing medial migration of mesenchymal tissue, is reported to give rise to BEEC [9].

The severity of the resulting condition depends on the point at which disturbed mesodermal layers interaction begins. Given the embryological origin of BEEC, it is often associated with other peculiar

orthopaedic, musculoskeletal, and gynaecological conditions. Associated upper urinary tract anomalies are rare. Gastrointestinal and spinal/neurological anomalies can be associated in patients with BEEC. Some of the associated malformations include: vesicoureteric reflux, mega ureter, horseshoe kidney, ureterocele, abdominal wall defect, umbilical hernia, neural tube defects, spinal dysraphism, club feet, congenital hip dislocation, pubic symphysis diastasis, anterior displaced anus, imperforate anus and Mullerian anomalies [1,5,10]. In our indexed case, after a thorough clinical assessment and morphological investigations, the only associated anomaly was abdominal wall defect as the anus was patent, and renal, trans-fontanel and pelvic ultrasounds were normal.

Prenatal diagnosis

The diagnosis of BEEC can be made before delivery by prenatal ultrasounds. It is based on the non-visualization of the bladder during the first trimester ultrasound but in most cases, it is confirmed by an ultrasound in the second trimester. This second trimester morphological ultrasound also helps in the diagnosis of other associated malformations [11]. In one study, the sensitivity of prenatal ultrasound for diagnosis of congenital malformations was estimated at 7/36 (19%) at 17-18th week of gestation, and 13/36 (36%) overall [12]. In another study, 43 prenatal ultrasounds from 25 pregnancies with bladder exstrophy, where the ultrasound was done between 14-36 weeks of pregnancy, the diagnosis of bladder exstrophy was made before delivery in only three cases.

Five factors associated with bladder exstrophy were identified:

1. Non-visualization of the bladder on ultrasound in 12 of 17 cases (71%);
2. Lower abdominal bulge representing the exstrophic bladder in eight of 17 cases (47%);
3. A small penis with anteriorly displaced scrotum in eight of 14 males (57%);
4. Low set umbilical insertion in five of 17 cases (29%); and
5. Abnormal widening of the iliac crests was seen in three of 17 cases (18%) [13].

In our patient three prenatal ultrasounds were done between 12 and 31 weeks and none was diagnostic of bladder exstrophy. The radiologists did not mention any of the above features. Factors contributing to missed prenatal diagnosis may include: low incidence of the pathology, lack of clinical suspicion, few radiologists and high workload, poor local training and lack of continuous medical education.

Management

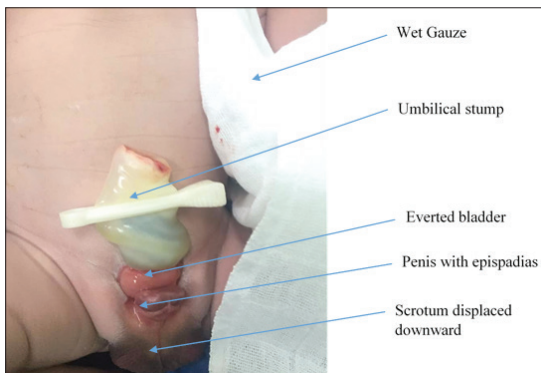


Figure 1. Showing bladder everted and scrotum displaced downward (credit: Paul N. Tolefac)

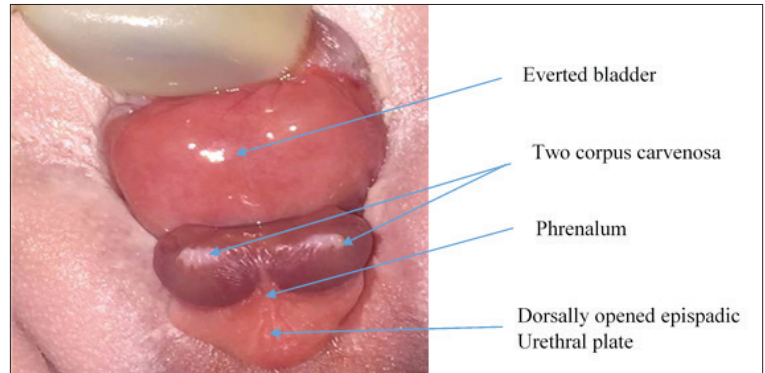


Figure 2. Showing bladder everted, corpus carvenosa and a dorsally opened epispadic urethral plate (credit: Paul N. Tolefac)

BEEC is a paediatric urological emergency. Immediate medical management usually consist of covering the extruding viscera with sterile silicon gauze surrounded by an occlusive dressing to prevent air contact and dehydration, fluid and electrolyte balance and antibiotic prophylaxis if indicated [2]. Surgical correction varies depending on the type and severity of the defect. Currently, a staged approach is the strategy most commonly used. In the standard-staged repair, a primary closure of the bladder without osteotomy, and without genital reconstruction in males, is attempted in the first 72 hours of life; between 6 and 12 months of age, the epispadias repair is performed in males.

Bladder neck reconstruction follows around the age of 5 years, if a reasonable bladder capacity is reached [5]. Alternatively, the neonatal primary complete repair and the deferred primary complete repair have been proposed [14]. Our patient benefited from the immediate medical management consisting of hospitalisation in the neonatal unit, covering the extruded viscera with wet gauze and fluid resuscitation. We did not give antibiotics. While the surgical team had been mobilised, for closure of the defect, the mother opted to go home against medical advice. This discharge against medical advice can be explained by the low socioeconomic status of the mother, financial constraints, refusal of the surgical intervention, and lack of confidence in the health care system which may all have contributed to her leaving the hospital to seek alternative treatment (traditional medicine).

CONCLUSION

BEEC is a rare congenital malformation. Even in the era of highly advanced information technology, the prenatal diagnosis of congenital malformations remains a challenge. Radiologists doing prenatal ultrasounds should check routinely to exclude foetal anomalies. The management of BEEC is multidisciplinary.

Declarations

Ethics approval and consent to participate: Ethical

approval was obtained from the ethical committee of Douala general hospital. A copy is available for review upon request by the Editor-in-Chief of this journal

Consent for publication: Obtained from the patient’s mother

Availability of data and material: The datasets (details of all results) are available from the corresponding author on reasonable request by the editor – in – chief. The file of the patient is in Douala general hospital.

Competing interests: “The authors declare that they have no competing interests” in this section.

Funding: None

Author’s contributions: GEH followed up the patient during pregnancy, PNT and GEH managed the patient during labour and postpartum, PNT wrote the initial draft of the manuscript, EY, CN, GEH and AMC corrected the initial manuscript, all authors approved the final manuscript and are responsible for it.

Acknowledgement: We express our sincere gratitude to all staff and medical students who took care of the patient.

References

1. Stec AA. Embryology and bony and pelvic floor anatomy in the bladder exstrophy-epispadias complex. *Semin Pediatr Surg.* 2011 May; 20(2):66–70.
2. Valerio E, Vanzo V, Zaramella P, Salvadori S, Castagnetti M, Baraldi E. Exstrophy–Epispadias Complex in a newborn: Case report and review of the literature. *AJP Rep.* 2015 Oct;5(2):e183–e187.
3. Nelson CP, Dunn RL, Wei JT. Contemporary epidemiology of bladder exstrophy in the United States. *J Urol* 2005 May;173(5):1728–31.
4. Nerli RB, Kamat GV, Alur SS, Koura A, Prabha

- V, Amarkhed SS. Bladder exstrophy in adulthood. *Indian J Urol.* 2008;24(2):164–8.
5. Inouye BM, Turchi A, Di Carlo HN, Young EE, Gearhart JP. Modern management of the xstrophy-epispadias complex. *Surg Res Pr.* [Internet]. 2014. <http://www.ncbi.nlm.nih.gov/pmc/articles/PMC4208497>
 6. Frimberger D. Diagnosis and management of epispadias. *Semin Pediatr Surg.* 2011 May;20(2):85–90.
 7. Bethell G, Johal N, Cuckow P. Cloacal exstrophy repair with primary closure of bladder exstrophy: a case report and review of literature. *Case Reports Pediatr.* [Internet]. 2016 <http://www.ncbi.nlm.nih.gov/pmc/articles/PMC4893573>
 8. Kulkarni B, Chaudhari N. Embryogenesis of bladder exstrophy: A new hypothesis. *J Indian Assoc Pediatr Surg.* 2008;13(2):57–60.
 9. Pierre K, Borer J, Phelps A, Chow JS. Bladder exstrophy: current management and postoperative imaging. *Pediatr Radiol.* 2014 July;44(7):768–786; quiz 765–767.
 10. Ebert A-K, Reutter H, Ludwig M, Rösch WH. The exstrophy-epispadias complex. *Orphanet J Rare Dis* 2009 Oct;4:23.
 11. Furtos C, Chene G, Varlet M-N, Varlet F, Seffert P, Chauleur C. Prenatal diagnosis and management of isolated bladder exstrophy. *Gynecol Obstet Fertil* 2010 Oct;38(10):624–30.
 12. Skari H, Bjornland K, Bjornstad-Ostensen A, Haugen G, Emblem R. Consequences of prenatal ultrasound diagnosis: a preliminary report on neonates with congenital malformations. *Acta Obstet Gynecol Scand* 1998 Jul; 77(6):635–42.
 13. Gearhart JP, Ben-Chaim J, Jeffs RD, Sanders RC. Criteria for the prenatal diagnosis of classic bladder exstrophy. *Obstet Gynecol* 1995 Jun;85(6):961–4.
 14. Massanyi EZ, Gearhart JP, Kost-Byerly S. Perioperative management of classic bladder exstrophy. *Res Reports Urol* 2013;5:67–75.