

# Inhaled foreign body mismanaged as TB, finally removed using a rigid bronchoscopy after 6 years of impaction

Justin Rubena Lumaya and Mubarak Mohammed

Residents Otolaryngology, Makerere University, Kampala, Uganda

Correspondence to: Justin Rubena Lumaya [lugela4@yahoo.com](mailto:lugela4@yahoo.com)

Foreign body aspiration is an important cause of mortality in children aged less than three years. Foreign body (FB) inhalation can pose diagnostic and therapeutic challenges, especially in longstanding cases and complications such as recurrent pneumonia, lung collapse and lung abscess may develop. We report a case of an 11-year old boy with foreign body impacted in his bronchus for six years, which was mistakenly managed as pulmonary tuberculosis. Radiological evidence confirmed the diagnosis and a rigid bronchoscopy was used to remove the metallic foreign body.

The standard of care for the management of a FB in a bronchus is a rigid bronchoscopy; however flexible bronchoscopy can be used, especially in adults. A thorough history with radiological evidence are essential and sometimes, followed by a diagnostic bronchoscopy.

**KEY WORDS:** *bronchus, foreign body aspiration, metallic foreign body, radiological evidence, rigid bronchoscopy.*

## Introduction

Foreign body aspiration (FBA) is one of the leading causes of sudden death among children aged less than three years [1]. Aspiration is common in this age group because of the less effective and protective mechanisms involved in coordination of breathing and swallowing [2]. FBA resembles a number of pulmonary diseases and so poses a great challenge to clinicians for its management [3]. The diagnosis depends on a history of sudden cough, difficulty in breathing, and/or stridor in an otherwise healthy child. Rigid bronchoscopy is the standard of care for both diagnostic and therapeutic purposes [4].

## Case Report

### History and examination

An 11-year old boy was referred from a nearby district to Mulago National Referral Hospital on the 9th October 2015 with a history of recurrent chest infections. It was reported that 6 six years ago there was a sudden onset of cough, intermittent fever, noisy breathing (wheezing), difficulty in breathing, and chest pain. However there were no night sweats, weight loss or contact with a tuberculosis patient. The boy was admitted to a district hospital several times over this period for different diagnoses such as severe pneumonia, asthma for which he had received antibiotics, steroids, bronchodilators and expectorants. The last admission before referral was in August 2014 when he was investigated for tuberculosis, Acid Alcohol Fast Bacillus (which was negative), chest X-ray, and HIV (negative).

Examination: Young boy; well nourished; not wasted, pale, jaundiced or distressed. He had digital clubbing with a single, non-tender, 3 x 2cm mobile soft left cervical lymph node enlargement level III (middle jugulo-diagastric); no lower limb oedema. Weight = 32kg; temperature = 36.8C; respiratory rate =20; SPO2 = 94%.

### Chest findings

Asymmetrical chest movements without obvious deformity, trachea slightly deviated to the left with a dull percussion note and reduced breath sounds.

### Cardiovascular System

BP=100/60; PR=80; Apex beat 4th ICS, slightly displaced laterally from mid-clavicular line, Heart sounds normal.

### Previous treatment

In August 2014 he had been started on anti-tuberculosis treatment and a slight clinical improvement over a month was reported despite no radiological changes. Anti-tuberculosis treatment had been continued for 8 months (until April 2015) after which he had been referred to Mulago National Hospital as a case of multi-drug-resistant tuberculosis.

### Investigations at Mulago TB Department

These revealed a foreign body (FB) impacted in the distal left main bronchus. Figure 1 shows and describes the pre-admission X-ray findings, and Figure 2 the CT scans.

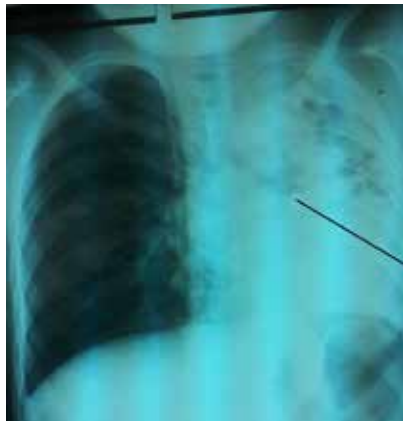

Figure 1. Pre-admission X-ray shows homogenous opacity in the left lung especially the lower lobe (Silhouette sign), foreign body (arrowed) appeared radio-opaque in the distal end of left main bronchus. There is a left mediastinal shift and compensatory hyperinflation of the right lung. Evidence of left lower lung atelectasis and upper left lobe multiple consolidations.

The cardiothoracic (CT) surgeons and Ear, Nose and Throat (ENT) surgeons were consulted for further management.

**Management**

The cardio-thoracic surgeons reviewed and put the patient on antibiotics (cefixime 200mg daily) expectorants (Brozedex Syrup [bromhexine hydrochloride, terbutaline sulphate, menthol]) and steroids (dexamthasone in 8mg – 2 divided doses). Initially the plan was to do a left sided lobectomy based on the findings on the images and the long history.

The ENT surgeons’ opinion was to do a rigid bronchoscopy, which was done on the 22nd October 2015. The first attempt was unsuccessful due to bleeding following removal of granulation tissue and mucus accumulation which covered the FB in the distal end of the left main bronchus – see Figure 3.

The patient was put on steroids and antibiotics for another four days giving a total of 2 weeks. A second

attempt was carried out successfully on the 26th October 2015 and the metallic end of a pencil and its rubber were discovered– see Figures 4 and 5. The patient was discharged in the fourth postoperative day. There was marked clinical and radiological improvement.

**Discussion**

FBA is common among children and 73-80% of cases are diagnosed from history alone. The lapse between aspiration and diagnosis can vary from days to several months and even years [1]. This is seen in our case where the metallic FB was impacted for almost six years.

In the United States, until 1986, 7% of sudden deaths in children aged under four years old were directly linked to FBA. Approximately 75% to 85% of all FBAs occur in children younger than 15 years old; however, it is most common in children aged less than three years [5].

Children are more prone to FBA due to their tendency to place objects in their mouths, to have less developed protective reflex coordination between swallowing and inhalation, and also because they have a high incidence of upper respiratory tract infections (which makes them mouth breathers, and therefore take deep inhalations during coughing [2]).

Males are affected more frequently than females due to their greater physical activity [6]. Studies have shown that the most common types of FBA inhaled are organic materials like nuts, vegetables and seeds, while inorganic materials (e.g. metallic) constitute 4.4% of objects [7]. The foreign body in our case was an inorganic material (metallic top of a pencil and its rubber).

FB inhalation can pose diagnostic and therapeutic challenges and can be life-threatening if not properly managed [8]. Unsuspected longstanding cases may lead to complications such as recurrent pneumonia, bronchiectasis, atelectasis, and lung abscess [2]. FBA can mimic other pulmonary diseases with similar presentation and this may lead to misdiagnosis in about one fifth of cases [3], as occurred in this case where the patient had been managed as for pulmonary tuberculosis.

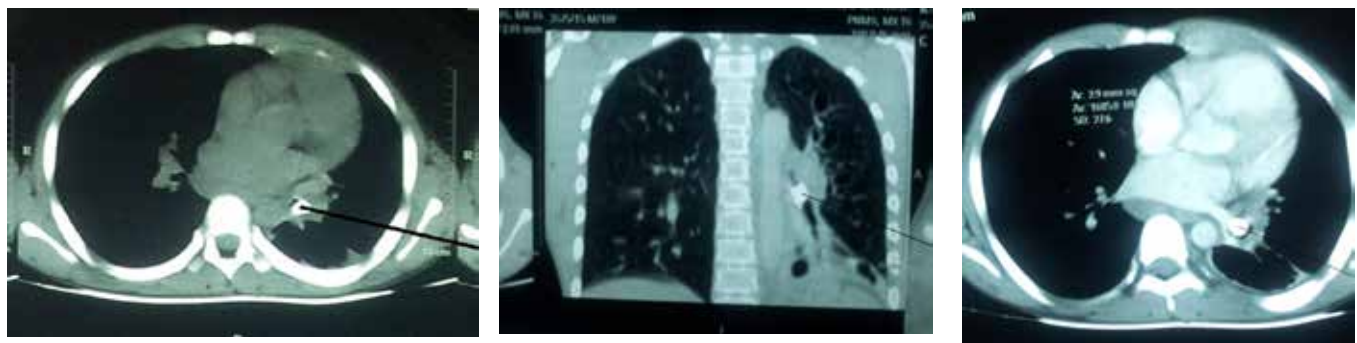


Figure 2a, b, c. CT-Scan findings before intervention (bronchoscopy). Showing evidence of hyper-inflated right lung, left lower lobe atelectasis, mediastinal shift and a clear radio-opaque foreign body in the left main (arrowed) bronchus.

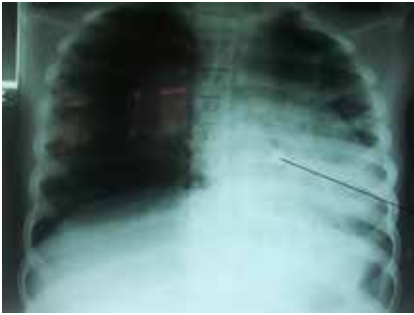

Figure 3. Post-operation X-ray after the first bronchoscopy. The foreign body (arrowed) is more visible in the distal end of the left main bronchus; despite the failed attempt there is evidence of better left upper lobe aeration compared to the pre-admission image.

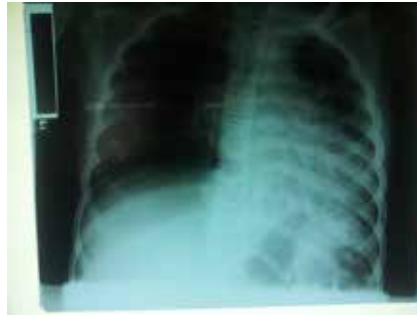

Figure 4. Post-operation X-ray after second bronchoscopy. The removal of the foreign body resulted in better left lung tissue aeration and reduced right lung hyperinflation.



Figure 5. Metallic top of a pencil and the rubber removed from the distal end of the left main bronchus.

### Pathophysiology

FB can lodge with equal frequencies in the right or left main bronchus because the angle of bifurcation of the trachea is the same in children (<15 years) [9]. As a result of FB impaction local inflammation, oedema, with cellular infiltration and granulation may form, which further compromise the airway. These pathological changes make it difficult to extract the FB due to bleeding and poor field visibility, which lessens the chance of successful removal at first attempt [10]. In our case, removal of the FB was successful in the second attempt. It was noticed radiologically that aeration had greatly improved at the lung apex compared to the first chest X-ray after the first bronchoscopy despite failure to remove the FB. This can be attributed to the fact that some granulation tissues had been removed and suction of all the mucus accumulation partially opened the bronchial tree.

Clinicians should be alert to the possibility of a FB especially in those cases with a vague history but yet positive clinical signs [4].

The systematic algorithm for diagnosis should start from a witness report, history of sudden cough, difficulty in breathing, stridor, wheezing and cyanosis in an otherwise healthy child. In a long standing FBA the symptoms will be of delayed presentation with persistent cough or wheezing, recurrent or non-resolving pneumonia or, rarely, pneumothorax. Radiography (chest X-ray) has a low sensitivity and specificity in cases of translucent materials - however signs of emphysema and air trapping, atelectasis, infiltration and mediastinal shift may be seen in longstanding cases. A CT-scan is better at detecting metallic objects compared to plain X-ray but it is less useful in detecting organic material (translucent materials)[11]. Hence a negative CT-scan does not exclude an inhaled organic FB.

Management of FBA using a rigid bronchoscope is accepted as a gold standard for both diagnostic and therapeutic use. C.J.Killian (1887) was the first to do bronchoscopy to remove a FB (a bone) from the right main bronchus. It is easier to remove large volumes of granulation tissue which may (as in this case) develop around and even hide the foreign body; it is also easier to control the airway and bleeding. Flexible bronchoscopy can however be used, especially in adults [4]. The outcome depends on several factors including the patient's age, FB type, time of diagnosis, skills of the surgeon and anaesthetist, and availability of instruments [12].

### Conclusion

FBA is a very common presentation among children and a high index of suspicion is warranted especially when treating children with recurrent or non-resolving pneumonia. Failure to diagnose and remove FB may result into serious complications such as asphyxia, recurrent pneumonia, bronchiectasis, atelectasis and lung abscess in long standing cases. It is therefore important to gather a good history, radiological evidence, and sometimes, do a diagnostic bronchoscopy. Accurate and early diagnosis is crucial to prevent life threatening complications.

**Conflict of interest:** None

**Consent:** The parent consented for the case to be published.

**Authors' contributions:** JR received and assessed the patient, did the two bronchoscopies, did the literature review, and followed up the patient. MM assisted in the bronchoscopy and participated in literature review.

**Acknowledgement:** We appreciate the efforts of our nurses and colleagues in the department who participated in treatment of the patient.

References

1. Tenjovi D, et al. Clinical and radiological characteristics of unrecognized foreign body aspiration into respiratory tract in children. *Medicinski pregled* 2013; 66(5-6): 214-219.
2. Rajasekaran S. et al. Management of tracheo bronchial foreign bodies in children—a retrospective study of series of 50 cases. *Otolaryngology online journal* 2013; 3(3):14-25.
3. Petrovic S. et al. Foreign body aspiration in children - a diagnostic challenge. *Balkan Med J* 2012; 29(1): 096-8.
4. Hada MS. et al. “Slam Dunk”: A case report of an unusual metallic foreign body. *Journal of Bronchology and Interventional Pulmonology* 2012; 19(2):156-158.
5. Mantor PC, Tuggle DW, Tunell WP. An appropriate negative bronchoscopy rate in suspected foreign body aspiration. *American Journal of Surgery* 1989; 158(6):622-624.
6. Marquette C-H, Martinot A. Foreign body removal in adults and children. In Bolliger CT, Mathur PN (eds): *Interventional Bronchoscopy. Prog Respir Res. Basel, Karger* 2000, vol. 30, 96-107.
7. Shad R, Agarwal A. Broken safety pin in bronchus - anaesthetic considerations. *Indian Journal of Anaesthesia* 2012; 56(6):570.
8. Panda SS. et al. Foreign body in the bronchus in children: 22 years’ experience in a tertiary care paediatric centre. *African Journal of Paediatric Surgery* 2014; 11(3):252.
9. Cleveland RH. Symmetry of bronchial angles in children 1. *Radiology* 1979; 133(1):89-93.
10. Debeljak A, Kecelj P. Bronchoscopic removal of foreign bodies in adults: experience with 62 patients from 1974–1998. *European Respiratory Journal* 1999; 14(4):792-795.
11. Fidkowski CW, Zheng H, Firth PG. The anesthetic considerations of tracheobronchial foreign bodies in children: a literature review of 12,979 cases. *Anesthesia & Analgesia* 2010; 111(4):1016-1025.
12. Farrell PT. Rigid bronchoscopy for foreign body removal: anaesthesia and ventilation. *Pediatric Anesthesia* 2004; 14(1):84-89.