

Case study: sarcoidosis

Andrew Woolley^a, Michaela Lynn^b and Neena Singh^b

^a Consultant Respiratory Physician, St Mary's Hospital, Isle of Wight, UK

^b Foundation Year 1 doctors; St Mary's Hospital, Isle of Wight, UK

Correspondence: Michaela Lynn kaelalynn83@hotmail.com

Introduction

Sarcoidosis is a multisystem granulomatous disease of unknown cause. It occurs worldwide but there are higher incidences in certain racial groups, being three to four times more common in African-Americans [1]. It can also aggregate in families. Most patients do not need treatment and the disease often regresses spontaneously, but a minority have potentially life-threatening progressive organ dysfunction; these patients need active management including oral corticosteroids. The poorest prognosis, in terms of chronicity and fatality, is for African Americans [2]. This case illustrates that acute sarcoidosis can be a difficult diagnosis to make.

Clinical assessment

A 59 year old man of white Australian origin, who had been living in the UK for the last 35 years, presented to the medical admission unit of our hospital with a cough, rash and pyrexia. The cough had been present for 3 months, increasing over the preceding 2 weeks, and was productive of clear sputum. He gave a 10 day history of an erythematous rash which involved all four limbs and the upper trunk, sparing the palms and soles. The patient also complained of widespread arthralgia, with variable joint swelling, tenderness and stiffness. There was no history of night sweats, weight loss or haemoptysis. His past medical history included fusion of the left ankle joint following an injury at the age of fifteen; he was otherwise fit and well. He was not on any regular medications and had no known drug allergies. He drank alcohol occasionally and had never smoked. He worked as an engineer. His last overseas travel was to the Australian outback in Queensland four years previously. He had no pets or significant animal exposure and no recent insect bites.

On examination, his temperature was 37.3 °C and other observations were normal. There were no added heart sounds and vesicular breath sounds were heard throughout. There was bilateral pedal pitting oedema to below knee level. There were no peripheral stigmata of vasculitis or palpable lymphadenopathy present. The abdomen was soft and non-tender with no organomegaly or palpable masses. The neurological examination was unremarkable. There was bilateral conjunctival injection. Dermatological

Table 1. Blood results on admission

Description	Value	Range
Haemoglobin	155g/l	135-185
MCV	86 fl	78-100
Platelets	289 x109/l	140-400
Haemoglobin	155g/l	135-185
MCV	86 fl	78-100
Platelets	289 x109/l	140-400
White cell count	10.9x 109/l	4.0-11.0
Neutrophils	8.6 x109/l	2.0-7.5
Lymphocytes	1.1 x109/l	1.0-3.5
Urea	3.7 mmol/l	2.5-7.8
Sodium	132 mmol/l	133-146
Potassium	4.3 mmol/l	3.5-5.3
Chloride	93 mmol/l	95-108
Creatinine	82 µmol/l	60-110
Estimated GFR	89 mL/min/1.73m ²	>90
CRP	174.9 mg/l	0.0-5.0
Calcium	2.26 mmol/l	2.20-2.60
Phosphate	1.14 mmol/l	0.80-1.50
Adjusted Calcium	2.39 mmol/l	2.20-2.60
Tot. Bilirubin	12 µmol/l	<21
Alkaline Phosphatase	95 U/L	30-130
Total Protein	78 g/l	60-80
Albumin	37 g/l	35-50
Globulin	41 g/l	20-40
Alanine Aminotransferase	45 U/L	<40

examination revealed multiple 1-2 mm erythematous macules on the arms, legs and upper trunk. There was a marked erythematous area on the right ankle and a firm tender swelling with surrounding erythema just distal to the left elbow. The latter had developed spontaneously on the day of admission.

During the following 30 days of the patient being in

hospital, he spiked temperatures daily, ranging from 37.3°C to 38.6°C. He also complained of widespread arthralgia, reporting variable joint swelling. Towards the end of his admission, the patient developed multiple, red, round, warm nodules on the postero-medial aspects of the lower limbs, reminiscent of erythema nodosum.

Investigations

Initial Investigations

Routine bloods tests revealed a mildly raised neutrophil count and an elevated CRP. Renal function was not impaired and all electrolytes were within the normal range. Bone profile was stable – see Table 1.

ECG showed left axis deviation. Urinalysis was negative for nitrites, leucocytes and blood. Repeated blood and sputum cultures showed no growth. Auramine stain was negative.

Specific Investigations

In view of the history of travel in the Australian outback, relevant infectious diseases were investigated: Malarial screen, ASO titre, HIV and serology for Brucella, Chikungunya virus, Cytomegalovirus (CMV), Dengue virus, Epstein–Barr virus (EBV), Hepatitis B surface antigen, Hepatitis C antibody, Lyme, Mycoplasma, Orientatsutsugamushi, Q fever, Ross River Fever, Spotted fever and Syphilis but all were negative. Other immunological and biochemical investigations were unremarkable – see Tables 2 and 3.

The chest radiograph did not show any evidence of infection and was thought to be normal – see Figure 1.

CT of the chest/abdomen/pelvis showed widespread lymph node enlargement throughout the mediastinum, suggesting possible sarcoidosis – see Figure 2.

Histology

Endobronchial ultrasound (EBUS) guided needle aspiration of the sub-carinal lymph node showed large numbers of lymphocytes and scattered histocytes with no malignant cells or well-formed granulomas.

Biopsy of the skin lesions was considered but they were beginning to resolve before this could be done.

Differential diagnosis

Initial working diagnosis was cellulitis of the right leg. Septic arthritis of the right ankle was excluded by the Orthopaedic team.

Differential diagnoses could be categorised into four broad areas:

Table 2. Immunology

Description	Value	Range
ANA	Ratio 2.4	< 1.0
ANCA	Negative	
Rheumatoid factor	57 IU/ml	0-25

Table 3. Chemical Pathology

Description	Value	Range
ESR	70 mm/hr	
Protein electrophoresis	Inflammatory response	
Serum IgA	2.73 g/l	0.80-4.00
Serum IgG	13.77 g/l	5.30-16.50
Serum IgM	0.80 g/l	0.50-2.00
INR	1.0	0.8-1.2
Beta-2 microglobulin	3.3 mg/l	1.2-2.4
LDH	499 IU/l	225-425
CA 19-9	32 KU/L	0-35
CEA	0.9 µg/l	0.0-2.5
AFP	1.2 KU/L	0.0-10.0

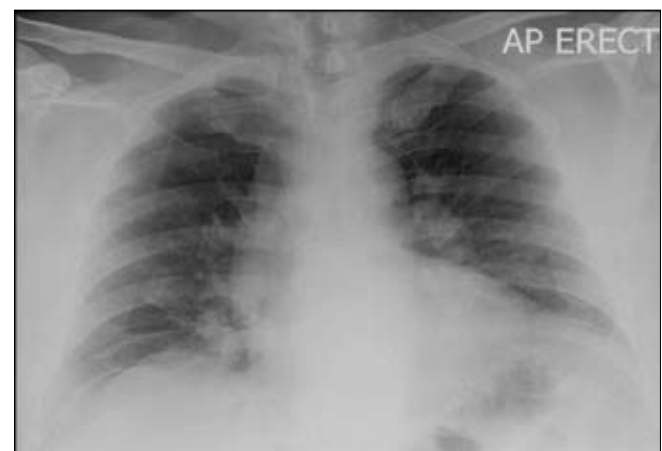


Figure 1. Anterior-posterior chest radiograph

1. Infections including demographic specific infections; bacterial infections including TB, Rheumatic fever, mycoplasma and typhoid; viral infections including HIV, EBV, CMV and hepatitis
2. Immune-mediated causes including sarcoidosis, vasculitis, SLE, reactive arthritis, psoriatic arthritis and amyloidosis
3. Malignancy including lymphoma, leukemia and metastatic cancer
4. Other causes of unexplained pyrexia such as

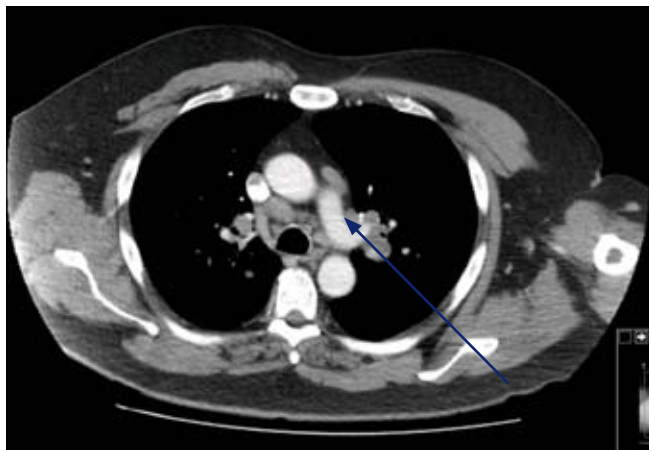

Figure 2. CT chest/abdomen/pelvis with contrast

abscess, haematoma, drug fever, pulmonary emboli, hyperthyroidism and sub-acute thyroiditis

Following the CT result, the patient was referred to the Respiratory team. A diagnosis of probable sarcoidosis was made. This was investigated by an EBUS guided needle aspiration which was performed in a regional tertiary hospital.

Treatment and Progress

Initial treatment was with flucloxacillin for cellulitis. However, the progression of the rash from the lower legs to the thighs, the bilateral swelling of the elbows and the development of tender red nodules, raised a concern that he had had a reaction to the antibiotic. This in conjunction with the ongoing pyrexia and elevated CRP (see graphs 1 and 2) prompted a switch to second line antibiotics (doxycycline), although this was not associated with any change in these outcomes.

Following a review by the Respiratory Team, antibiotic treatment was stopped and this did not cause any deterioration in the patient’s clinical state. Treatment with steroids was withheld until a histological diagnosis could

be made. The EBUS lymph node aspiration cytology was supportive of the diagnosis of sarcoidosis. He was referred to an Ophthalmologist, as per American Thoracic Society guidelines [3], who diagnosed ocular hypertension but did not find any evidence of uveitis or visual impairment.

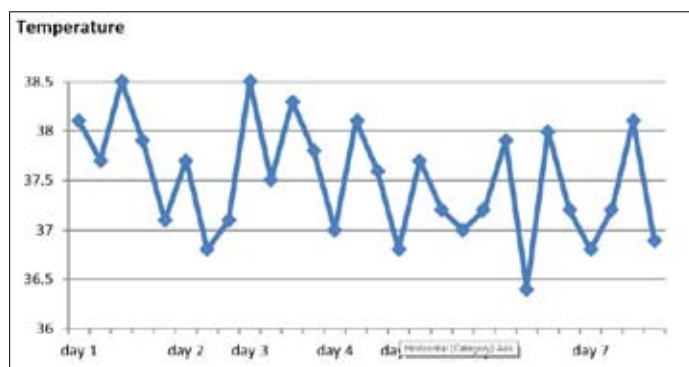
The patient was booked for an urgent follow-up outpatient appointment to discuss findings, prognosis and treatment options. At follow-up 2 months after discharge, he was asymptomatic and on no treatment.

Comment

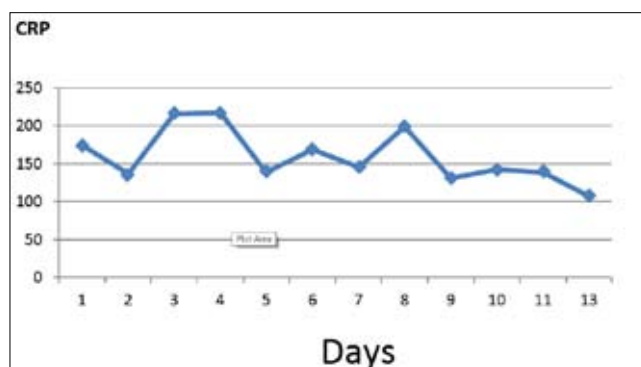
Pyrexia of unknown origin (PUO) was first defined in 1961 as a temperature greater than 38.3°C on several occasions, accompanied by more than three weeks of illness and a failure to reach a diagnosis after one week of inpatient investigation [4]. In adults, infections, cancer and autoimmune disorders account for most PUOs. However, drug fever, granulomatous diseases-including sarcoidosis, vasculitides, pulmonary emboli, hyperthyroidism and subacute thyroiditis are other important causes.

Erythema nodosum (EN) is characterized by purple or red, tender nodules, which can occur anywhere but are usually on the anterior aspect of the lower leg. Accompanying arthralgia occurs in more than half of patients. Streptococcal infection is the most common underlying cause. Granulomatous diseases, including sarcoidosis and tuberculosis must be considered. EN may correlate with a flare-up of Crohn’s disease or ulcerative colitis. It can precede the diagnosis of Hodgkin’s lymphoma and non-Hodgkin’s lymphoma. It can be drug induced. In many cases no cause is found.

Bilateral hilar lymph node enlargement can be a feature of infection (particularly fungal or mycobacterial organisms) or malignancy (e.g. lymphoma). However bilateral hilar lymphadenopathy is the most common radiological finding in sarcoidosis [5]; this should therefore remain high on the differential diagnosis list.



Graph 1. Fluctuating temperatures during admission



Graph 2. Fluctuating CRP during admission

With hindsight, the pattern of clinical features including pyrexia, erythema nodosum and bilateral hilar lymphadenopathy were highly suggestive of a clinical diagnosis of sarcoidosis. A good quality postero-anterior radiograph on admission to hospital may have brought the diagnosis to light much earlier.

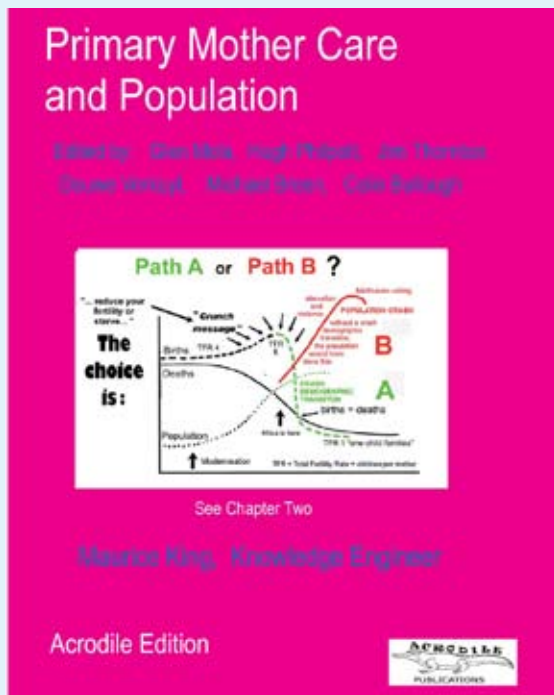
References

1. Thomas K.W. and Hunninghake G.W. 2003 Sarcoidosis. *JAMA*; 289(24):3300-3303
2. Annuzzi M.C., Rybicki B.A. and Teirstein A.S. 2007

- Sarcoidosis *New England Journal of Medicine*;357(21):2153-65
3. American Thoracic Society. Statement on Sarcoidosis. 1999. *American Journal of Respiratory and Critical Care Medicine*;160:736-55
4. Petersdorf R.G. and Beeson P.B. 1961 Fever of unexplained origin: report on 100 cases. *Medicine (Baltimore)* Feb; 40:1-30.
5. Hyun J. P., Jung I.J., Myung H. C., Sun W. S., Hyo L. M., Jun H. B., Dae H. H., Ki J. K., and Kyo-Young L. 2009 Typical and Atypical Manifestations of Intrathoracic Sarcoidosis. *Korean Journal of Radiology* Nov-Dec; 10(6): 623-631.

‘PRIMARY MOTHER CARE AND POPULATION’

Authors: Glen Mola, Jim Thornton, Michael Breen, Colin Bullough, Hugh Philpott, Douwe Verkuyl, Priscilla Busynge, and Maurice King



“This book should be in every health unit in Africa”, so said a highly critical and long experienced doctor and aid worker of an earlier edition. Its purpose is to stop mothers dying and to reduce Africa’s maternal mortality. Although primarily intended for ‘the better educated midwives’, it should be useful for the less educated ones, and indeed for the more enquiring members of the general public. It is also highly suitable for medical students, and indeed

for trainee consultant obstetricians, since their cadres are presently becoming deskilled in Africa. We constantly have in our minds the isolated midwife who is trying to do her first destructive operation ‘out of the book’ on a mother with obstructed labour in the middle of the night, never having done one before.

We describe all the family planning methods in detail, including particularly the postcoital ones. The novel feature of the book is however its second chapter “How many children?” which deals with the problem of communities exceeding the carrying capacity of their local ecosystems. This is ‘demographic entrapment’, which requires an immediate reduction of fertility, in ‘a crash demographic transition’. Since demographic entrapment is tightly taboo to demography, development economics and the UN agencies and NGOs, this chapter breaks entirely new ground. We hope it will be a growing point for future ‘community disentrainment programs’.

The book is large with 28 chapters, two million words, and several pictures on almost every page. It is problem oriented, with detailed instructions as to how to deal with every difficulty that we have ever been able to find. The introduction contains a glossary of all technical terms in narrative form.

It was put together in an unusual way, over many thousands of hours, by a doctor who is not an obstetrician, putting himself in the position of the reader and then finding out what he should do and know. To reduce its cost, it is published without royalty, for the love of Africa. The book can be purchased from Kennedy Chadeka, Acrodile Publishing Ltd, Nairobi, Kenya. www.acrodile.co.ke

Note the above review was provided by the publisher and does not necessarily reflect the opinion of SSMJ.