

Hepatitis E Virus

Christina Levick^a

^a Post Gastroenterology Specialty Registrar, Queen Alexandra Hospital, Portsmouth, UK

Correspondence: christina.levick@gmail.com

Abstract

Hepatitis E virus (HEV) is the most common cause of acute viral hepatitis in the developing world. It is a waterborne virus that can cause epidemics in the face of overcrowding and poor sanitation. Although the hepatitis illness is usually self-limiting, it has a high mortality in pregnant women and can become a chronic infection in the immunosuppressed. Treatment is mostly supportive and prevention is by good water hygiene.

Introduction

Before the discovery of hepatitis E virus (HEV), many epidemics of hepatitis in the developing world were found to be from a cause other than the known hepatitis A, B and C viruses. HEV was discovered in 1983 in the stool samples of a human volunteer infected with the combined stool samples of patients with non-A, non-B hepatitis (Balayan et al., 1983). HEV is a small single-stranded RNA virus spread by contaminated water.

Epidemiology

HEV is the most common cause of clinical hepatitis in many countries in Africa, including South Sudan, and Asia. There are four known genotypes of HEV that can infect humans (Smith et al. 2013). Figure 1 illustrates the prevalence of the different HEV genotypes across the world. It should be noted that there may be some inaccuracy in the epidemiology of HEV due to the variation in the sensitivity of various anti-HEV IgG testing kits and the lack of standardization of testing (Zhou et al., 2013).

Genotypes 1 and 2 affect humans alone. They are transmitted via the faecal-oral route and survive in water. Consequently, the places of highest prevalence are areas of over crowding and poor sanitation (Hazam et al., 2010). They are endemic in the developing world, with genotype 1 being the most common cause of HEV outbreaks. Notable outbreaks include the refugee camps in Maban County, South Sudan, 2012.

Genotypes 3 and 4 affect humans and animals e.g. pigs, game. These genotypes are most commonly seen in the developed world, although low level prevalence of genotype 3 HEV has been found in locally farmed pigs in Cameroon (S de Paula et al., 2013). They are transmitted across species by consuming the raw or undercooked

meat of an infected animal (Tei et al., 2003, Emerson et al., 2005). Transmission may also occur rarely between humans. This has been documented by blood transfusions (Matsubayashi, 2004).

A further two more genotypes have been discovered that do not affect humans, but can infect wild boar (Smith et al., 2013).

Acute HEV infection

HEV infection can range from asymptomatic to fulminant hepatitis. The incubation period from infection to symptoms ranges from two to eight weeks (Purcell and Emerson, 2008). Symptoms include fever, fatigue, myalgia, arthralgia, weakness, vomiting, jaundice, pale stools and dark urine. Neurological symptoms, e.g. from peripheral neuropathy, may also occur (Kamar et al, 2011). Blood tests reveal raised liver transaminases, alkaline phosphatase, γ -glutamyltransferase and bilirubin.

Acute HEV infection can be diagnosed by the presence of anti-HEV IgM, whilst IgG suggests past infection. Due to the wide variation in the accuracy of serological testing, viral Polymerase Chain Reaction (PCR) should be used to confirm the diagnosis (Drobenuic et al., 2010).

In HEV endemic areas where HEV genotype 1 predominates, only 20% of HEV infections produce symptomatic hepatitis. HEV infection rarely causes clinical symptoms in children (Buti et al., 2008), in contrast to pregnant women who have the highest risk of symptomatic hepatitis.

Pregnant women are a particularly susceptible group to HEV transmission, symptomatic infection and mortality. Mortality is 2% if not pregnant and 20% if pregnant (Rein et al., 2012). This mortality risk is most pronounced in the 3rd trimester when the mortality approaches 31% (Guthmann et al., 2006). The risk of contracting acute HEV infection is increased by HIV infection in pregnancy (Caron et al., 2012).

Pre-existing liver disease increases the risk of fulminant hepatitis. The mortality from HEV genotype 1 infection as a cause of decompensation of chronic liver disease is almost 70%, which is considerably higher than other causes of decompensation (Kumar et al., 2004).

HEV infection only produces one symptomatic episode

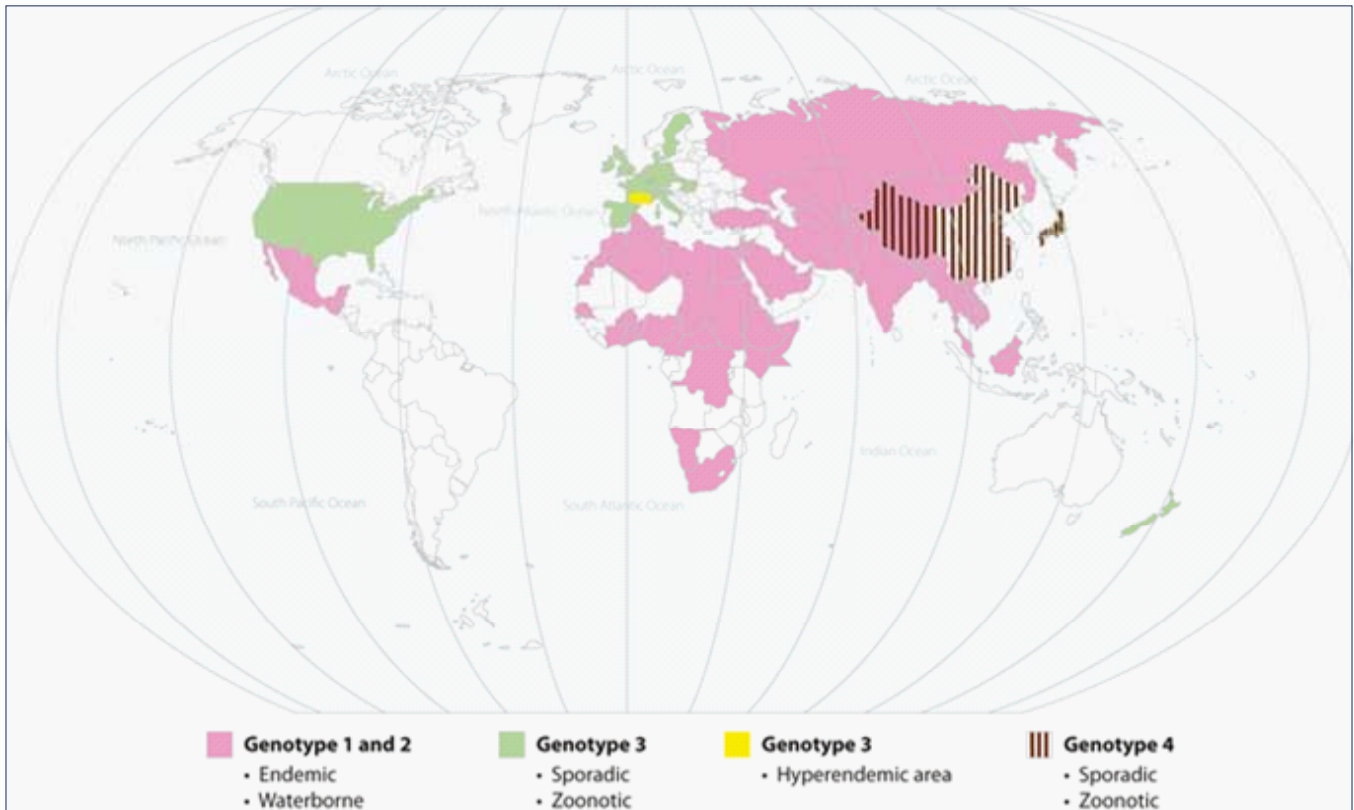


Figure 1. Geographic distribution of human cases of Hepatitis E (Reprinted from *The Lancet*; 379(9835), Kamar et al., 2477–2488, Hepatitis E, Copyright 2012, with permission from Elsevier)

due to the generation of anti-HEV IgG antibodies.

Chronic HEV

In the majority of cases acute HEV infection will be cleared. An immunocompromised status may lead to the persistence of the virus and chronic HEV infection. This is particularly the case for patients with HIV (Dalton et al., 2009), organ transplants (Kamar et al., 2008) and haematological malignancy. HEV infection in this group is more difficult to confirm as the standard antibody testing for HEV infection is unreliable due to the underlying immunocompromise and so direct molecular assays should be used. To date, only genotype 3 HEV has been shown to cause chronic infection.

Treatment

HEV infection is usually self-limiting and so only supportive treatment is needed. Severe infection can be treated with ribavirin, although ribavirin is contraindicated in pregnancy due to teratogenicity and fetal loss. The approach to treating chronic infection in transplant patients is first to reduce the immunosuppression to allow clearance by the host (Kamar et al., 2010), then to treat with ribavirin and/or pegylated alpha interferon for three months if infection remains (Scobie and Dalton, 2013).

Prevention and Vaccine

The main way to prevent HEV infection in developing countries is by maintaining good hygiene and to supply a safe water source. Chlorination of water has not been shown to inactivate HEV (Guthmann et al., 2006), but boiling water will kill the virus (Emerson et al., 2005).

Human and animal studies have shown the development of antibodies to HEV post infection that protect against re-infection (Bryan et al., 1994, Tsarev et al., 1994). Following subsequent work, two HEV vaccines have been developed.

The HEV 239 vaccine (Hecolin®) was shown to induce immediate immunity to HEV following two doses within one month with 100% efficacy against symptomatic HEV, lasting five months until the third dose (Shrestha et al., 2007). This supports its use in limiting an outbreak of HEV. No adverse effects of the vaccine have been observed in pregnancy (Wu et al., 2012) and its efficacy and safety have been confirmed in a phase III trial (Zhu et al., 2010). Pregnant women or women of childbearing age could be targeted for vaccination in the face of limited resources. The HEV 239 vaccine is currently licensed for use in China, but unfortunately is not part of the WHO priority vaccines.

Comparison with hepatitis A virus

There are many similarities between HEV and hepatitis A virus (HAV). Both HEV and hepatitis A virus (HAV) are enteric viruses spread by contaminated water. HAV is only found to infect human and non-human primates, whereas HEV has a wide variety of zoonotic hosts, depending on its genotype (Purcell et al., 2008). The clinical presentation of HEV is very similar to that of HAV. There are only a few contrasting points. The incubation period of HEV is roughly ten days longer than that of HAV. The severity of disease and mortality tends to increase with age for HAV, whereas age has no bearing on HEV mortality. HEV does however, have a high mortality in pregnant women that is not seen in HAV. Finally, HAV hepatitis can relapse in contrast to HEV, which only causes a single episode of clinical illness.

Conclusion

HEV infection is a major cause of morbidity in areas of over crowding and poor water hygiene. Pregnant women and patients with preexisting liver disease are most likely to develop fulminant hepatitis, with an associated high mortality. They could therefore be targeted for vaccination in endemic areas. Ultimately prevention of transmission by good sanitation and boiling drinking water is the best approach to reduce morbidity and mortality from HEV and a number of other waterborne pathogens.

References

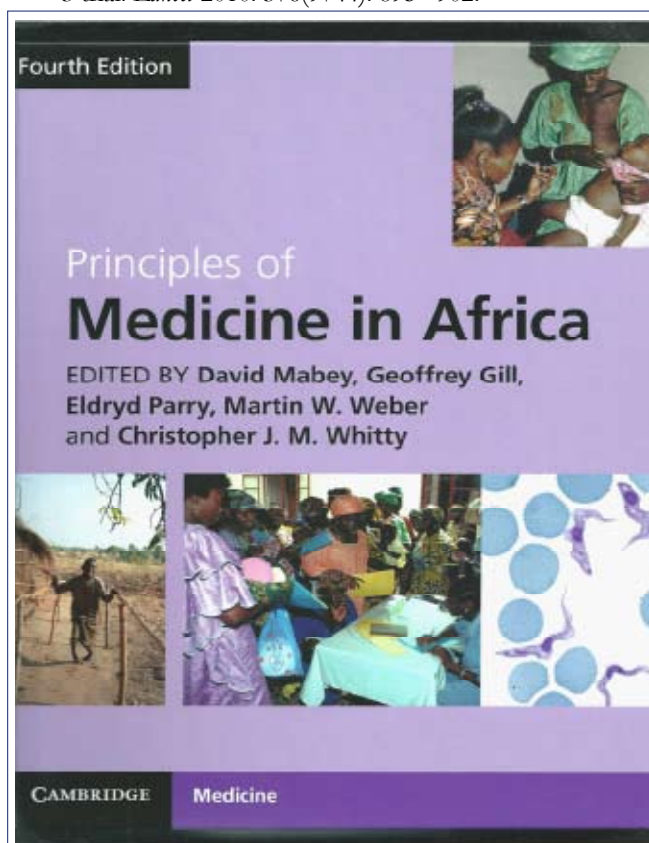
1. Balayan MS, Andjaparidze AG, Savinskaya SS, et al. Evidence for a virus in non-A, non-B hepatitis transmitted via the fecal-oral route. *Intervirology* 1983;20:23–31
2. Bryan JP, Tsarev SA, Iqbal M, Ticehurst J, Emerson S, Ahmed A, et al. Epidemic hepatitis E in Pakistan: patterns of serologic response and evidence that antibody to hepatitis E virus protects against disease. *J Infect Dis*. 1994;170(3):517–21.
3. Buti M, Plans P, Dominguez A, et al. Prevalence of hepatitis E virus infection in children in the northeast of Spain. *Clin Vaccine Immunol* 2008;15:732–734.
4. Caron M, Bouscaillou J, Kazanji M. Acute risk for hepatitis E virus infection among HIV-1-positive pregnant women in central Africa. *Virol J*. 2012 Oct 31;9:254.
5. Dalton HR, Bendall RP, Keane FE, Tedder RS, Ijaz S. Persistent carriage of hepatitis E virus in patients with HIV infection. *N Engl J Med*. 2009;361(10):1025–7.
6. Drobeniuc J, Meng J, Reuter G et al. Serologic assays specific to immunoglobulin M antibodies against hepatitis E virus: pangenotypic evaluation of performances. *Clin Infect Dis* 2010; 51(3): e24–e27
7. Emerson SU, Arankalle VA, Purcell RH. Thermal stability

of hepatitis E virus. *J Infect Dis* 2005;192:930–933.

8. Guthmann JP, Klovstad H, Boccia D, et al. A large outbreak of hepatitis E among a displaced population in Darfur, Sudan, 2004: the role of water treatment methods. *Clin Infect Dis*. 2006;42:1685–91.
9. Hazam RK, Singla R, Kishore J, Singh S, Gupta RK, Kar P. Surveillance of hepatitis E virus in sewage and drinking water in a resettlement colony of Delhi: what has been the experience? *Arch Virol* 2010; 155 (8): 1227–1233.
10. Kamar N, Abravanel F, Selves J et al. Influence of immunosuppressive therapy on the natural history of genotype 3 hepatitis-E virus infection after organ transplantation. *Transplantation* 2010; 89(3): 353–360
11. Kamar N, Bendall R, Legrand-Abravanel F et al. Hepatitis E. *Lancet* 2012; 379(9835): 2477–2488.
12. Kamar N, Bendall R, Peron JM et al, Hepatitis Virus E and Neurologic Disorders. *Emerging Infectious Diseases* (www.cdc/eid); 2011, 17 (2)).
13. Kamar N, Selves J, Mansuy JM, Ouezzani L, Peron JM, Guitard J, et al. Hepatitis E virus and chronic hepatitis in organ-transplant recipients. *N Engl J Med*. 2008;358(8):811–7
14. Kumar A, Aggarwal R, Naik SR, Saraswat V, Ghoshal UC, Naik S. Hepatitis E virus is responsible for decompensation of chronic liver disease in an endemic region. *Indian J Gastroenterol* 2004; 23(2): 59–62.
15. Matsubayashi K, Nagaoka Y, Sakata H, et al. Transfusion-transmitted hepatitis E caused by apparently indigenous hepatitis E virus strain in Hokkaido, Japan. *Transfusion* 2004;44:934–940.
16. Purcell RH, Emerson SU. Hepatitis E: an emerging awareness of an old disease. *J Hepatol* 2008;48:494–503
17. Rein DB, Stevens GA, Theaker J, Wittenborn JS, Wiersma ST. The global burden of hepatitis E virus genotypes 1 and 2 in 2005. *Hepatology*. 2012;55(4):988–97
18. Scobie L and Dalton HR. Hepatitis E: Source and Route of Infection, Clinical Manifestations and New Developments. *J Viral Hepat*. 2013;20(1):1-11.
19. S de Paula V, Wiele M, Mbunkah AH, Daniel AM, Kingsley MT, Schmidt-Chanasit J. Hepatitis E virus genotype 3 strains in domestic pigs, Cameroon. *Emerg Infect Dis*. 2013 Apr;19(4):666-8.
20. Shrestha MP, Scott RM, Joshi DM, Mammen MP Jr, Thapa GB, Thapa N, et al. Safety and efficacy of a recombinant hepatitis E vaccine. *N Engl J Med*. 2007;356(9):895–903
21. Smith DB, Purdy MA, Simmonds P. Genetic variability and the classification of hepatitis E virus. *J Virol*. 2013 Apr; 87(8):4161-9.
22. Tei S, Kitajima N, Takahashi K, et al. Zoonotic transmission of hepatitis E virus from deer to human beings. *Lancet*

2003;362: 371–373.

23. Tsarev SA, Tsareva TS, Emerson SU, Govindarajan S, Shapiro M, Gerin JL, et al. Successful passive and active immunization of cynomolgus monkeys against hepatitis E. *Proc Natl Acad Sci U S A*. 1994;91(21):10198–202.
24. Wedemeyer H, Pischk S, Manns M, Pathogenesis and Treatment of Hepatitis E Virus Infection. *Gastroenterology* 2012;142:1388–1397
25. Wu T, Zhu FC, Huang SJ, Zhang XF, Wang ZZ, Zhang J, et al. Safety of the hepatitis E vaccine for pregnant women: a preliminary analysis. *Hepatology*. 2012;55(6):2038
26. Zhao Q, Zhang J, Wu T, Li SW, Ng MH, Xia NS, Shih JW. Antigenic determinants of hepatitis E virus and vaccine-induced immunogenicity and efficacy. *J Gastroenterol*. 2013 Feb;48(2):159–68.
27. Zhu FC, Zhang J, Zhang XF et al. Efficacy and safety of a recombinant hepatitis E vaccine in healthy adults: a large-scale, randomised, doubleblind placebo-controlled, phase 3 trial. *Lancet* 2010; 376(9744): 895– 902.

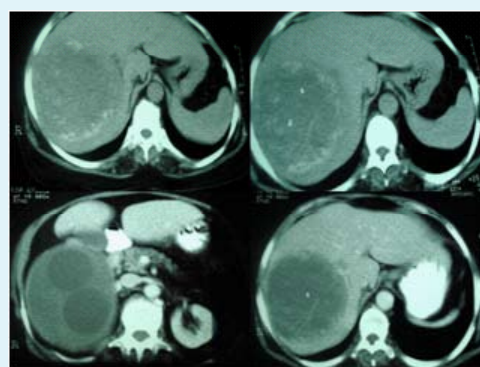


This Book which costs £150 new was donated to the South Sudan Postgraduate Medical Education & Training Library Juba by Dr. Peter Newman, Consultant Neurologist, James Cook University Hospital, Middlesborough. If you have a reference textbook which is less than five years old in Surgery, Medicine, Obstetrics & Gynaecology, Paediatrics & Child Health and Primary Health Care which you wish to donate to this newly established Library please email Dr. Eluzai Hakim with details on eluzaihakim@doctors.org.uk

QUIZ ANSWERS FOR OUR READERS

Lady with fever and hepatomegaly

Case: A 54-year old female from an urban area presented with low grade fever, and vague right upper quadrant abdominal discomfort of one month duration. She was a sweeper by profession and had no close contact with pets. On examination she was febrile; the vital signs were stable and she had no jaundice or other stigmata of chronic liver disease. The liver was palpable to 7cms below the right costal margin and 4cms in the epigastrium with a smooth surface, and was tender to palpation: there were no bruits. Her haemogram and biochemical parameters were normal except for elevated alkaline phosphate levels (323 IU/L). These were the contrast enhanced computerized tomography images (see image).



Questions and answers:

Q1. What is the likely diagnosis?

A. Hydatid cyst of liver.

Q2. What other conditions should be considered?

A. Liver abscess, biliary cystadenoma and hepatoma.

Q3. What is the most likely causative organism?

A. *Echinococcus granulosus*.

Q4. What is the most serious complication of this condition?

A. Rupture of a cyst leading to anaphylactic shock.

Q5. Are there any serological tests that would aid diagnosis?

A. Enzyme-linked immunosorbent assay (ELISA): positive in 90%.

Q6. What is the gold standard treatment of the condition?

A. Surgical removal without disruption of cyst contents.

Q7. Which is the preferred drug for the treatment of the condition?

A. Albendazole.

Quiz sent by George Sarin Zacharia