

# Suspected clinical-radiological discord

Martin Tombe<sup>a</sup> M. Med (Medicine)

## Abstract

17-year male student presented with vague constitutional symptoms and jaundice. His clinical chest findings initially suggested a discord with radiological findings. It turned out that the patient had a rare congenital disorder in addition to a seemingly common condition that brought him to the hospital.

The purpose of this case presentation is to share some challenges of a clinical-radiological discord in a teaching hospital in Zimbabwe. It shows a flow of teamwork from House Officers to the Consultants as well as radiological back up.

## Case presentation

A seventeen-year old male student was seen in 2004 by a House Officer in Mpilo Central Hospital, a Teaching Hospital in Zimbabwe. He had complained of malaise, loss of appetite and epigastric discomfort for two weeks. He did not take alcoholic drinks. Systematic enquiry was unremarkable. On examination he looked generally well. His body temperature was 36.8<sup>o</sup> C. The pulse was 80 beats per minute and regular. His blood pressure was 110/70 mmHg and he was jaundiced with no pallor or lymphadenopathy. There was dullness to percussion and absent breath sounds over the left lower chest posteriorly and laterally. Examination of the other body systems was reported to be normal. There was no tenderness, masses or free fluid elicited in the abdomen.

## Diagnoses and investigations

The clinical diagnoses were viral hepatitis and left pleural effusion.

- The full blood counts (FBC) and erythrocyte sedimentation rate (ESR) were within normal limits; thus WBC 4.2/ $\mu$ L, Hb 12.5g/dL and platelet 220/ $\mu$ L while ESR was 14 mm 1st hour of Westergren.
- The liver function tests were hepatic in nature; thus alkaline phosphatase was 130 IU/L, alanine aminotransferase (ALT) 120 IU/L, aspartate aminotranferace (AST) 80 IU/L. Total bilirubin 90 $\mu$ mol/L and direct bilirubin 68 $\mu$ mol/L.
- The chest X-ray was reported as normal (Figure 1).

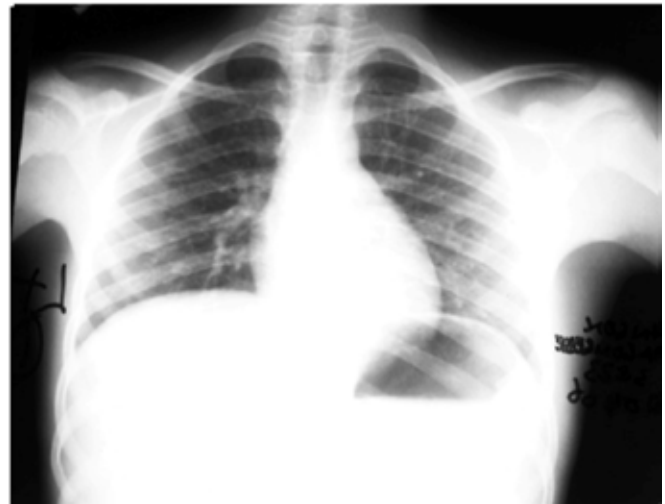


Figure 1. A postero-anterior chest X-ray showing no left pleural effusion

## Consultant's review

The following morning the patient was reviewed by the Consultant who agreed with the possible diagnosis of viral hepatitis as one of the working diagnoses but which did not require in-patient care. Nevertheless an haemolytic process must also be considered. He commented that the therapeutic dose of paracetamol as prescribed was not contraindicated in liver diseases if given for a short time. He agreed with the clinical chest findings. He was surprised that there was no left pleural effusion on the chest X-ray. One possibility he considered was that the X-ray belonged to another patient. Before deciding on a repeat chest X-ray he re-examined the patient. He concluded that the chest X-ray definitely belonged to the patient, it was abnormal and he discharged the patient to be followed up as an out-patient.

The signs he had found were a cardiac apex beat on the right side and an area suggestive of hepatic dullness on the left side of the chest. The chest X-ray showed that the heart shadow and stomach gas bubble were on the right. The left hemi-diaphragm was higher than the right consistent with a left sided liver as shown in the edited chest X-ray (Figure 2).

On a closer observation and properly oriented the same chest X-ray (Figure 1) showed that it had been correctly but not clearly labelled (Figure 3).

## Final diagnosis

The final diagnosis was dextrocardia with situs inversus. Hence there was a clinical-radiological concordance rather

<sup>a</sup> a Specialist and Consultant Physician, Letsholathebe II Memorial Hospital, Maun, Botswana

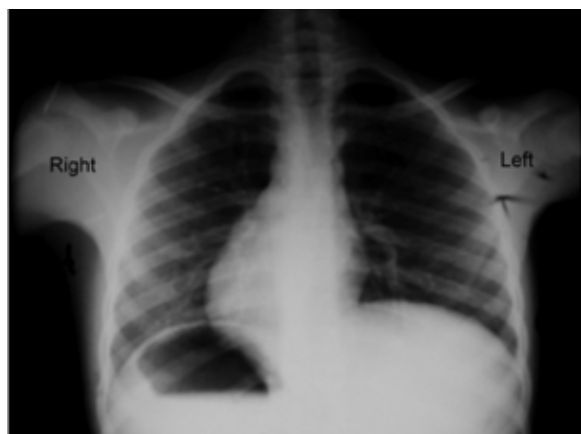


Figure 2. The edited postero-anterior chest X-ray properly oriented

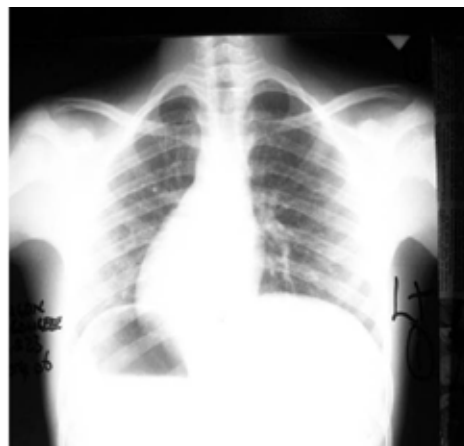


Figure 3. A properly oriented chest X-ray in figure 1 showing dextrocardia and situs inversus.

than discord. After two weeks the jaundice had cleared and the hepatitis screen was positive for hepatitis A.

### Discussion

It is not uncommon to miss rare conditions on first examination. That is why even the consultant had suggested the X-ray may not belong to the patient until he did a physical examination. The need to label X-rays properly to avoid such errors cannot be overemphasized [1]. The indication for a further physical assessment arose from the absence of other supportive symptoms and signs for a pleural effusion and a chest X-ray that did not fit the physical signs.

Situs inversus with dextrocardia describes mal-rotation of the gut with the organs reversed from their abdominal normal positions. Without further investigations it cannot be stated with certainty if the case described had complete situs inversus and other cardiac congenital abnormalities such as ventricular septal defect. It is inherited as autosomal recessive and is believed to affect 1 in 12,000 people [2]. It may be associated with immotile cilia syndrome. This may affect the cilia of bronchi and paranasal sinuses leading to bronchiectasis and chronic paranasal sinusitis as in Kartagener's syndrome<sup>1</sup>.

Males may have immotile spermatozoa and hence be infertile. There are other clinical disorders associated with dextrocardia [3] but they are beyond the scope and purpose of this article. There were no signs to suggest Kartagener's syndrome in this patient.

<sup>1</sup> Manes Kartagene described the syndrome in 1933

### Learning points

1. Attention to the basic physical signs in all systems is essential during the initial examination: in this case the identification of the cardiac apex beat. This patient did not appear to have any reasons such as pulmonary emphysema to explain why the apex beat could not be felt on the left side.
2. Careful labelling of any X-ray in terms of its orientation.
3. The patient, on discharge, should be informed of the diagnosis of dextrocardia with situs inversus. This could have implications for future diagnostic problems such as acute appendicitis as his appendix is likely to be in the left iliac fossa, his spleen is probably on the right hypochondrion.

**Conflict of interest:** None.

### References

1. Voigt S. How to Read a Chest X-ray – A Step by Step Approach. *SSMJ*. 2008;1(2): 8-18
2. Kartagener M. Zur pathogenese der bronchiectasien. I Mitteilung: bronchiectasien bei situs viscerum inversus. *Betr Klin Tuberk.* 1933; 83: 498-501
3. Bohun CM, Potts JE, Casey BM, Sandor GG. A population-based study of cardiac malformations and outcomes associated with dextrocardia. *Am. J. Cardiol.* 2007; 100 (2): 305–309.

**The Juba Link e-mail Newsletter #8** (January 2013) has just been published. To join the mailing list write to Zorina Walsh at [twalsh721@btinternet.com](mailto:twalsh721@btinternet.com). Or visit the new Juba Link website at [www.jubalink.org.uk](http://www.jubalink.org.uk) where there are details of the link between St Mary's Hospital, Isle of Wight, UK and Juba Teaching Hospital, South Sudan.