

Pericardial effusion complicated by tamponade: a case report

Michele Montandon^a MD, Rae Wake^a BM and Stephen Raimon^b MBBS

Introduction

Pericardial effusion is fluid in the space between the heart and the pericardial sac. There are many causes of pericardial effusion, with infection (viral and TB) as the most common. If fluid rapidly accumulates in the pericardial space, like in chest trauma, this fluid can compress the heart (cardiac tamponade) and cause circulatory failure. With slow accumulation of fluid, the pericardial sac will stretch to accommodate the fluid. However, if fluid continues to accumulate, tamponade will eventually occur. This is an emergency situation requiring aspiration of pericardial fluid (pericardiocentesis).

History and physical examination

A 40-year-old South Sudanese man was referred from a state hospital. He complained of fever, cough productive of mucoid sputum without haemoptysis and chest pain for four months. He also reported weight loss for two months and abdominal and lower limb swelling for one month. In addition he had fatigue, palpitations and exertional dyspnoea but denied orthopnoea.

He had no past history of medical or surgical conditions, no known tuberculosis contacts and had never been tested for HIV.

On physical examination he was wasted and sleepy but oriented and speaking in full sentences. Glasgow Coma Score 15/15. Pulse 102/minute and weak and thready. Respiratory rate 40/minute. Blood pressure 80/40. Pale but no jaundice. Pitting lower limb oedema up to the knees. Chest auscultation revealed crackles at both bases. The heart sounds were muffled but there were no added sounds, murmurs or friction rubs. The jugular venous pressure could not be determined. The abdomen was soft, distended with a fluid thrill and tender hepatosplenomegaly. Bowel sounds were normal.

Investigations

The patient brought a chest X-ray from the state hospital and this showed a massively enlarged cardiac silhouette and bilateral pulmonary infiltrates or oedema (Figure 1). An urgent bedside ultrasound showed a large pericardial

effusion of about 2 cm, right atrial collapse and right ventricular collapse in diastole (Figure 2).

HIV testing was negative. A further chest X-ray showed the same features as the one that was brought with the patient.

Treatment and progress

The physical examination suggested and cardiac ultrasound confirmed cardiac tamponade. An emergency pericardiocentesis was performed by a subxiphoid approach using ultrasound guidance. Only 75mL of serous (clear-yellow) fluid could be aspirated before the needle became blocked. However the blood pressure rose to 130/100 and the patient became haemodynamically stable. The pericardial fluid was smear positive for AFB so the patient was started on anti-TB therapy. Unfortunately, he passed away two days later. The precise cause of death is not known but may have been due to re-accumulation of pericardial fluid and cardiac tamponade.

Comment

The patient presented with cardiac tamponade, the most severe complication of TB pericarditis. The key to urgent treatment was the fact that the clinicians were aware of this possible diagnosis, which was confirmed with bedside cardiac ultrasonography. Emergency pericardiocentesis was possible using ultrasound to guide the insertion of

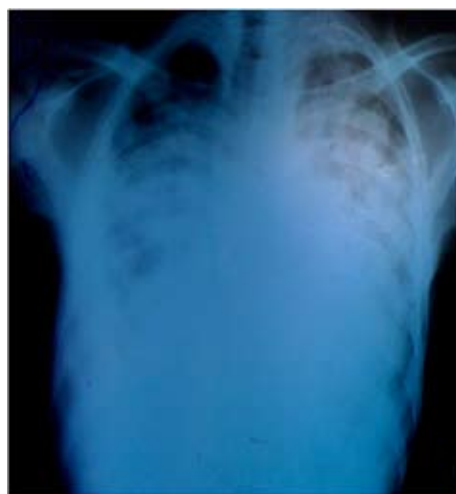

Figure 1. Chest X-ray demonstrating enlarged cardiac silhouette and bilateral pulmonary infiltrates or oedema (credit: Rae Wake. Permission obtained from patient)

^a Massachusetts General Hospital, Department of Emergency Medicine, Division of Global Health and Human Rights, Boston, MA, USA.

^b Juba Teaching Hospital, Juba, South Sudan

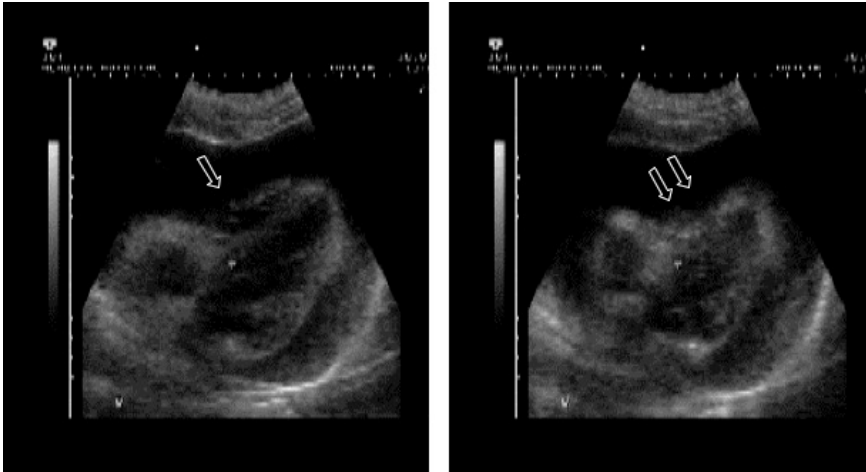


Figure 2. Cardiac ultrasound demonstrating large pericardial effusion and right ventricular collapse. Impaired filling of the right ventricle during diastole is visible (arrow) during inspiration. This even increases during expiration, when right ventricle almost collapses (2 arrows). (Courtesy Dr. Tom Heller, Munich)

the aspirating needle. Nevertheless, prognosis is poor once the condition has progressed to cardiac tamponade, and early diagnosis and treatment of TB pericarditis may prevent this potentially fatal complication.

Pericarditis classically presents with shortness of breath and chest pain that is sharp, sudden, pleuritic and is relieved by sitting forward. A pericardial friction rub may be heard at the left sternal border but this disappears when fluid accumulates.

Cardiac tamponade occurs when fluid in the pericardial space accumulates faster than the pericardial sac can stretch and so causes high pressure compressing the heart and preventing the heart from expanding fully. For example, in cardiac trauma where blood fills the space quickly, as little as 100mL can cause tamponade. However, if the fluid accumulates more slowly as with TB pericarditis, the pericardial sac can expand to hold over one litre of fluid before critical compression arises [1].

The three classical signs of cardiac tamponade (also called Beck's triad) are **hypotension, jugular venous distention, and muffled heart sounds**. Hypotension results from decreased cardiac output, jugular-venous distention results from impaired venous return to the heart and, muffled heart sounds are due to pericardial fluid. There are other physical signs that may indicate cardiac tamponade. On inspiration the central venous pressure (jugular venous pressure) would normally fall but with tamponade this rises. Pulsus paradoxus is the finding of a fall in the systolic blood pressure of more than 10mmHg when the patient inspires [2].

The **chest Xray** of a patient with large pericardial effusion shows a large "boot-shaped" cardiac silhouette

but it can be difficult to tell if a large heart is due to dilated cardiomyopathy or pericardial effusion.

Ultrasound easily detects a large pericardial effusion: the fluid appears anechoic or black around the heart. The right atrium and right ventricle appear collapsed with dilation of the inferior vena cava [2].

In this case, the underlying cause of the pericardial effusion was rapidly established by the positive AFB smear test. However the other differential diagnoses would have included those in Table 1.

Tuberculous (TB) pericarditis

Epidemiology

Tuberculous pericarditis, caused by *Mycobacterium tuberculosis*, is found in approximately 1% of all autopsied cases of TB and in 1% to 2% of instances of pulmonary TB. It is the most common cause of pericarditis in Africa [3]. In one series from the Western Cape Province of South Africa, tuberculous pericarditis accounted for 69.5% (162 of 233) of cases referred for diagnostic pericardiocentesis [4]. By contrast, tuberculous pericarditis accounts for only 4% of cases in developed countries [3]. The incidence of tuberculous pericarditis in sub-Saharan Africa is increasing as a result of the human immunodeficiency virus (HIV) epidemic, and this trend is likely to appear in other parts of the world [5,6].

Recent studies of patients with TB pericarditis in sub-Saharan Africa found the overall mortality rate in the range of 17-27%. Risk of death was higher in patients with HIV infection, older age, and co-existing pulmonary tuberculosis [7,8].

Diagnosis

Pericardial fluid has a poor yield of about 2% (range 0-42% reported) of acid fast bacilli (AFB) on smear examination but TB culture is positive in 38-56% [8]. We were therefore fortunate to find AFB on a smear from our patient. A raised lymphocyte count, adenosine deaminase, protein and lactate dehydrogenase levels in the pericardial fluid are useful indicators of TB [9].

An adequate clinical assessment as described for our patient is always important but even more so in the absence of reliable laboratory tests. Evaluation for pulmonary TB (chest Xray and sputum AFB) and HIV may help guide your clinical diagnosis.

Patients from TB endemic areas who present with

MAIN ARTICLES

Table 1. Causes of pericarditis or pericardial effusion [1]

Infection- viral, TB, bacterial, fungal, HIV
Malignancy <ul style="list-style-type: none"> • Primary • Metastatic
Post-cardiac injury syndrome (after trauma or cardiothoracic surgery)
Acute myocardial infarction (acute, delayed)
Metabolic-uremia, hypothyroidism
Collagen vascular diseases- rheumatoid arthritis, lupus erythematosus
Radiation
Idiopathic

pericarditis must be regarded with a high index of suspicion. In the absence of an alternative diagnosis, patients should be started on empirical anti-tuberculosis treatment irrespective of test results [5].

Treatment

Patients diagnosed with TB pericarditis should be promptly started on anti-TB therapy using the standard 4-drug regimen. Pericardiocentesis is a life-saving procedure for patients with cardiac tamponade and as in our patient only a small volume of aspirate (75 ml) may have a dramatically beneficial effect.

It is generally recommended that patients with TB pericarditis are also prescribed steroids, although there are only a few clinical trials to support this recommendation [3]. The dose recommended is 60mg prednisolone daily for adults and 1mg/kg/day for children with gradual withdrawal after 2-3 weeks [10,11]. There is less evidence available to support steroid use in HIV positive patients, but one small study in Zimbabwe found mortality benefit with use of prednisolone [12].

Learning points

- Pericarditis typically presents with shortness of breath and pleuritic chest pain that gets better when leaning forward.
- A large or rapidly expanding pericardial effusion can lead to cardiac tamponade. This is a life-threatening condition and requires emergency pericardiocentesis.
- Close monitoring, especially during the hours after pericardial aspiration, looking for rising pulse and respiratory rate and falling blood pressure is needed as fluid may reaccumulate and cardiac tamponade recur.
- In sub-Saharan Africa, TB pericarditis is the most common cause of pericardial effusion and cardiac tamponade.

- Recommended treatment for TB pericarditis includes standard 4 drug anti-TB therapy for a six months' course, as well as prednisolone daily for at least 2-3 weeks.

Acknowledgement

We thank the CEO of JTH and Dr Elijah in whose Medical Department we carried out this case study - with the verbal permission of the patient

References

1. Little WC, Freeman GL. Contemporary Reviews in Cardiovascular Medicine: Pericardial Disease. *Circulation*. 2006; 113: 1622-1632.
2. Khandaker MH, Espinosa RE, Nishimura RA, Sinak LJ, Hayes SN, Melduni RM et al. Pericardial Disease: Diagnosis and Management. *Mayo Clinic Proc*. 2010 June; 85(6):572-593
3. Mayosi BM, Burgess LJ, Doubell AF. Tuberculous Pericarditis. *Circulation*. 2005;112:3608-3616
4. Sagrista-Sauleda J, Permanyer-Miralda G, Soler-Soler J. Tuberculous pericarditis: ten-year experience with a prospective protocol for diagnosis and treatment. *J Am Coll Cardiol*. 1988;11:724-728.
5. Heller T, Lessells RJ, Wallrauch C, Brunetti E. Tuberculosis Pericarditis with Cardiac Tamponade: Management in the Resource-Limited Setting. *Am J Trop Med Hyg*. 2010 December 6; 83(6): 1311-1314.
6. Fowler NO. Tuberculosis pericarditis. *J Am Med Assoc*. 1991; 266: 99-103.
7. Mayosi BM, Wiysonge CS, Ntskhe M, Gumede F, Volvink JA, Maartens G et al. Mortality in patients treated for tuberculous pericarditis in sub-Saharan Africa. *S Afr Med J*. 2008. Jan; 98(1):36-40.
8. Reuter H, Burgess LJ, Louw VJ, Doubell AF. The management of tuberculous pericardial effusion: experience in 233 consecutive patients. *Cardiovasc J S Afr*. 2007 Jan-Feb; 18 (1):20-25.
9. Imazio M, Spodick DH, Brucato A, Trinchero R, Markel G, Adler Y. Diagnostic issues in the clinical management of pericarditis. *Int J Clin Pract*. 2010;64:1384-1392
10. The National Collaborating Centre for Chronic Conditions and the Centre for Clinical Practice at NICE. Tuberculosis. Clinical diagnosis and management of tuberculosis, and measures for its prevention and control. NICE, 2007.
11. American Thoracic Society, Centres for Disease Control, and Infectious Disease Society of America. Treatment of Tuberculosis. *MMWR Morb Mortal Wkly Resp* 2003; 52:1
12. Hakim JG, Ternouth I, Mushangi E, Siziya S, Robertson V, Malin A. Double blind randomised placebo controlled trial of adjunctive prednisolone in the treatment of effusive tuberculous pericarditis in HIV seropositive patients. *Heart* 2000; 84:183-188.