

Guidelines for the Management of Suspected Microbial Keratitis in Settings with Limited Laboratory Facilities

Wani MG, Consultant Ophthalmologist, Sakubva Eye Unit, Mutare Zimbabwe^a

Introduction

Microbial Keratitis, also referred to as Suppurative Keratitis or Corneal Ulcer, is a potentially sight threatening condition that may present to doctors and nurses working in State hospitals and eye units in South Sudan.

Delay in treatment can result in development of complications that may lead to loss of sight or destruction of the eye. It is generally recommended that corneal scrapping and microscopic examination of smears be performed to identify organism type before initiation of therapy and that culture and sensitivity testing be undertaken to provide information necessary for subsequent treatment modification.

These recommendations, although good, are impractical in settings where laboratory facilities are not readily available or reliable. In this case initial choice of antibiotics therapy may be made without the benefit of Gram Stain Microscopy results.

In recent years, a number of new broad spectrum antibiotics have been introduced that as single agents have been effective in treating corneal ulcers. This seems to vindicate the position previously held by some ophthalmologists that extensive laboratory workup, although essential, only rarely changes the course of initial therapy, regardless of the basis on which such therapy was chosen.

A good history, clinical examination and knowledge of prevalence and sensitivity pattern of local isolates can assist the clinician select appropriate antibiotics for initial treatment of suspected case of microbial keratitis. This article presents guidelines that would aid the clinician in making such decision in settings where minimum or no laboratory support exists.

Microbial Keratitis

The cornea is the transparent avascular part of the sclera that lies in front of the eye protected by the eyelids. It is covered by epithelium that provides the first line of defence against invading micro-organisms. The tear film spread on its surface by the blinking action of the lids contains lysozymes that have antibacterial activity against most bacteria.

Suppurative Corneal ulcer occurs following invasion of the cornea by pathogenic bacteria capable of penetrating intact epithelium such as *Corynebacterium Diphtheriae*, *Neisseria Gonorrhoeae* and *H. influenzae*. Non surgical trauma is the commonest factor predisposing the cornea to infection with less virulent organisms that are usual commensals of the lid. Spontaneous invasion of the cornea may occur in patients with previous history of *Herpes Simplex*, *Exposure Keratopathy*, *Diabetes Mellitus*, *contact lens wear* and general immune suppression.

The prevalence of blindness directly resulting from complications of *Suppurative Keratitis* is estimated to be 5%¹. This figure is likely to increase as other causes of corneal blindness decrease with improvement in immunization against measles, control of *Xerophthalmia*, and other corneal blinding diseases. In developing regions like India, Africa and Asia, *Suppurative Keratitis* is the second commonest cause of uniocular blindness after cataract². Blindness caused by sequale of *Suppurative Keratitis* can be considered irreversible in parts of the world where corneal grafting services are non existent. Patients are therefore at increased risk of total blindness if the other eye should lose sight to other blinding conditions. Early recognition and treatment are therefore important to avert the sight threatening complication of this condition

The cornerstone of effective treatment is informed initial antibiotic choice with later modification as clinical cause dictate. At a primary and secondary eye care level and sometime in tertiary eye care centres without adequate laboratory support, such a choice has often to be made without the benefit of laboratory data.

Careful history, consideration of risk factors, evaluation of clinical characteristics of the ulcer and

^a P O Box 30, Mutare Zimbabwe, Email: wanimenamutare@mutare.icon.co.zw

knowledge of prevalence and sensitivity pattern of local isolates can guide the clinician in choosing appropriate initial therapy. The literature suggests that in temperate and tropical climates where agricultural activities and therefore trauma due to vegetative matter is common, Fungi are the most common cause of *Suppurative Keratitis*³ although bacteria are still isolated with increasing frequency where no history of injury is reported⁴. Therefore in formulating therapeutic strategy in such environment it is important to keep in mind the possibility of infection with bacterial and non-bacterial pathogens.

Predisposing factors

Presence of certain risk factors may point to infection with specific organisms; therefore direct inquiry in the history can elicit important information that may indicate particular organism. Trauma with vegetative matter or objects contaminated with soil can predispose to infection with filamentous fungi especially *Fusarium* and *Aspergillus* while patients with immune-suppression may be susceptible to yeast infection.

Use of traditional eye medicine (TEM) in home treatment of *Microbial Keratitis* should be especially enquired for in the history. It is a common practice among poor rural peasants in developing countries where access to eye care is limited. In one study in India⁵ 47% of patients were found to have used TEM before presentation to hospital. The prevalence of TEM use in Southern Africa is estimated to 24%⁶.

People frequently consult traditional healers because they are affordable and available, can be paid in kind, are within easy reach of the patient and are highly regarded in their communities. While traditional healers have had a positive impact in resolution of psychiatric and psychosocial problems, their role in the management of *Microbial Keratitis* has largely been negative. Some traditional eye medications are corrosive, have been prepared under unhygienic conditions using plant and animal extracts that are often contaminated by pathogenic bacteria or fungi. Use of traditional eye medicine delays patients from presenting to hospital and may modify the clinical picture, thus making etiological diagnosis impossible

Use of contact lens is fortunately uncommon in rural communities in developing countries although it is becoming widespread in urban centers of some countries. Contact lens wearers may be at risk of infection with the parasite *Acantoamoeba Histolytica* or *Pseudomonas* species if daily wear contact lenses are used and cleaning is done with a home-made solution. It is a common predisposing factor in developed countries where trauma is less frequent and use of this device is widespread

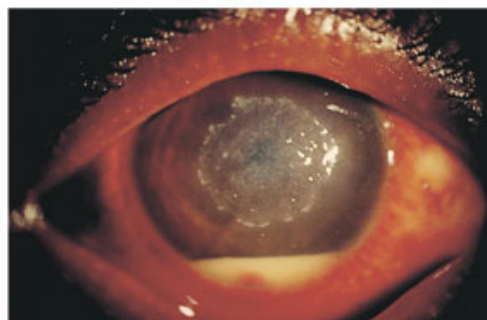
Previous *Herpes Simplex Keratitis*, *Neurotrophic Keratitis* or dry eyes are some of the other factors that can predispose to microbial Keratitis.

Clinical examination of the ulcer

A corneal ulcer is suspected in a patient complaining of sudden onset of pain, photophobia, discharge and reduced vision, in an inflamed eye that has a grey patch on the cornea. Severe ulcers involve more than half the corneal surface, penetrate to more than half corneal thickness and are complicated with hypopion – see Fig 1.

It is difficult to make etiologic diagnosis of an ulcer from history or clinical assessment alone but certain clinical characteristics may point to a particular etiologic agent.

Fig 1 Hypopion Ulcer



Note the round grey patch at the centre of the cornea and a collection of pus known as hypopion

Fungal ulcers have feathery edges (see Fig 2) and may be surrounded by satellite lesions. The ulcer tends to follow an indolent course rarely causing much pain. Hypopion when present tends to adhere to the endothelial surface instead of settling to the bottom of the anterior chamber. History of vegetative injury or treatment with steroid containing preparations is often present.

Bacterial ulcers tend to be more acute, presenting within few days of injury and are characterized by pain, photophobia, tearing and redness of the eye. *Pseudomonas*

ulcers produce copious greenish yellow discharge and progress rapidly to hypopion formation and corneal perforation. The surrounding cornea may have ground glass appearance.

The most common bacteria include Staphylococcus Epidermidis, Staphylococcus aureus, Pseudomonas Aeruginosa and streptococcus Pneumoniae. Fusarium and Aspergillus are common fungi

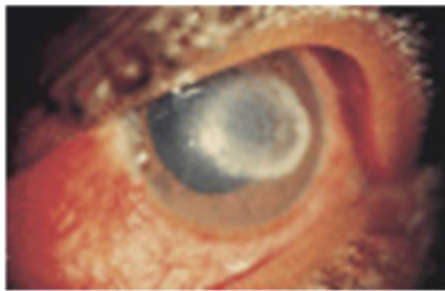


Fig 2 Fungal ulcer - note feathery edges

Value of Gram Stain Microscopy in Etiologic Diagnosis of Corneal Ulcers

Gram Stain Microscopy [GSM] is the recommended laboratory procedure that should be performed before initial antibiotic therapy is started. Where laboratory facilities are available this should be done as a routine procedure.. Where laboratory facilities are not adequate, it will be limited to cases with severe ulcers or when fungal infection is suspected from history or clinical examination. Gram stain will enable broad classification of organisms into Gram Positive and Gram Negative as well as fungal. It will also facilitate the building of a local database to act as a reference for future treatment decision and to examine changes in trends.

Sensitivity of Gram Stain Microscopy [GSM] varies in different studies ranging from 36% - 50%⁷⁻⁹. GSM tends to be positive in severe cases of bacterial infection or fungal infection and when antibiotic has not been used prior to presentation to hospital. It tends to be negative in small to medium ulcers.

Culture is the Gold standard that can confirm results of GSM and provide sensitivity data to enable modification of initial therapy. Corneal infiltrate should be sent for culture in all cases of severe ulcers, suspected fungal infection and those that are refractory to treatment. McLeod et al⁸ (see Table 1) compared the recovery rate of organisms by Gram Stain and Culture and found that in almost 49% of

instances Gram Stain missed organism that were subsequently recovered on culture.

Table 1. Identification of organisms by gram stain and culture

Gram stain	Culture	%
Organisms demonstrated on stain	Corresponding organisms recovered on culture	26
No organisms demonstrated on stain	Organisms recovered on culture	49
No organisms demonstrated on stain	No organisms recovered on culture	25

In some cases¹⁰, culture was not only negative in a case of positive smear but in fact it yielded different organisms from those seen on smear. From these studies, Only in a quarter of cases does culture result confirm a positive or negative smear.

Some of the reasons for the high false negative GSM rate are that patients with suppurative Keratitis usually always present late to hospital after a failed home treatment with either antibiotics or traditional eye medicine. The material obtained during scrapping is often small hence may not be sufficient for processing. Interpretation of corneal smears, traditionally done by primary physicians is time consuming and may call for expert knowledge of the practitioner.

Proper materials for obtaining corneal scrapping may not be stocked at the practitioners' office in adequate quantities. Thus it was shown⁸ that where scrappings were done, the procedure was often performed using cotton tipped applicator contrary to textbook recommendation that a metal Kumura spatula or wooden applicator be used in all cases. All these shortcomings may lead to low harvest rates of organisms seen in GSM.

Choice of initial antibiotic therapy

Initial antibiotic therapy may be chosen on the basis of Gram Stain Microscopy where this is available or it can be based on knowledge of most likely organisms as reported in local literature.

Evaluation of a patient with corneal ulcer

1. Take a good history paying attention to injury especially vegetative injury.
2. Find out if patient has instilled any traditional medicine preparation into the eye.
3. Carefully examine the ulcer and note presence of discharge, appearance of feather margins, and presence of satellite lesions, impending perforation and presence of hypopyon.
4. Make a tentative diagnosis and chose initial broad spectrum antibiotics according to knowledge of prevalence and sensitivity.

Initial therapy based on results of Gram Stain Microscopy - see Table 2.

- If GSM shows a single organism, start therapy with topical Ciprofloxacin 0.3% given frequently two hourly till improvement then reduce to TDS.
- If GSM shows mixed organisms: start combination therapy with topical cefazolin and Gentamicin two hourly and assess daily.
- If GSM shows presence of Fungi or positive history of vegetative injury – add an antifungal either Natamycin or Econazole eye drops TID.

Modify therapy if no improvement and according to culture and sensitivity results. Do not change therapy if patient is improving on current therapy even if sensitivity results indicate lack of sensitivity to the antibiotic in use.

Table 2. Choice of antibiotics based on results of GSM

Organism identified by GSM	Drug	Frequency	Duration
Single bacterial pathogen	Topical Ciprofloxacin eye drops	2-hourly until improvement then 3 times/day	7 days or until cure
Mixed bacterial pathogens	Combination therapy with topical Cefazolin and Gentamicin 0.3% eye drops	2-hourly until improvement then 3-hourly	7 days
Fungal elements	Topical Natamycin 5% or Econazole eye drops	3 times/day	7 days

Initial therapy based on prevalence of local isolates

1. Always assume mixed infection with both gram positive and gram negative organisms.
2. If there is a history of vegetative injury or use of TEM, assume presence of fungi and evaluate ulcer carefully

for signs of fungal infection such as feathery margins, satellite lesions etc.

3. Note if the patient is using contact lens.
4. Start broad spectrum antibiotics therapy with the following combination:
 - Topical fortified Cephazolin 5% or Ciprofloxacin 0.3% combined with fortified Gentamicin 1.4% and Natamycin 5% or Econazole.
 - Combine both Subconjunctival injection of Gentamicin and topical eye drops.
 - Give eye drops half hourly until improvement, then reduce to TDS.

How to prepare fortified antibiotic eye drops Gentamicin

Add 2ml parental Gentamicin (80mg) to 5ml of commercial Gentamicin ophthalmic solution (0.3%) to get final concentration of 14mg/ml.

Cefuroxime

Dilute 1g parental Cefuroxime in 2.5ml sterile water.

Take 2.5ml of this solution and add to 12.5ml of artificial tears to get final concentration of 50mg/ml.

References

1. Whitcher J, Srinivasan M, *Corneal Ulceration in the developing World*. Br J Ophthalmol 1997; 622-623 (August)
2. Brilliant LB, Pokhrel RP, Grasset NE, Lepkowski JM, Kolstrad A, Hawks W, Pararajagaram R et al *Epidemiology of blindness in Nepal* Bull World health organ. 1985; 63(2): 375-86
3. Thomas PA, Leck AK, Myatt M *Characteristic clinical features as an aid to diagnosis of Suppurative keratitis caused by filamentous fungi* British Journal of Ophthalmology 2005;89:1554-1558
4. Leck AK, Thomas PA, Hagan M, et al. *Aetiology of suppurative corneal ulcers in Ghana and south India, and epidemiology of fungal keratitis*. Br J Ophthalmol 2002;86:1211-1
5. Prajna VN, Pillai MR, Manimegalai TK, Srinivasan M. *Use of traditional eye medicines by corneal ulcer patients presenting to a hospital in South India*. Indian J Ophthalmol 1999;47:15-8
6. Courtright P, Lowallen S, Kanjalotis S, Divala DJ. *Traditional eye medicine use among patients with corneal disease in rural Malawi*. Br J Ophthalmol 1994; 78: 810-12
7. Sharma S, Kunimato DY, Gopinathan U, Athmanathan S, Grag P, Rao GN. *Evaluation of corneal scrapping smear examination methods in diagnosis of bacterial and Fungal Keratitis: Survey of 8 years of laboratory experience*. Cornea 2002 Oct; 21(7): 643-7
8. Stephen D, McLeod MD, Amir Kakahdouz Isfahni et al; *Role of smears, cultures & antibioitic sensitivity testing in management of suspected infectious Keratitis*. Ophthalmology Vol 103 No 1 Jan 1996
9. Wani MG, Makanganwi A, Guramatunhu S, *Prevalence and Causes of Corneal Ulcers seen at Sekuru Kaguvi Eye Hospital in Harare Zimbabwe*. Cent Afr J Med 2001;47(5):119-23
10. Poole TRG, Hunter DL, Maliwa EMK, Ramsay ARC *Aetiology of Microbial keratitis in Nothern Tanzania*. Br J Ophthalmol 2002; 86; 941-942