



Management of cutaneous bovine papillomatosis in a year-old Sokoto Gudali heifer through marginal resection

IA Suka¹, A Abdulrasheed¹, N Abdullahi¹, A Musa¹, AT Balarabe¹, M Umar², A Aliyu¹, AU Alamin³ & YB Lawali¹

- ^{1.} Ministry of Animal Health and Fisheries Development Sokoto, Sokoto State, Nigeria
- ^{2.} Department of Morbid Anatomy and Forensic Medicine, College of Health Sciences, Usmanu Danfodiyo University Sokoto, Sokoto State, Nigeria
- ^{3.} Ministry of Animal Health Husbandry and Fisheries Kebbi, Kebbi State, Nigeria, Nigeria

*Correspondence: Tel.: +2347038334178; E-mail: ibraheem.suka@gmail.com

Copyright: © 2024

Suka *et al.* This is an open-access article published under the terms of the Creative Commons Attribution License which permits unrestricted use, distribution, and reproduction in any medium, provided the original author and source are credited.

Publication History:

Received: 18-08-2023

Revised: 30-11-2023

Accepted: 04-12-2023

Abstract

Bovine papillomatosis is an infectious viral condition with cutaneous oncogenic characteristics. The disease is caused by bovine papillomavirus. It is transmitted by vertical spreading, arthropod vectors, and direct skin contact. Understanding the type of tumor, its clinical stage, and anticipated biological behaviors are crucial factors in the surgical oncology approach. A year-old Sokoto Gudali Heifer weighing approximately 80kg was presented to the Veterinary Clinic Sokoto with complaints of head rashes that spread to other parts of the body. On clinical examination, there were numerous, varying-sized cauliflower-like outgrowths with offensive odor and fly swarm. Cutaneous bovine papillomatosis was diagnosed based on clinical findings and supported by histopathology, and the Heifer was scheduled for marginal resection of the tumor. The surgery was successfully conducted; the Heifer was discharged two weeks after the surgery. Marginal resection approach was used in this case report and it involves the complete removal of a tumor leaving only a microscopic lesion, and ivermectin injection serves as a successful adjunct therapy in the treatment of cutaneous bovine papillomatosis. Different levels of aggressiveness should be taken into consideration when managing this type of tumor.

Keywords: Bovine, Cutaneous, Papillomatosis, Marginal resection, Nigeria, Cauliflower, Ivermectin

Introduction

Bovine papillomatosis (BP) is an infectious viral condition with cutaneous oncogenic characteristics. It is linked to the deterioration of leather and teat obstruction in cattle (Khan *et al.*, 2022). The disease is caused by Bovine papillomavirus (BPV) which belongs to the genus Papillomavirus, family Papillomaviridae. It is a double-stranded DNA virus that is non-enveloped, causing a cutaneous lesion on

the epithelium and mucosa of the affected animal (Araldi *et al.* 2017).

The five different genera of BPV which include; Delta papillomavirus, Xi Papillomavirus, Epsilon papillomavirus, Dyoxi Papillomavirus, and Dyokap Papillomavirus have been identified and are linked to a variety of pathological effects (Bauermann *et al.*, 2017). Transmission of the disease occurs through vertical spreading, arthropod vectors, and direct skin

contact (Ata *et al.*, 2021). Diagnosis can be made through clinical examination, histopathology, and electron microscopy (Araldi *et al.*, 2017).

Gross symptoms of bovine papillomatosis infection include endophytic and exophytic papillomatous growth that resembles cauliflowers on the skin of affected cattle. They are distributed differently on the neck, limbs, and back. The lesions lack hair growth and are firm, pedunculated, and have a rough, thick surface. They appear on the skin as multiple, uneven, elevated growths with varying sizes and a greyish-black color (Khattab *et al.*, 2023).

Histopathological examination of bovine skin warts revealed rete ridges that were generated by varying degrees of acanthosis and epidermal interdigitation seen projected outwardly or inwardly and were associated with hyper- or para-keratosis (Hassanien *et al.*, 2021). In another study, these changes were linked to the dilation and thinning blood vessel wall resulting in haemorrhage into the dermis and stratum corneum (Swamy Babu *et al.*, 2020).

In this case report, we discussed in detail the successful surgical management of cutaneous bovine papillomatosis with recommendations for a better clinical outcome.

Case Presentation

A year-old Sokoto Gudali heifer weighing approximately 80 kg was brought to the Veterinary Clinic Sokoto, Nigeria with complaints of head rashes that spread to other areas of the body (Plate I). The client claimed that the rashes were first seen three months before presentation.



Plate I: A year old Sokoto Gudali heifer presented with cutaneous bovine papillomatosis

Clinical examination findings

The patient appeared emaciated and had a rough haircoat upon examination. There were numerous, varying-sized cauliflower-like outgrowths on the head, neck, and other parts of the body. The ocular mucous membrane was slightly pale. The superficial lymph nodes of the prescapular and submandibular regions were grossly enlarged. The rectal temperature, respiratory rate, and pulse rate were 39.4°C, 30 cycles per minute, and 76 beats per minute respectively. Around the lesions, there was an offensive odor and a fly swarm, suggestive of secondary bacterial infection. Cutaneous bovine papillomatosis was diagnosed based on clinical findings and supported by histopathology which showed hyperkeratotic, acanthotic, and papillomatous stratified squamous epithelium with numerous areas showing viral inclusion bodies and the heifer was scheduled for marginal resection of the tumor.

Laboratory examination

The presurgical hematocrit revealed mild anaemia (20.8%) (physiological range 26-42%), haemoglobin, red blood cells, and white blood cells were 5.7g/dL, 4.25×10^{12} L, and 8.4×10^9 L respectively. Four irregular, warty, grey-white tissues, each measuring 4x2x2cm, 3.5x2x2cm, 2x2x1cm, and 1x1.5x1cm, were submitted for histological analysis, they totaled 25g in weight (Plate II).

Case management

Presurgical Management: Intramuscular administration of amoxicillin (Amoxinject LA[®]) injection at the dosage of 0.1 mg/kg body weight for



Plate II: Gross picture showing multiple irregular wart-like tissue from the skin of a Sokoto Gudali heifer

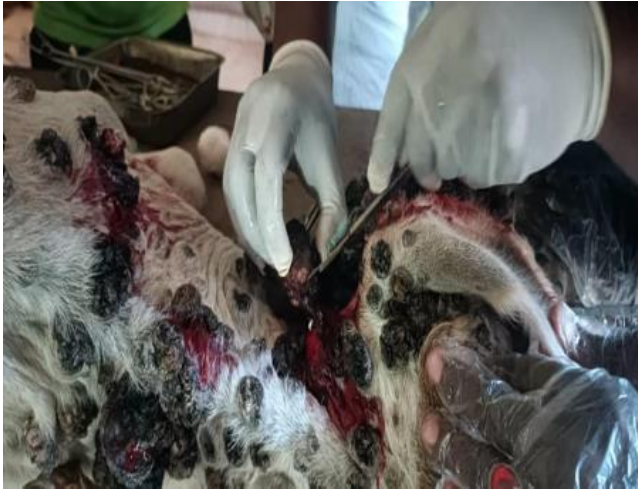

Plate III: Marginal resection of the tumor tissue from the skin of a Sokoto Gudali heifer

3 days was undertaken before the surgical technique to arrest the underlying secondary bacterial infection.

Surgical Management: The anesthetic protocol involved subcutaneous infiltration with Lignocaine HCL with adrenaline (C-Zocain Plus®) at the dosage of 7mg/kg. The surgery was conducted in two phases at a week interval: the left and the right lateral aspects. Each lesion was clamped with haemostatic forceps at its base incorporating healthy skin and marginal resection was conducted using a scalpel blade (Plate III). The resected site was cleaned with diluted 10% povidone-iodine (Sawke®). A horizontal mattress suture using nylon size 2 was applied to the incision site for skin closure and haemorrhage control where necessary. The procedure was repeated for all lesions on the left lateral aspect. Haemorrhages in other lesions were controlled using potassium permanganate. After the surgery, oxytetracycline spray was applied topically and a gauze bandage was wrapped around the surgical site to limit fly contamination.

Post-operative management

The post-operative medical management was conducted using amoxicillin (Amoxinject LA®) injection at 0.1 mg/kg for 3 days, diclofenac Na⁺ injection at 2.5 mg/kg for 3 days, vitamin K (Lamina 0.3®) injection at 2.5 mg/kg single dose, tetanus antitoxin (Dano-TT®) at 1500 units single dose, 10% dextran iron (I.DNOR®) at 6ml single dose and ivermectin 1% (Khairamectin®) injection at 200 mc/kg single dose. The surgical site was dressed daily with diluted 10% povidone-iodine (Sawke®). After 2 weeks, the Heifer recovered fully with remnants of scar formation (Plate IV).

Histopathology

Histology sections showing areas of orthokeratotic hyperkeratosis, papillated epidermal hyperplasia (Plate

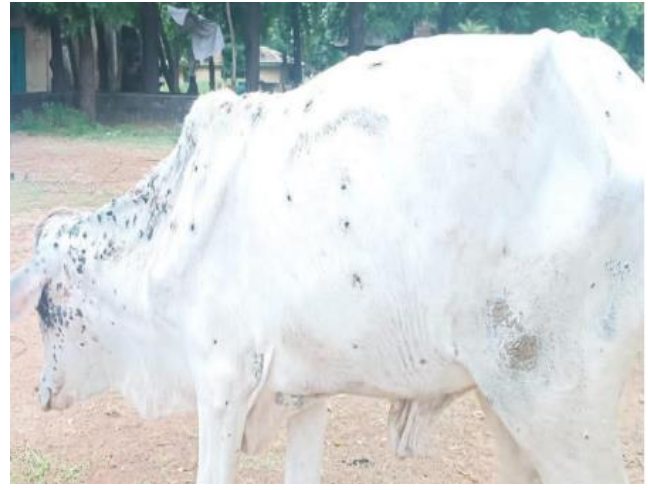

Plate IV: A Sokoto Gudali heifer two weeks after surgical removal of wart lesions

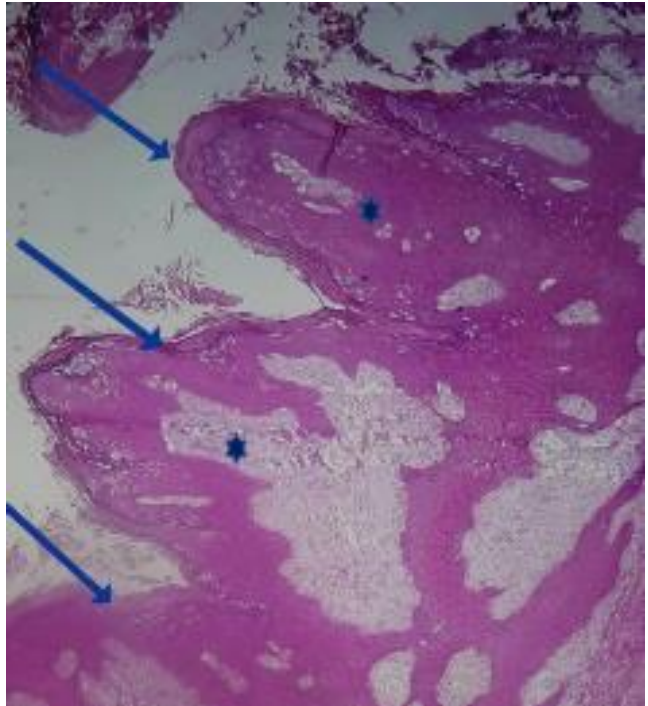


Plate V: Histological section of wart-like tissue from the skin showing areas of orthokeratotic hyperkeratosis (blue arrow), papillated epidermal hyperplasia (asterisk) HE 200X

V) with numerous areas showing viral inclusion bodies (Plate VI). The rete ridges were elongated and bent inward. The epidermis was fibrocollagenous with areas of lymphocytic infiltrates. Following the histological examination, a squamous papilloma was confirmed.

Postsurgical haematology

Postsurgical haematological results revealed mild anemia (21.0%) (physiological range 26-42%),

haemoglobin, red blood cells, and white blood cells were 5.4g/dL, $4.05 \times 10^{12}/L$, and $11.7 \times 10^9/L$ respectively. There was mild anaemia, however with a slight improvement in the haematocrit value most likely due to the administration of haematinics post-surgically.

Discussion

A clinical case of bovine papillomatosis is an economically significant infection causing a reduction in milk and meat production, hides devaluation, and mortality, posing a great financial loss (Crespo *et al.*, 2019). This, therefore, made its treatment of paramount importance.

Different treatment protocols have been described for the management of clinical cases of BP with varying degrees of success. Use of Ivermectin and other agents such as Thuja, Levamisole, Autogenous Vaccine, and autohaemotherapy were all reported (Caly *et al.*, 2020, Mariz *et al.*, 2016). However, those protocols require a prolonged period of management and therefore prolonged stress on

the animal. When there are only a few lesions, surgical resection of the lesions is advised, along with ivermectin treatment and paraimmunity inducers (Mariz *et al.* 2016). Surgical management proves to be the most expedited treatment protocol with a 100% success rate and faster recuperation.

This case presents an unusual occurrence of bovine papillomatosis, as the majority of cases tend to resolve spontaneously. However, in this particular instance, persistence was observed, attributed to the presence of an infestation of flies and the emergence of a foul odor emanating from the cutaneous lesions, indicating a potential secondary bacterial infection. Antibiotics medication was initiated three days presurgical and that drastically reduced the bacterial load contributing to the surgical success.

Understanding the type of tumor, its clinical stage, and anticipated biological behaviors are crucial factors in the surgical oncology approach. Different levels of aggressiveness should be taken into consideration when managing the tumor. The level of aggressiveness in surgical oncology are debulking, radical resection and marginal resection of the tumor. The marginal resection approach was used in this case and it involves the incomplete removal of a tumor with a microscopic lesion still present. Radiation therapy may be used as an additional therapy to effectively treat the microscopic lesions that are left after surgery. But in this case, Ivermectin injection

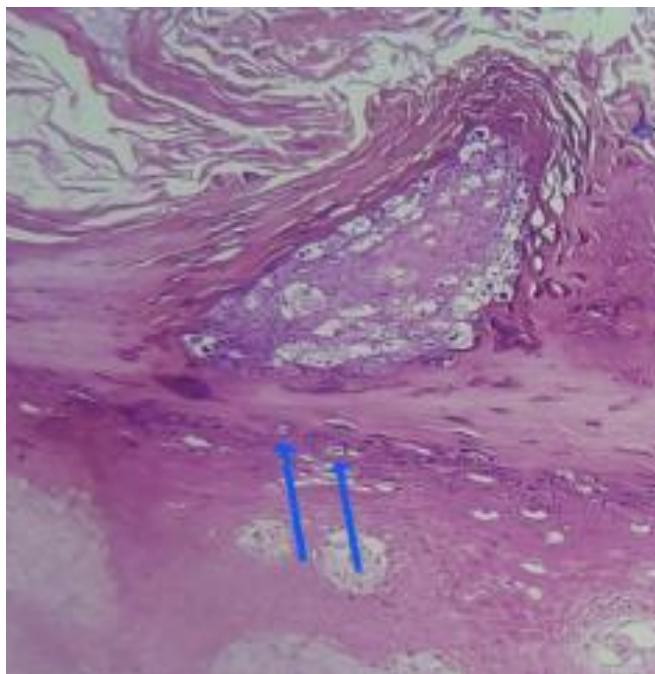


Plate VI: Histological section of wart-like tissue from the skin showing area with intranuclear viral inclusion bodies HE 400X

served as a successful adjunct therapy in the treatment of cutaneous bovine papillomatosis, and this conforms to the findings of previous studies (Mariz *et al.* 2016).

Funding

No funding was received.

Conflict of Interest

The authors declare that there is no conflict of interest.

References

- Araldi RP, Melo TC & Consonni SR (2017). Bovine papillomavirus productive infection in cell cultures: First evidence. *Virology: Research and Reviews*, **1**(2): 1-9.
- Ata EB, Allam AM, Elbayoumy MK & Mahmoud MAEF (2021). Electron microscopy and phylogenetic analysis of bovine papillomavirus infection in cattle from four Egyptian governorates. *Tropical Animal Health and Production*, doi.10.1007/s11250-021-02607-4.
- Bauermann FV, Joshi LR, Mohr KA, Kutish GF, Meier P, Chase C & Diel DG (2017). A novel bovine papillomavirus type in the genus dyokappapapillomavirus. *Archives of Virology*, **162**(10): 3225-3228.

- Caly L, Druce JD, Catton MG, Jans DA & Wagstaff KM (2020). The FDA-approved drug ivermectin inhibits the replication of SARSCoV-2 in vitro. *Antiviral Research*, doi.org/10.1016/j.antiviral.2020.104787.
- Crespo S, Lunardi M, Otonel R, Headley S, Alfieri AF & Alfieri A (2019). Genetic characterization of a putative new type of bovine papillomavirus in the Xi-papillomavirus 1 species in a Brazilian dairy herd. *Virus Genes*, **55**(5): 682-687.
- Hassanien RT, Hamdy ME, Elnomrosy SM, Hussein HA, Afify AF, Darwish FM, Shehab G, Emran R, Abd-El-Moniem MII, Habashi AR, Fahmy HA, Ibraheem EM, Shahein MA, Attya M, Abdelhakim AMM & Hagag NM (2021). Molecular characterization and pathological identification of a novel strain of delta papillomavirus-4 (bovine papillomavirus-2) in Egypt. *Veterinary World*, **14**(9): 2296-2305.
- Khan S, Akbar H, Rashid M, Younas M, Farooqi S, Rehman F, Badshah A & Azeem S (2022). Clinical management of cutaneous bovine papillomatosis in a cow calf: a case report. *Journal of the Hellenic Veterinary Medical Society*, **73**(2): 4261-4264.
- Khatab MS, Osman AH, AbuBakr HO, Azouz RA, Ramadan ES, Farag HS & Ali AM (2023). Bovine papillomatosis: A serological, hematobiochemical, ultrastructural and immunohistochemical investigation in cattle. *Pakistan Veterinary Journal*, doi.10.29261/pakvetj/2023.023.
- Mariz FC, Jesus ALS & Silva MAR (2016). The challenges inherent in the control and prevention of bovine papillomaviruses. *Austin Journal of Genetics and Genomic Research*, **3**(1): 10-17.
- Swamy Babu MV, Veena P, Suresh Kumar RV, Amaravathi P & Vani G (2020). Clinical, pathological and immunohistochemical bovine papillomatosis. *The Pharma Innovation Journal*, **9**(6): 243-246.