



Parasitism and rumen impaction in a 5-month-old Yankasa ewe: A clinico-pathological report

NA Sani^{1*}, AA Mobolaji¹, SE Abalaka¹, OZ Tenuche¹, MA Adeiza², CE Ejiofor³, RJ Lawal⁴, VO Kolawole⁵ & OD Olayemi³

1. Department of Veterinary Pathology, Faculty of Veterinary Medicine, University of Abuja, Abuja, Nigeria

2. Department of Veterinary Public Health and Preventive Medicine, Faculty of Veterinary Medicine, University of Abuja, Nigeria

3. Department of Parasitology and Entomology, Faculty of Veterinary Medicine, University of Abuja, Nigeria

4. Department of Veterinary Medicine, Faculty of Veterinary Medicine, University of Maiduguri, Nigeria

5. Department of Veterinary Medicine, Faculty of Veterinary Medicine, University of Abuja, Nigeria

*Correspondence: Tel.: +2348032176723; E-mail: nuhu.sani@uniabuja.edu.ng

Copyright: © 2023

Sani et al. This is an open-access article published under the terms of the Creative Commons Attribution License which permits unrestricted use, distribution, and reproduction in any medium, provided the original author and source are credited.

Publication History:

Received: 28-08-2023

Revised: 01-10-2023

Accepted: 09-10-2023

Abstract

We report concurrent acariosis, helminthosis and foreign body rumen impaction of multiple aetiologies in a 5-month-old Yankasa ewe from a multispecies flock on semi-intensive management system. The clinical findings were tachycardia, hypothermia, bradypnea, diarrhoea, emaciation, lethargy, pale mucous membranes, and heavy tick infestation attached to the skin of the forelimb, hind limb, inguinal region, and the ears. Severe non-regenerative anaemia, marked neutrophilia and lymphocytopenia characterized the blood picture. The ewe was treated for endo and ectoparasites, along with fluid therapy. However, the ewe died in the course of treatment and the carcass was subsequently presented for necropsy. Gross findings included the presence of numerous ticks attached to the skin of the outer ears and interdigits, indigestible foreign materials in the rumen and numerous worms in the rumen, abomasum and the intestine. Laboratory analysis revealed that the ticks were *Rhipicephalus* sp. and *Amblyomma* sp. The rumen worms were identified as *Paramphistomum* sp., the worms from the abomasum were identified as *Haemonchus contortus*, and those of the intestine were identified as *Moniezia expansa*. Histopathologically, there was hypertrophy of the chief cells of the abomasum. There was a section of *Haemonchus contortus* surrounded by eosinophils within the mucosa of the abomasum. The villi of the intestine sloughed-off into the lumen. Based on the clinicopathological findings, the diagnoses of acariosis, helminthosis and foreign body rumen impaction were arrived at. The remaining animals in the herd were treated accordingly and the farmer was advised to ensure good farm management practices.

Keywords: Acariosis; Helminthosis; Pathology; Rumen impaction; Yankasa Ewe

Introduction

Small ruminant production is popular among rural and peri-urban dwellers in Nigeria, contributing immensely to the socioeconomic and protein requirements of the populace. However, livestock

production is challenged by several factors, notably infectious and non-infectious diseases. Several species of hard ticks infest sheep leading to blood loss and transmission of some agents of diseases.

Helminths can parasitize small ruminants of all ages, occupying different predilection sites mostly within the gastrointestinal tract (GIT) of their host. Such infections cause clinical signs such as anorexia, reduced productivity, weight loss, stunted growth, anaemia or even death in severe cases (Yohanna *et al.*, 2019).

Rumen impaction is a condition that results from the accumulation of indigestible materials in the rumen characterized by distended ventral left abdomen, scanty or no faeces, and poor body condition (Rabana *et al.*, 2022). Diagnosis is by palpation and ballottement of the rumen during clinical examination of the live ruminant, rumenotomy, or at postmortem examination (Martin-Martel *et al.*, 2021).

Although multiple infestations with ecto- and endo-parasites have been reported in sheep (Atikum *et al.*, 2021), the authors did not come across any report on foreign body rumen impaction co-existing with acariasis and helminthosis of multiple aetiologies in Yankasa ewe, hence the need for this report.

Case Presentation

Clinical history

A 5-month-old Yankasa ewe weighing about 20 kg was brought to the University of Abuja Veterinary Teaching Hospital, Abuja with the chief complaint of diarrhoea, sternal recumbency and anorexia, which started five days before presentation. The ewe belonged to a multispecies flock comprising 48 sheep and 23 goats raised on semi-intensive management system, some of which showed similar signs of disease but albeit less severe. The clinicians could not ascertain the deworming and vaccination history of

the flock. The respiratory rate, heart rate, and temperature of the ewe were 15 cycles/minute, 100 beats/minute, and 38°C, respectively. The clinical signs observed included diarrhoea, soiled hind quarters, emaciation, lethargy, pale mucous membranes, and heavy tick infestation.

Haematological analysis revealed the presence of microcytic hypochromic anaemia, and leukocytosis characterized by neutrophilia and lymphocytopenia as shown in Table 1. Analysis of faecal sample revealed the presence of ova of *Trichostrongylus* sp., while the ticks were identified as *Rhipicephalus* sp. and *Amblyomma* sp. The results also revealed no haemoparasite on thin blood smear. Therefore, the clinical diagnoses were acariasis and helminthosis at ante-mortem. The ewe was treated with 500 ml of Hartsman solution subcutaneously, 1% ivermectin injection at 200 µg/kg SC, and albendazole (bolus) at 7.5 mg/kg per os stat. The other animals in the herd were also treated appropriately. However, the ewe died in the course of treatment and the carcass was presented for necropsy.

Gross and histopathological findings

The carcass was fresh and cachexic. There were brownish hard ticks attached to the skin of the inter-digits and outer ear. The hindquarters were soiled with loose faecal material. The ocular and oral mucous membranes were markedly pale. The peritoneal cavity contained about 200 ml of straw-coloured fluid. The rumen had a hard mass (Plate IA) that weighed 1.46 kg which comprised of polythene bags, ropes, and other unidentified indigestible materials.

Table 1: Haematological findings of the ewe diagnosed with parasitism and rumen impaction

Parameter	Result	*Reference range	Interpretation
PCV (%)	12	38.1-39.7	Low
Hb (g/dl)	4.1	11.1-12.0	Low
RBC ($\times 10^6/\mu\text{l}$)	3.3	12.3-13.4	Low
MCV (fl)	36.3	38.3-40.9	Low
MCH (pg)	10.4	11.4-11.5	Low
MCHC (g/dl)	30.2	31.3-32.2	Low
WBC ($\times 10^3/\mu\text{l}$)	18.0	12.2-12.9	High
Neutrophil ($\times 10^3/\mu\text{l}$)	11.2	3.4-4.3	High
Lymphocyte ($\times 10^3/\mu\text{l}$)	6.3	7.2-8.1	Low
Eosinophil ($\times 10^3/\mu\text{l}$)	0.0	0.0-0.61	Normal
Monocyte ($\times 10^3/\mu\text{l}$)	0.5	0.0-0.61	Normal
Basophil ($\times 10^3/\mu\text{l}$)	0.0	0.0-0.0	Normal

*Source: Egbe-Nwiyi *et al.* (2000).

Key: PCV = packed cell volume; Hb = haemoglobin; RBC = red blood cell; MCV = mean corpuscular volume; MCH = mean corpuscular haemoglobin; MCHC = mean corpuscular haemoglobin concentration; WBC = white blood cell

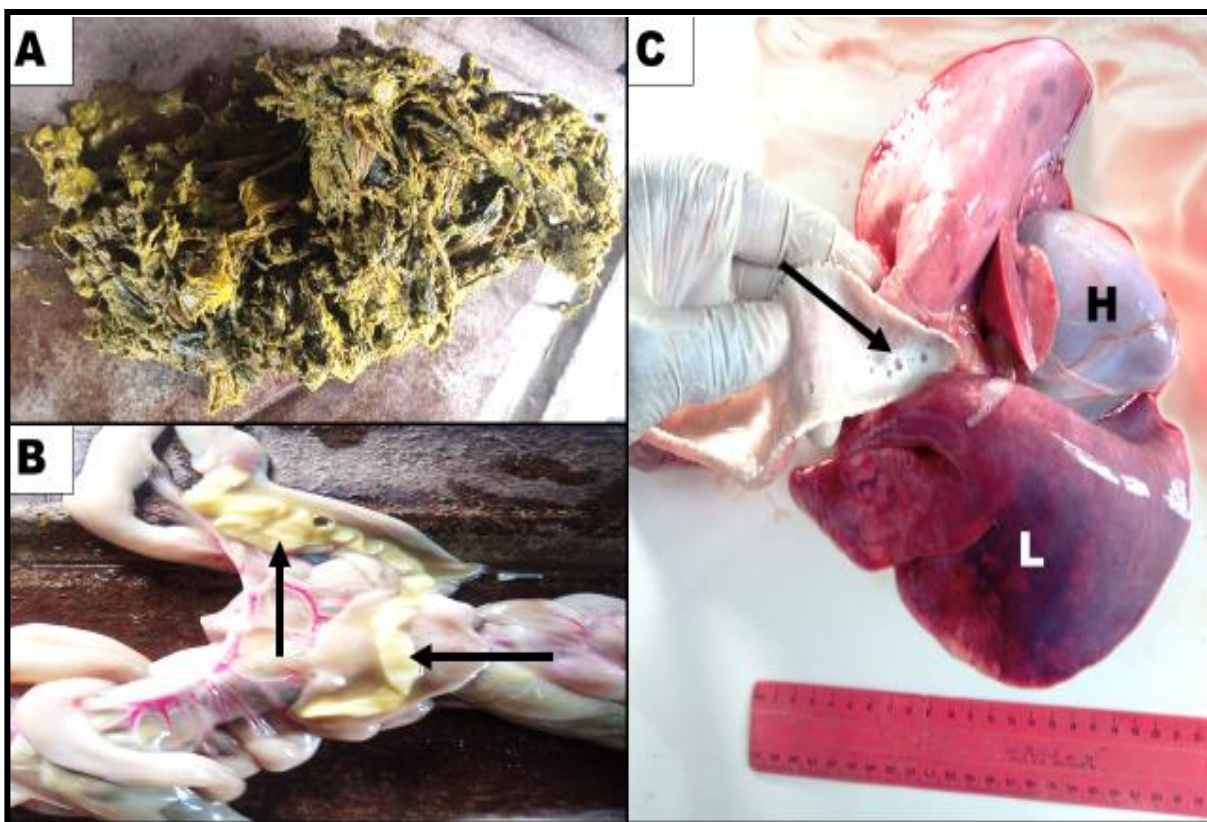


Plate I: Gross pathological changes in Yankasa ewe diagnosed with acariosis, helminthosis, and foreign body rumen impaction. A. Note the foreign materials from the rumen. B. Note the yellowish, long, flat, segmented worms (*Moniezia expansa*) within the lumen of the intestine (arrows). C. Note the copious froth within the lumen of the trachea (black arrow), severely congested and oedematous left lung (L), and cloudy pericardium (H)

There were numerous small pear-shaped reddish parasites on the mucosa of the rumen. There was moderate number of small, threadlike, reddish worms in the abomasum, while the lumen of the duodenum and ileum contained numerous whitish to creamy, segmented, long, flat worms (Plate IB). There were pinpoint hemorrhages on the mucosa of the small intestine. There were pinpoint hemorrhages on the cortex of the left kidney. There was moderate amount of froth within the trachea and the bronchi. The left lung was congested and oedematous (Plate IC) while the ventral aspect of the apical and middle lobes of the right lung had collapsed with visible interlobular septae. The pericardium was cloudy and contained 12 ml of straw-coloured fluid. There was serous atrophy of the pericardial fat and the heart was globous.

Tissue samples (lung, abomasum, and intestine) were fixed in 10% neutral buffered formalin and submitted to the Histopathology Laboratory of the Department of Veterinary Pathology, University of Abuja, Abuja for analysis according to standard procedure. There was hypertrophy of the chief cells within the

abomasum with a segment of *Haemonchus contortus* surrounded by eosinophils within its mucosa (Plate IIA and B). There was necrosis of the epithelium of the intestine while some intestinal villi had sloughed into the lumen (Plate IIC). There was oedema within the lumen of the bronchioles and alveolar spaces (Plate IID).

Samples for laboratory analyses and results

The ectoparasites and worms were submitted to the Parasitology and Entomology Laboratory, Department of Parasitology and Entomology, University of Abuja, Abuja, for identification, according to standard procedure. The identified ectoparasites were *Rhipicephalus evertsi* and *Amblyomma variegatum* whereas the worms from the rumen were identified as *Paramphistomum* sp, those from the abomasum were identified as *Haemonchus cotortus*, and those from the intestine were identified as *Moniezia expansa*.

The results led to a diagnosis of acariosis, helminthosis,, and foreign body rumen impaction of the ewe.

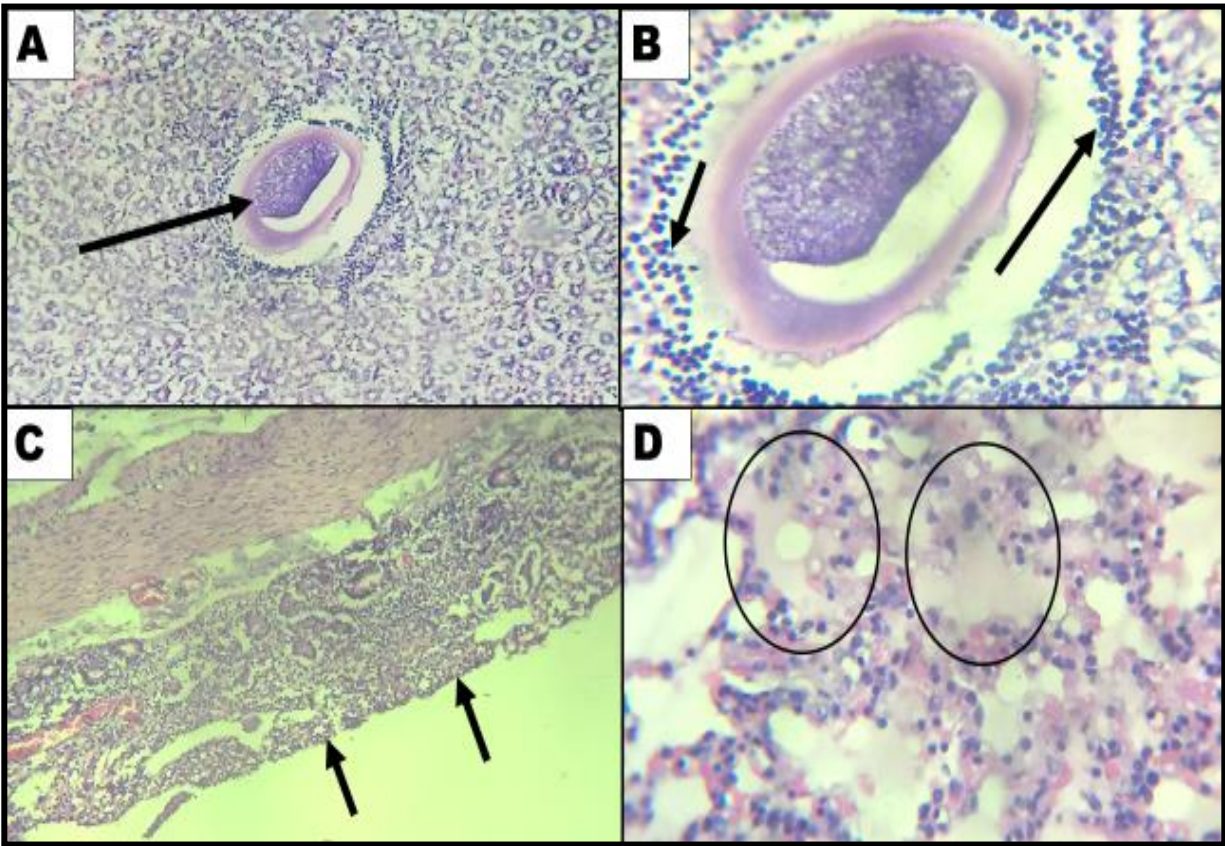


Plate II: Photomicrographs of histopathological changes in some tissues of the Yankasa ewe diagnosed with acariosis, helminthosis and foreign body rumen impaction. A. Note the segment of *Haemonchus contortus* (arrow) within the mucosa of the abomasum (H & E stain; ×200 magnification). B. Note the eosinophils (arrows) around the segment of the parasite (H & E stain; ×400 magnification). C. Note the flat mucosa of the intestine devoid of villi (arrows) (H & E stain; ×200 magnification). D. Note the oedema within the alveoli (oval) (H & E stain; ×400 magnification)

Discussion

When large numbers of ticks parasitize their host, they can cause anaemia due to their blood sucking activity. The indirect consequence of tick infestation could be the transmission of haemoprotozoans such as *Theileria* sp, *Babesia* sp, and *Anaplasma* sp (Bello *et al.*, 2017), each of which can be responsible for economically important diseases in sheep and other ruminants. Although no haemoparasite was detected in the blood of the affected ewe, the combination of the blood loss due to the tick infestation and *Haemonchus contortus* infection may have resulted in the severe non-regenerative anaemia observed in this case. Such hypochromic and microcytic anaemia in sheep diagnosed with haemonchosis have been reported (Abosse *et al.*, 2022), even though not as severe as what we observed in this case.

In this report, there was no gross pathology in association with the *Paramphistomum* spp in the rumen. The source of water for the animals in this

herd was a tributary of the Gwagwalada river, which serves as a watering point for many other herds from neighboring farms and even herds from other states migrating from the far North to the South in search of pasture. This scenario is well suited for disease transmission as animals from diseased herds may contaminate the water with eggs of parasites or other disease agents contained in their faeces or other excretions, which may then be consumed by healthy animals.

The major predisposing factors to foreign body rumen impaction in sheep and other ruminants is scarcity of free pasture especially during the dry season, and the indiscriminate disposal of wastes (Igbokwe *et al.*, 2003). Even during the rainy season where there is availability of free pasture to support semi-intensive and extensive management systems of production, the heightened level of insecurity, especially in the fringes as well as the increased cultivation of land to meet rising food demands have restricted access to

free pasture for ruminants. Therefore, such ruminants resort to refuse dumps in search of food, thereby ingesting non-digestible materials in the process. The materials accumulate in the rumen over time to impede feed consumption and utilization resulting in difficulty in breathing due to pressure exerted by the mass on the diaphragm and the lungs and obstruction of flow of oral medications to other parts of the GIT, among others (Alimi *et al.*, 2018). To mitigate problems associated with animal health and production in Nigeria, there is the need for a 'One Health' approach, resolving issues revolving around the causative agents, the host, and the environment. There is also the need for zero-grazing to prevent animals from consuming indigestible materials, and adopt a comprehensive parasite-control programme in the herd.

Funding

No funding was received.

Conflict of Interest

The authors declare that there is no conflict of interest.

References

- Abosse JS, Terefe G & Teshale BM (2022). Comparative study on pathological changes in sheep and goats experimentally infected with *Haemonchus contortus*. *Surgical and Experimental Pathology*, [doi.10.1186/s42047-022-00116-8](https://doi.org/10.1186/s42047-022-00116-8).
- Alimi OA, Buhari S, Lawal FM, Abdulkadir SZ, Amid SA, Adediran SO, Aliyu A & Asifat DA (2018). Rumen impaction in a 3½ – year old Balami ewe: case report and literature review. *Science World Journal*, **13**(1): 93-96.
- Atikum P, Osemeke H, Olaolu S, Gulek J, Takyun A, Paul K, Yakubu R & Weka R (2021). Gastrointestinal parasites infection among sheep in Bokkos Local Government Area of Plateau state, Nigeria. *Nigerian Journal of Animal Science*, **23**(2): 153-160.
- Bello AM, Lawal JR, Dauda J, Wakil Y, Mshelia ES, Abubakar MI & Biu AA (2017). Prevalence of haemoparasites in Balami sheep from Maiduguri, North-eastern Nigeria. *Direct Research Journal of Veterinary Medicine and Animal Science*, **2**(2): 28-35.
- Egbe-Nwiyi TN, Nwosu SC & Salami HA (2000). Haematological values of apparently healthy sheep and goats as influenced by age and sex in arid zone of Nigeria. *African Journal of Biomedical Research*, **3**(2): 109-115.
- Igbokwe IO, Kolo MY & Egwu GO (2003). Rumen impaction in sheep with indigestible foreign bodies in the semi-arid region of Nigeria. *Small Ruminant Research*, **49**(2): 141-146.
- Martin-Martel S, Morales M, Morales I, Jaber JR, Rodríguez-Guisado F, Tejedor-Junco MT & Corbera JA (2021). Pathological changes of the rumen in small ruminants associated with indigestible foreign objects. *Ruminants*, [doi.10.3390/ruminants1020009](https://doi.org/10.3390/ruminants1020009).
- Rabana JL, Bukola YZ, Mustapha M & Adamu L (2022). Indigestible foreign materials impaction of small ruminants in Gombe State, Nigeria. *Iranian Journal of Veterinary Medicine*, **16**(1): 1-14.
- Yohanna JA, Dung GK, Adejoh VA & Pam DD (2019). Prevalence of helminth parasites of ruminants in abattoir market Jos, Jos South Local Government Area, Plateau State, Nigeria. *International Journal of Biomedical and Health Sciences*, **15**(2): 51-57.