

Sokoto Journal of Veterinary Sciences



(P-ISSN 1595-093X; E-ISSN 2315-6201)

<http://dx.doi.org/10.4314/sokjvs.v20i3.9>



Gurumyen *et al.*/Sokoto Journal of Veterinary Sciences, 20(3): 216 - 218.

Biliary cystadenoma in an 8-year-old Caucasian bitch

GY Gurumyen^{1*}, EV Tizhe¹, TN Polycarp¹, LA Adekunle², AA Usman², TO Omadevuaye², MN Patrobas³, ES Unanam⁴, AJ Jubril², RE Antia² & VO Taiwo²

1. Department of Veterinary Microbiology and Pathology, Faculty of Veterinary Medicine, University of Jos, Jos, Plateau State, Nigeria
2. Department of Veterinary Pathology, Faculty of Veterinary Medicine, University of Ibadan, Ibadan, Oyo State, Nigeria
3. Department of Veterinary Parasitology and Entomology, Faculty of Veterinary Medicine, University of Jos, Jos, Plateau State, Nigeria
4. Department of Veterinary Medicine, Surgery and Radiology, Faculty of Veterinary Medicine, University of Jos, Plateau State, Nigeria

*Correspondence: Tel.: +2348030639783; E-mail: yilzemg@gmail.com

Copyright: © 2022 Gurumyen *et al.* This is an open-access article published under the terms of the Creative Commons Attribution License which permits unrestricted use, distribution, and reproduction in any medium, provided the original author and source are credited.

Abstract

Biliary cystadenoma is reported in an 8-year-old female Caucasian dog diagnosed by gross and microscopic examination. The gross lesion observed during postmortem examination on the liver was a 3×2cm cream-coloured raised nodule that extended into the parenchyma and another 2×4cm cyst filled with mucoid fluid. Histopathology showed multiloculated cysts lined by columnar and occasionally flattened epithelial cells, with papillary projections into the lumens. These findings are discussed in the paper.

Publication History:

Received: 16-02-2022

Revised: 19-07-2022

Accepted: 26-07-2022

Keywords: Benign tumour, Biliary cystadenoma, Caucasian, Dog, Liver

Introduction

Biliary cystadenoma, also called a cystic adenoma, bile duct adenoma, or cystic cholangioma is a rare benign cystic neoplasm which originates from the hepatic parenchyma and less often from the

extrahepatic bile ducts and gallbladder (Moon *et al.*, 2011). Patients with cystadenoma may be asymptomatic as the tumour is often seen as an incidental finding during radiological examination,

surgical investigation for other clinical indications or even postmortem examination (Nasrin *et al.*, 2012). Large, multiloculated biliary cystadenomas with internal septation and nodularity are frequently surrounded by a dense cellular fibrostroma (Averbukh *et al.*, 2019). Although cystadenomas can be unilocular in rare cases, multilocularity is a fundamental trait (Cho *et al.*, 2005). The tumour usually manifests histologically by focal or multicentric cystic proliferation of biliary epithelium involving one or more hepatic lobes (Adler & Wilson, 1995). This report documents a case of biliary cystadenoma in a Caucasian dog in Jos city, Nigeria.

Case Report

History

An 8-year-old Caucasian bitch was brought to the Veterinary Teaching Hospital, University of Jos, Jos, on the 19th September 2020 with a complaint of failure to get pregnant after several mating sessions during estrus or heat. The dog died within the period of clinical evaluation and was presented for postmortem examination.

Postmortem examination

The carcass showed moderate emaciation with pale oral, ocular and tracheal mucous membranes. The

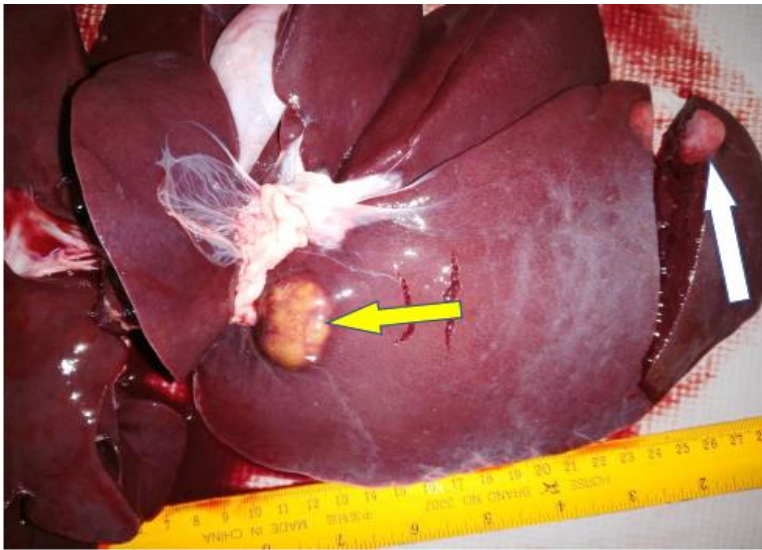

Plate I: Liver showing a cyst filled with clear mucoid fluid (yellow arrow) while the white arrow indicates a deep-seated nodule on the ventral aspect of the right lobe

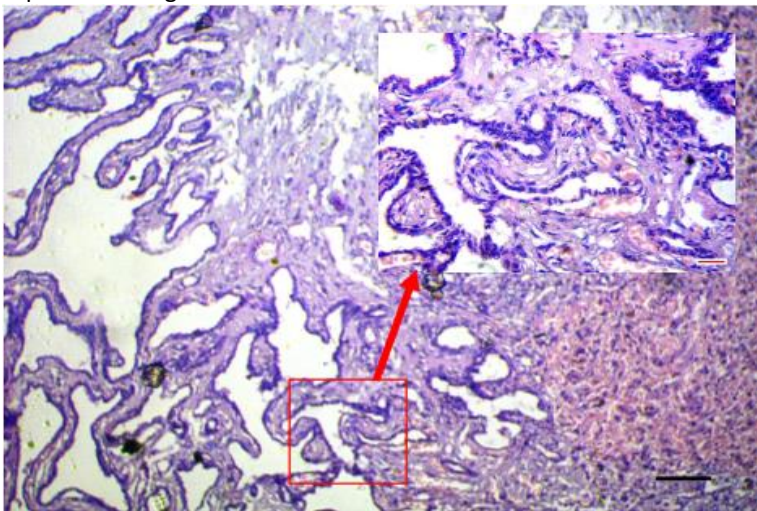


Plate II: Photomicrograph of liver cyst: multiloculated cysts of different sizes lined by columnar epithelial cells with papillary projections into the lumens. The cysts are separated by highly cellular fibrous connective tissues. H&E. Bar= 26.5mm

intestinal mucosa had ecchymotic haemorrhages, especially in the duodenum and jejunum. The ventral aspect of the right lateral lobe of the liver had a 3×2cm cream-coloured raised nodule that extended into the parenchyma and another 2×4cm cyst filled with mucoid fluid (Plate I). The kidneys were mildly shrunken with rough cortical surfaces and depressed areas. The cut surfaces of the renal cortex had fibrous tags.

Histopathology

Sections of the lesion on the liver was preserved in 10% buffered formalin solution and processed for microscopy after staining with hematoxylin and eosin. Histopathological examination of the liver lesion showed multiloculated cysts of different sizes lined by columnar and occasionally flattened epithelial cells with papillary projections into the lumens, suggestive of biliary cystadenoma (Plate II). The cysts were separated by fibrous connective tissues.

Discussion

This report describes biliary cystadenoma in an 8-year-old Caucasian bitch which is the first in the breed documented in this locality. There has been previous reports of biliary cystadenoma in three breeds of dogs; 8-year-old Maltese dog (Moon *et al.*, 2011), 13-year-old, Irish setter dog (Akkoç *et al.*, 2009) and 14-year-old female German Shepherd (Macri *et al.*, 2015). This condition was diagnosed in an 8-year-old female Caucasian dog in the present case. In humans, biliary

cystadenoma has been reported more in females (> 85 percent) than men, with an associated hormonal influence as a risk factor in women (Macri *et al.*, 2015). Grossly, the cyst, in this case, was observed in only one lobe (lateral right) of the liver. This is also similar to a previous report (Macri *et al.*, 2015) which confirmed the presence of a solitary cyst in a hepatic lobe using histopathology and immunohistochemistry. The histopathological features observed in this case are consistent with benign biliary cystadenoma (Cho *et al.*, 2005). The occurrence of the cyst on the right lobe of the liver is consistent with findings by Lewis *et al.* (1988) in which eight of the 15 biliary cystadenoma cases were found in the right lobe of the liver, five in the left, and only one in the medial regions of both lobes. Biliary cystadenomas are often reported as incidental finding (Macri *et al.*, 2015) just as in this case and may not be the primary cause of death.

Conclusion

A biliary cystadenoma is reported based on the characteristic gross and histological features as an incidental finding during a postmortem examination of a bitch dog. This may be the first case report of biliary cystadenoma in a dog in Nigeria.

Acknowledgement

We want to appreciate the efforts of Miss Ju Gye for processing the tissue for histopathological examination.

Funding

Nil

Conflict of Interest

The authors declare that there is no conflict of interest.

References

- Adler R & Wilson DW (1995). Biliary Cystadenoma of Cats. *Veterinary Pathology*, **32**(4): 415–418.
- Akkoç A, Cangül İT, ÖZYİĞİT MÖ (2009). Multicentric intrahepatic biliary cystadenoma in a dog. *Turkish Journal of Veterinary and Animal Sciences*, **33**(2):161-164.
- Averbukh LD, Wu DC, Cho WC & Wu GY (2019). Biliary mucinous cystadenoma: A review of the literature. *Journal of Clinical and Translational Hepatology*, **7**(2): 149-153
- Cho HS, Masangkay SJ, Kim YS & Park NY (2005). Biliary Cystadenoma in a Captive Japanese Macaque (*Macaca fuscata*). *Journal of Veterinary Clinics*, **22**(4): 401–403.
- Lewis WD, Jenkins RL, Rossi RL, Munson L, Remine SG, Cady B, Braasch JW & McDermott WV (1988). Surgical treatment of biliary cystadenoma: A report of 15 Cases. *Archives of Surgery*, **123**(5): 563–568.
- Macri B, Lanteri G, Capucchio M, Ieni A & Marino F (2015). A cystadenoma of the biliary ducts in a dog: Anatomico-histopathological features and pathogenetic considerations: A case report. *Veterinárni Medicína*, **60**(5): 288–291.
- Moon SJ, Kim JW, Sur JH, Jeong SW & Park HM (2011). Biliary cystadenoma in a Maltese dog: Clinical and diagnostic findings. *Journal of Veterinary Medical Science*, **73**(12): 1677–1679.
- Nasrin A, Baharak A & Reza K (2012). Concurrent cystic endometrial hyperplasia, ovarian luteoma and biliary cyst adenoma in an aged rabbit (*Oryctolagus cuniculus*): Case report and literature review. *Asian Pacific Journal of Tropical Biomedicine*, **2**(3): 1975–1978.