



## Evaluation of tracheal size in the Nigerian indigenous dog by radiologic morphometry

RO Ukaha<sup>1\*</sup>, KK Agwu<sup>2</sup> & ROC Kene<sup>3</sup>

1. Department of Veterinary Surgery & Radiology, College of Veterinary Medicine, Michael Okpara University of Agriculture, Umudike, Abia State, Nigeria
2. Department of Medical Radiography and Radiological Sciences, College of Medicine, Enugu Campus University of Nigeria, Nsukka, Enugu State, Nigeria
3. Department of Veterinary Surgery & Radiology, Faculty of Veterinary Medicine, University of Nigeria, Nsukka, Enugu State, Nigeria

\*Correspondence: Tel.: +234 8061530565; E-mail: ukaha.rock@mouau.edu.ng

**Copyright:** © 2022 Ukaha et al. This is an open-access article published under the terms of the Creative Commons Attribution License which permits unrestricted use, distribution, and reproduction in any medium, provided the original author and source are credited.

**Publication History:**  
Received: 18-05-2021  
Revised: 28-12-2021  
Accepted: 04-01-2022

Reproducible and easily applied methods of radiologic evaluation are needed in the day-to-day clinical practice for diagnosis and treatment (management) of tracheal disorders in animals. In the Nigerian Indigenous Dog, records of such measurements are either non-existent or invisible. The objective of this prospective cross-sectional study was to document measurement indices used for the evaluation of canine trachea. Thirty healthy Nigerian indigenous dogs of both sexes were used for the investigation. Plain right and left lateral thoracic radiographs of each research animal were obtained. The tracheal silhouette in each radiograph was objectively evaluated and adequately described. In the right and left lateral views, the sagittal diameter of the tenth vertebra, the thoracic inlet diameter, and the tracheal diameter were the parameters measured and recorded. Indices generated were the tracheothoracic ratio and tracheovertebral ratio. Results were described as means  $\pm$  standard errors of means while differences between mean values were subjected to student's t-test statistic using SPSS version 22 for windows. Statistical significance was established at  $P \leq 0.05$ . In the lateral radiographs, mean values of vertebral indices, tracheothoracic ratios, and tracheovertebral ratios for right/left lateral radiographs were  $0.21 \pm 0.01 / 0.21 \pm 0.01$ , and  $0.92 \pm 0.12 / 0.92 \pm 0.11$ , respectively. Using the right lateral and dorsoventral orthogonal views, the fronto-sagittal and Haller index's mean values were  $1.05 \pm 0.04$  and  $0.95 \pm 0.04$ , respectively. The indices generated in the present study are considered adequate and recommended for morphological evaluation of the canine tracheal silhouette. The tracheovertebral ratio was established for the first time in the present research. The results of this work are reproducible, objective and easy to apply in small animal clinical practice.

**Keywords:** Diagnostic indices, Nigerian dog, Thoracic measurement, Radiology

## Introduction

The trachea, also referred to as the windpipe, is a cartilaginous tube that extends from the lower border of the cricoid cartilage of the larynx to the carina, its bifurcation, the point where the trachea branches into right and left principal or main-stem bronchi (Holbert & Strollo, 1995; Furlow & Mathisen). The trachea is located a little to the right of the midline in ventrodorsal views. However, in lateral projections, it is slightly parallel to the cervical vertebrae and divergent ventrally from the thoracic spine to the carina (Kneller, 2007; Alexander, 2013). The trachea runs side by side with the oesophagus and delivers air to the lungs. Indications of tracheal evaluation are usually respiratory distress and obstruction. Right or left lateral and ventrodorsal orthogonal cervico-thoracic radiography usually adequately demonstrates the canine tracheal tree. Masses in the neck muscles, cranial mediastinum and base of heart can cause tracheal shift, narrowing, and collapse (Essman *et al.*, 2002). Tracheal bifurcation is displaced dorsally in left-sided cardiac enlargement and ventrally in the organomegaly of the tracheobronchial lymph glands, whereas in the persistent right fourth aortic arch, the trachea is displaced to the left (Buchanan, 2004). Tracheal masses are generally luminal, solitary and distinct and are well visualized due to the negative contrast of the surrounding air. Foreign bodies in the dog, including tooth, stone, bone, kibble or plant material, are most often lodged at the carina, recovered from the trachea resulting from orotracheal aspiration; retrieval of these foreign bodies in the dog using fluoroscopically guided forceps is preferred to bronchoscopy (Lotti & Niebauer, 1992; Tivers & Moore, 2006; Volta *et al.*, 2007).

Tracheal rupture and avulsion have been reported to be associated with complete circumferential tracheal discontinuity cranial to the carina, resulting in focal, well-defined, spherical dilation of the tracheal lumen. The lesion is visualized as a thin, soft tissue opacity margin that could be intact tracheal adventitia or surrounding mediastinal tissue (Mitchell *et al.*, 2000; White & Burton, 2000). Tracheal diverticulum and stenosis are complications of the same causes that predispose to tracheal rupture and avulsion and surgery (White & Burton, 2000; Mattoon & Drost, 2004). Tracheal stenosis, be it generalized or localized, may be caused by thickening of the tracheal mucosa due to severe tracheitis or by annular tracheal narrowing due to neoplasia (Fasanella *et al.*, 2010).

Tracheal collapse syndrome, a chronic progressive respiratory disease with chronic cough and other upper respiratory obstruction clinical signs, is most commonly seen in mature small and toy breed dogs (Buback *et al.*, 1996; Johnson & Pollard, 2010; Sura & Durant, 2012; Tappin, 2016). Two processes that are associated with tracheal luminal narrowing have been reported, namely: (a) dynamic airway obstruction due to chondromalacia of tracheal cartilages and weakened trachealis muscles, and (b) static airway obstruction due to abnormal tracheal cartilages malformed into "W" shape (Weisse, 2015; Weisse *et al.*, 2019). A trachea may be compressed by a mass lesion such as an enlarged lymph gland, tumour, large thyroid goiters, or unusually swollen blood vessels (Ralston *et al.*, 2018). Tracheal stenosis can be located anywhere in the neck region, chest region, or within the entire length of cervico-thoracic trachea, including the principal bronchi (LaRosa, 2021).

Tracheal collapse is rare in the cat, but feline primary tracheal collapse has been reported secondary to an extra-tracheal mass effect and intra-tracheal pressure changes caused by upper airway obstruction (Hendricks & O'Brien, 1985; Fujita *et al.*, 2004; Mims *et al.*, 2008).

Radiography is the first step in diagnosing a collapsing trachea. However, radiographs do not detect a hundred percent of the cases because collapsed tracheas are not always flattened, and a radiographic image only captures one event at a point in time. For this reason, fluoroscopy is preferred to radiographs and the imaging modality of choice for the assessment of tracheal and principal bronchial collapse (LaRosa, 2021). Fluoroscopically-guided endoluminal tracheal stenting is now frequently used to treat tracheal collapse. However, a complete fluoroscopic evaluation should be made before stenting to fully characterize the extent of the collapse and rule out main-stem bronchi involvement. The appropriate stent size to use should be selected with the help of images obtained during positive-pressure maximal tracheal dilation with a radio-opaque measurement device. Possible stent fracture and migration are a reason for follow-up radiographic evaluation. The stent edges should be checked for overgrowth of exuberant granulation tissue (Moritz *et al.*, 2004; Sura & Krahwinkel, 2008). Available records on the canine trachea are predominantly reported in exotic breeds; and there is no visible published result such as measurement index for correction, management and treatment of

tracheal size associated structural defects in the Nigerian Indigenous Dog.

### Materials and Methods

Thirty Nigerian Indigenous dogs (NID), aged  $\geq 7$  months with an average body weight  $8.19 \pm 2.45$  kg (range: 4.0 – 15.6 kg), and comprising equal number of both sexes, were used for the research. The animals were quarantined, fed, screened for diseases, and subjected to general examinations. Only healthy dogs were used for the study. The research animals were individually restrained with xylazine hydrochloride (XYL-M2<sup>®</sup>: VMD, Belgium) given at 2mg/kg intramuscularly and positioned for radiography with the help of leg-ties, sandbags, without any manual assistance. Laterolateral plain thoracic projections, namely: right lateral (RtL) and left lateral (LeL) projections, of each research animal were obtained at inspirational phase using a mobile X-ray machine (Dean Dynamax 40, GEC Medical Equipment Group Ltd, England). The focus-film-distance and object-film-distance were set at 90 cm and 0 cm, respectively, for all the exposures. Other exposure factors were variously selected due to differences in thoracic thicknesses of individual dogs. X-ray films (Begood<sup>®</sup>, China), cassettes and screens (NACAL Medical, England), processing chemicals (Begood<sup>®</sup>, China), an X-ray illuminator (fluorescent viewing-box), a standard metre rule and a weighing scale were also used.

The entire canine thorax, in each view, from the first rib to the first lumbar vertebra was collimated into the X-ray field, and the X-ray beam was centred at the

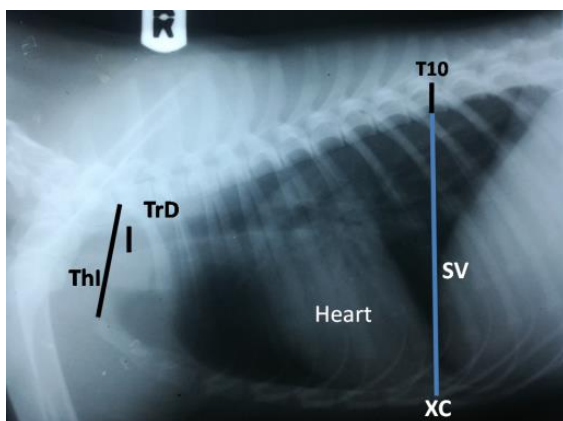
midpoint of the fourth intercostal space (Ettinger & Suter, 1970; Douglas *et al.*, 1987). The exposed films were processed, placed in pre-labelled envelopes and stored.

Radiographic measurements were taken in centimetres with the meter rule using the fluorescent viewing box. Parameters measured were the following: (a) Thoracic inlet diameter (ThI), measured distance between the cranioventral edge of first thoracic vertebra (T1) and craniodorsal end of the first sternebra (Figures 1a and b); (b) Tracheal diameter (TrD), measured transverse width of trachea at the thoracic inlet (Figures 1a and b); (c) Vertebral diameter (VD), a measured sagittal diameter of vertebral body, taken from dorsal surface to ventral border of the tenth thoracic vertebra, T10 (Figures 1a and b); and Sternovertebral distance (SV), measured distance in line with VD from the ventral border of T10 to the dorsal border of the xiphoid cartilage, XC (Figures 1a and b).

The measured dimensions were used to generate radiographic indices for tracheal evaluation in the NID namely: Tracheothoracic ratios (TTR), given by  $TTR = TrD \div ThI$  and Tracheovertebral ratio (TVR), calculated by  $TVR = TrD \div VD$  (Figures 1a and b).

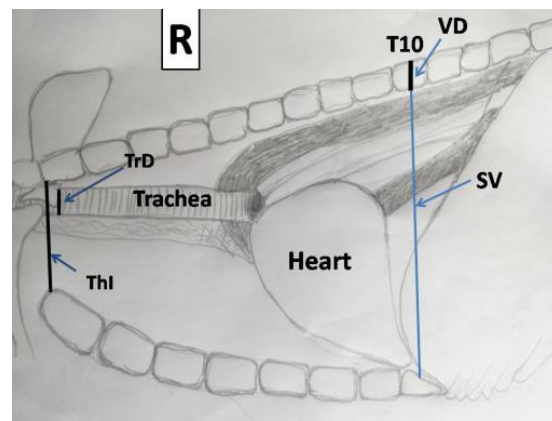
### Data analysis

Data obtained were presented in figures and tables, and expressed in descriptive statistics. Differences between mean values obtained in the right lateral RtL versus left lateral LeL views of males and females, and adult dogs and puppies were analyzed with the student's t-test statistic using SPSS version 22 for



**Figure 1a:** Right lateral thoracic radiograph of healthy Nigerian Indigenous Dog demonstrating measurements of parameters used to calculate tracheal ratios

TrD = tracheal diameter, ThI = thoracic inlet distance, SV = sternovertebral distance, VD= transverse width of the tenth vertebra, T10, XC = xiphoid cartilage (last sternebra)



**Figure 1b:** Annotated diagram of lateral thoracic radiograph of the Nigerian Indigenous Dog demonstrating measurements of parameters used to calculate tracheal ratios

windows. The means, ranges, and standard errors of means of the radiographic indices evaluated in the present research were calculated for each sex, age bracket separately and for all animals pooled. The pooled index variances were also determined. A probability value  $P \leq 0.05$  was considered statistically significant.

**Results**

Illustrated in Table 1, mean tracheothoracic (TTR) values were not varied between right lateral (RtL) and left lateral (LeL) thoracic projections and also between results obtained for both sexes. However, the TTR means were slightly greater in puppies than the mean values obtained for adult dogs in both RtL and LeL radiographs. As shown in Table 2, Tracheovertebral ratio (TVR) mean obtained in RtL views was slightly greater than the mean value for LeL projections. It is equally seen in the table that, in both

lateral sets of views, the female TVR mean ratios were greater than the mean values obtained in male lateral radiographs. Between the ages, however, adult TVR means were greater than the respective values recorded for puppies in both RtL and LeL radiographs. In Table 3, the pooled sample, sex, age results and associated index variances are presented for easy comparison. The pooled TTR ratio variances were much more negligible than values obtained for TVR; and between projections, RtL variances were less than LeL values.

**Discussion**

In the present study, we found that evaluation of the trachea was easiest in lateral radiographs and equally felt that the ventrodorsal view would be more useful for its displacement assessment. The trachea diverges slightly from the thoracic spine because of the dorsal angulation of thoracic vertebrae, and the trachea

**Table 1a:** Tracheothoracic ratio (TTR) in lateral thoracic radiographs of the Nigerian Indigenous Dog; TTR= TrD/ThI (Mean ± SEM)

Tracheothoracic Indices	Right Lateral Views	Left Lateral Views
TrD	0.97±0.03	0.96±0.03
ThI	4.61±0.12	4.62±0.12
TTR	0.21±0.01	0.21±0.01

Mean ratios were not significantly different from each other ( $P \geq 0.05$ )

**Table 1b:** Sex and age differences in TTR in lateral thoracic radiographs of the Nigerian Indigenous Dog; TTR= TrD/ThI (Mean ± SEM)

Sex differences				
Tracheothoracic Indices	RtL Views (Females)	LeL Views (Females)	RtL Views (Males)	LeL Views (Males)
TrD	1.03±0.04	1.02±0.04	0.91±0.04	0.90±0.03
ThI	4.82±0.18	4.85±0.18	4.39±0.15	4.38±0.15
TTR	0.21±0.01	0.21±0.01	0.21±0.01	0.21±0.01
Age differences				
Tracheothoracic Ratios	Right Lateral Views (Adults)	Left Lateral Views (Adults)	Right Lateral Views (Puppies)	Left Lateral Views (Puppies)
TrD	1.01±0.03	1.00±0.03	0.89±0.11	0.89±0.11
ThI	4.85±0.13	4.85±0.13	4.12±0.48	4.15±0.49
TTR	0.21±0.01	0.21±0.01	0.22±0.03	0.21±0.03

Mean ratios between RtL/LeL views and both sexes were not significantly different from each other ( $P \geq 0.05$ )

Mean ratios between RtL/LeL views and both ages were not significantly different from each other ( $P \geq 0.05$ )

**Table 2a:** Tracheovertebral ratios (TVR) in lateral thoracic radiographs of the Nigerian Indigenous Dog; TVR= TrD/VD (Mean ± SEM)

Tracheovertebral Indices	Right Lateral Views	Left Lateral Views
VD	1.06±0.13	1.05±0.11
TrD	0.97±0.17	0.96±0.16
TVR	0.92±0.12	0.92±0.11

Mean indices were not significantly different from each other ( $P \geq 0.05$ )

**Table 2b:** Age and sex differences in TVR in lateral thoracic radiographs of the Nigerian Indigenous Dog; TVR= TrD/VD (Mean ± SEM)

Sex differences				
Tracheothoracic Indices	Right Lateral Views (Females)	Left Lateral Views (Females)	Right Lateral Views (Males)	Left Lateral Views (Males)
VD	1.07±0.11	1.05±0.11	1.05±0.15	1.04±0.12
TrD	1.03±0.17	1.02±0.17	0.91±0.15	0.90±0.12
TVR	0.96±0.11	0.97±0.12	0.87±0.11	0.87±0.09
Age differences				
Tracheothoracic Ratios	Right Lateral Views (Adults)	Left Lateral Views (Adults)	Right Lateral Views (Puppies)	Left Lateral Views (Puppies)
VD	1.09±0.10	1.09±0.07	0.99±0.17	0.96±0.13
TrD	1.01±0.13	1.00±0.14	0.89±0.21	0.89±0.17
TVR	0.93±0.10	0.91±0.12	0.89±0.12	0.89±0.13

Mean indices between RtL/LeL views and both sexes were not significantly different from each other (P≥0.05)

Mean indices between RtL/LeL views and both ages were not significantly different from each other (P≥0.05)

**Table 3:** Summary of sex and age differences in tracheal indices

	TTR (RtL/LeL) Mean±SEM (Range)	TVR (RtL/LeL) Mean±SEM (Range)
Male (n = 15)	0.21±0.03/0.21±0.02 (0.16-0.26/0.17-0.24)	0.87±0.01/0.87±0.00 (0.73-1.10/0.73-1.00)
Female (n = 15)	0.21±0.03/0.21±0.03 (0.19-0.28/0.18-0.27)	0.96±0.01/0.97±0.02 (0.78-1.11/0.73-1.82)
Adult (n = 20)	0.21±0.02/0.20±0.02 (0.18-0.26/0.17-0.25)	0.93±0.01/0.91±0.02 (0.75-1.10/0.73-1.30)
Puppy (n = 10)	0.22±0.04/0.22±0.03 (0.16-0.28/0.19-0.27)	0.89±0.02/0.89±0.02 (0.75-1.11/0.73-1.08)
Pooled (n = 30)	0.21±0.03/0.21±0.03 (0.16-0.28/0.17-0.27)	0.92±0.01/0.92±0.02 (0.75-1.11/0.73-1.18)
Pooled var	0.0007/0.0006	0.0117/0.0127

tracheothoracic ratio (TTR) and tracheovertebral ratio (TVR); n = number of radiographs studied; SEM = standard error of mean, var = variance

Sex and age mean ratios between RtL and LeL views not significantly different from each other (P≥0.05)

angles slightly ventrally at the carina. If a mature dog exhibits persistent clinical signs of respiratory distress in spite of adequate drug treatment (with antibiotics, antitussives, corticosteroids, sedatives), surgical intervention may be necessary as a salvage procedure (Weisse, 2015). The commonest procedure is placement of extra-luminal ring prostheses (limited mostly to the cervical trachea) and endo-luminal tracheal stent (Weisse, 2015; LaRosa, 2021). Precise radiographic and/or physical measurements of tracheal diameter are important for proper stent sizing decisions before the management of tracheal collapse syndrome and for the selection of accurate endotracheal tube sizes during surgeries involving gaseous anaesthesia (Shigeki *et al.*, 2010; Violette *et al.*, 2019). Preoperative measurement of tracheal width has also been used to determine appropriate sizes of double-lumen endobronchial tubes for

patients undergoing various thoracic surgical procedures (Brodsky *et al.*, 1999).

In the present study, the Nigerian Indigenous Dog's indices determined for tracheal evaluation were tracheothoracic ratios (TTR) and tracheovertebral ratio (TVR). There was no statistical difference (p≤0.05) in the TTR and TVR mean ratios obtained in right lateral (RtL) versus left lateral (LeL) recumbent radiographs investigated, index means for male versus female dogs, and for puppies versus adult dogs. Non-bulldog brachycephalic breeds have a smaller tracheal diameter-to-thoracic inlet ratio of 0.16±0.03 than brachycephalic dogs with 0.20±0.03, while Bulldogs have an even smaller TTR of 0.13±0.04 based on records by Harvey & Fink (1982) and Dennis *et al.* (2010). From these publications, only the brachycephalic TTR results are well comparable with the results of the present research. The low pooled

index variances (or negligible levels of difference from expected means) obtained in the present study, especially for TTR, point to the efficiency of these indices in tracheal evaluation using these views (Gardner *et al.*, 2007). It has been proved that extramural cervical, cranial mediastinal and heart-based masses can cause tracheal displacement, narrowing, and collapse (Fasanella *et al.*, 2010). These scientists equally reported that tracheal hypoplasia appears as a generalized reduction in tracheal diameter and is caused by apposed or overlapping tracheal cartilages and a shortened or absent dorsal tracheal membrane common in brachycephalic dogs. Another group of authors also discovered that generalized tracheal narrowing was caused by severe tracheitis (which, in turn, was caused by inhalation of toxic or chemical irritants, trauma, or upper respiratory infections) and led to thickening of the tracheal mucosa (Macready *et al.*, 2007). Whatever the aetiology, abnormal change in tracheal diameter is easily evaluated or diagnosable with the TTR and TVR indices. The diameter of the trachea is relatively uniform, slightly smaller than that of the larynx, and does not vary in diameter significantly between respiratory phases (inspiration and expiration). The tracheal diameter is similar between the cervical and thoracic regions but occasionally widens caudally in the cervical region in large dog breeds. In a study conducted by Violette *et al.* (2019) using six different dog breeds (Yorkshire terrier, Pomeranian, Maltese, Pug, Shih-Tsu, and Yorkie-poo), the mean ( $\pm$ SD) maximal cervical, thoracic inlet, and intra-thoracic tracheal diameters for the entire study population were  $9.99\pm 1.46$ mm,  $8.70\pm 1.81$ mm,  $7.60\pm 1.20$ mm, respectively. These results, though they do not represent any breed in particular, are similar to our thoracic inlet mean tracheal diameter value.

Variable tracheal luminal narrowing in dogs can be caused by a redundant trachealis dorsalis membrane, between the mid-cervical and mid-thoracic portions of the trachea. Tracheal chondromalacia and collapse syndrome are seen commonly in middle-aged and older small- and toy breed dogs with chronic coughing as a clinical sign (Sura & Durant, 2012; Tappin, 2016). The extent of collapse is usually assessed as a percentage ranging from 25 to 100% of the tracheal-diameter-reduction scale, similar to the grading system used in bronchoscopy for tracheal collapse evaluation. In this scale, a tracheal diameter reduction of 25% or less is likely within normal limits of variation of the respiratory cycle (Macready *et al.*, 2007). Endoluminal stenting through fluoroscopic guidance has become commonplace for the

treatment of tracheal collapse. Before stenting, a complete fluoroscopic evaluation should be made to characterize the extent of collapse fully and rule out main stem bronchi involvement. Images made during positive-pressure maximal tracheal dilation with a radio-opaque measurement device help to determine the appropriate stent size. During follow-ups, the stent should be evaluated for fracture and migration, and the trachea for exuberant granulation tissue at the edges of the stent (Moritz *et al.*, 2004; Sura & Krahwinkel, 2008; Mims *et al.*, 2008).

In conclusion, the authors consider the indices generated in the present study adequate and recommend them for morphological assessment of the tracheal silhouette in the NID. The tracheovertebral ratio (TVR) was established probably, for the first time in the present research. The results of this research are easily reproducible and objective if applied in small animal clinical practice.

## References

- Alexander K (2013). The Pharynx, Larynx and Trachea. In: *Textbook of Veterinary Diagnostic Radiology*, Sixth edition, (DE Thrall, editor). Elsevier Saunders, St Louis. Pp 489-498.
- Brodsky JB, Macario A & Mark JBD (1999). Tracheal diameter predicts double-lumen tube size: a method for selecting left double-lumen tubes. *Anesthesia and Analgesia* **82**(4): 861-864.
- Buback JL, Boothe HW & Hopson HP (1996). Surgical treatment of tracheal collapse in dogs: 90 cases (1983-1993). *Journal of American Veterinary Medical Association*, **208**(3): 380-384.
- Buchanan JW (2004). Tracheal signs and associated vascular anomalies in dogs with persistent right aortic arch. *Journal of Veterinary Internal Medicine*, **18**(4): 510-514.
- Dennis R, Kirberger RM, Barr F & Wrigley RH (2010). Lower Respiratory Tract. *Handbook of Small Animal Radiology and Ultrasound: Techniques and Differential Diagnoses*, Second edition. Saunders Elsevier Inc, London. Pp 145 -171.
- Douglas SW, Herrtage ME & Williamson HD (1987). *Principles of Veterinary Radiology*, fourth edition. Bailliere Tindall, London. Pp 211-225.
- Essman SC, Hoover JP & Bahr RJ (2002). An intrathoracic malignant peripheral nerve

- sheath tumour in a dog. *Veterinary Radiology and Ultrasound*, **43**(3): 255-259.
- Ettinger SJ & Suter PF (1970). *Radiographic Examination in Canine Cardiology*. WB Saunders Co., Philadelphia. Pp 156-167.
- Fasanella FJ, Shivley JM & Wardlaw JL (2010). Brachycephalic airway obstructive syndrome in dogs: 90 cases (1991-2008). *Journal of American Veterinary Medical Association*, **237**(9): 1048-1051.
- Fujita M, Miura H & Yasuda D (2004). Tracheal narrowing secondary to airway obstruction in two cats. *Journal of Small Animal Practice*, **45**(1): 29.
- Furlow, PW & Mathisen DJ (2018). Surgical anatomy of the trachea. *Annals of Cardiothoracic Surgery*, **7**(2): 255-260.
- Gardner A, Thompson MS, Heard DJ, Fontenot D & Gibson N (2007) Radiographic evaluation of cardiac size in flying fox species (*Pteropus rodricensus*, *P. hypomenalus* and *P. vampyrus*), *Journal of Zoo & Wildlife Medicine* **38**(2): 192-200.
- Harvey C & Fink E (1982). Tracheal diameter: Analysis of radiographic measurements in brachycephalic and nonbrachycephalic dogs. *Journal of American Animal Hospital Association*, **18**(4): 570-576.
- Hendricks JC & O'Brien JA (1985). Tracheal collapse in two cats. *Journal of American Veterinary Medical Association*, **187**(4): 418-419.
- Holbert JM & Strollo DC (1995). Imaging of the normal trachea. *Journal of Thoracic Imaging*, **10**(4): 171-176.
- Johnson LR & Pollard RE (2010). Tracheal collapse and bronchomalacia in dogs: 58 cases (7/2001-1/2008). *Journal of Veterinary Internal Medicine*, **24**(2): 298-305.
- Kneller SK (2007). Larynx, Pharynx, and Trachea. In: *Textbook of Veterinary Diagnostic Radiology*, Fifth edition (DE Thrall, editor). Saunders Elsevier, St Louis. Pp 489-494.
- LaRosa A (2021). Tracheal Collapse: Medical Management Versus Implantable Stents. Veterinary Health Center, University of Missouri. <http://vhc.missouri.edu/small-animal-hospital/>, retrieved 03-09-2021.
- Lotti U & Niebauer G (1992). Tracheobronchial foreign bodies of plant origin in 153 hunting dogs. *Compendium on Continuing Education for Practising Veterinarians*, **14**(7): 900-905.
- Macready DM, Johnson LR & Pollard RE (2007). Fluoroscopic and radiographic evaluation of tracheal collapse in dogs: 62 cases (2001-2006). *Journal of American Veterinary Medical Association*, **230**(12): 1870-1876.
- Mattoon JS & Drost WT (2004). Radiographing the trachea in small animals. *Veterinary Medicine*, **99**(1): 72-84.
- Mims HL, Hancock RB, Leib MS & Waldron DR (2008). Primary tracheal collapse in a cat. *Journal of American Animal Hospital Association*, **44**(3): 149-153.
- Mitchell S, McCarthy R & Rudloff E (2000). Tracheal rupture associated with intubation in cats: 20 cases (1996-1998). *Journal of American Veterinary Medical Association*, **216**(10): 1592-1595.
- Moritz A, Schneider M & Bauer N (2004). Management of advanced tracheal collapse in dogs using intraluminal self-expanding biliary wall stents. *Journal of Veterinary Internal Medicine*, **18**(1): 31-42.
- Ralston SH, Penman ID, Strachan MW & Hobson RP (2018). *Davidson's Principles and Practice of Medicine*, Twenty-third edition. Elsevier. <https://www.elsevier.com/books/>, retrieved 03-09-2021.
- Shigeki S, Ryohei S, Junya K, Shizuko K, Hirofumi A, Kazuichi Y & Junzo T (2010). Comparison of tracheal diameter measured by chest X-ray and by computed tomography. *Anaesthesiology Research and Practice*, [doi.10.1155/2010/269171](https://doi.org/10.1155/2010/269171).
- Sura P & Durant AM (2012). Trachea and Bronchi. In: *Veterinary Surgery: Small Animal*. Vol 2, First edition (KM Tobias, SA Johnston SA, editors). Elsevier Saunders, St Louis. Pp 1746-1750.
- Sura PA & Krahwinkel DJ (2008). Self-expanding nitinol stents for the treatment of tracheal collapse in dogs: 12 cases (2001-2004). *Journal of American Veterinary Medical Association*, **232**(2): 228-236.
- Tappin SW (2016). Canine tracheal collapse. *Journal of Small Animal Practice*, **57**(1): 9-17.
- Tivers MS & Moore AH (2006). Tracheal foreign bodies in the cat and the use of fluoroscopy for removal: 12 cases. *Journal of Small Animal Practices*, **47**(3): 155-159.
- Violette NP, Weisse C, Berent AC & Lamb KE (2019). Correlations among tracheal dimensions, tracheal stent dimensions, and major complications after endoluminal stenting of tracheal collapse syndrome in dogs. *Journal of Veterinary Internal Medicine*, **33**(5): 2209-2216.

- Volta A, Piccionello AP & Bonazzi M (2007). What is your diagnosis? Bronchial foreign body. *Journal of American Veterinary Medical Association*, **230**(2): 191-192.
- Weisse C (2015). Intraluminal Tracheal Stenting. In: *Veterinary Image-Guided Interventions, First edition* (C Weisse, A Berent, editors). Wiley Blackwell, Ames AI. Pp 73-78.
- Weisse C, Berent A, Violette N, McDougall R & Lamb K (2019). Short-, intermediate, and long-term results for endoluminal stent placement in dogs with tracheal collapse. *Journal American Veterinary Medical Association*, **254**(3): 380-392.
- White RN & Burton CA (2000). Surgical management of intrathoracic tracheal avulsion in cats: Long term results in 9 consecutive cases. *Veterinary Surgery*, **29**(5): 430-435.