



Endoparasitism in commercial quails around Umuahia, Abia State, Nigeria

A Onyeabor & EC Uwalaka*

Department of Veterinary Parasitology and Entomology, College of Veterinary Medicine, Michael Okpara University of Agriculture, Umudike, Nigeria

*Correspondence: Tel.: +2348037749097; E-mail: emmauwalaka@gmail.com

Copyright: © 2021 Onyeabor & Uwalaka. This is an open-access article published under the terms of the Creative Commons Attribution License which permits unrestricted use, distribution, and reproduction in any medium, provided the original author and source are credited.

Publication History:
Received: 09-04-2021
Revised: 02-08-2021
Accepted: 12-08-2021

Keywords: Coccidia, Gastrointestinal parasites, Helminths, Nigeria, Prevalence, Quails

Abstract

The enteric parasites of quails in Umuahia were investigated to determine their prevalence. Three hundred faecal samples, collected on voiding, were screened, with two hundred and five of them from deep litter and ninety-five from cages. Faecal analysis was conducted using the flotation and McMaster techniques. The overall prevalence of helminth infection was 167(55.6%) while that for coccidian oocysts was 89(29.6%). The prevalence of the nematode parasites detected in this study includes *Ascaridia* spp. 63(21.0%), *Heterakis* spp. -41(13.6%), *Capillaria* spp. -33(11.0%), *Syngamus* spp. 20(6.6%) and *Strongyloides* spp. 10(3.3%). The age-wise prevalence of gastrointestinal nematodes in young and adult quails was 41(42.2%) and 126(62.0%) respectively. Also, 33(34.0%) and 56(27.5%) young and adult quails were infected with coccidian oocysts, respectively. Enteric nematode parasites found in the cage managed and deep litter managed quails were 31(32.6%) and 136(66.3%) respectively. Also, 63(30.7%) and 26(27.3%) deep litter and cage managed quails respectively were infected with coccidian oocytes. It was concluded that gastrointestinal nematode and coccidian infections of quails are common in quails in Umuahia area regardless of the management system. This necessitates appropriate sustainable control measures to enhance a profitable poultry enterprise.

Introduction

As the world human population increases, demand for the protein of animal origin becomes a vital component of nutrients. Meeting this demand can be achieved by poultry production, which is the most efficient and economic means, due to the relatively small capital required to start and the minimum period required to maturity of the birds (Udoh *et al.*, 2014). Quail farming, also known as corturniculture,

as an alternative poultry enterprise is usually embarked upon for the excellent meat and egg characteristics of the birds and the numerous nutritive and economic benefits (Onyewuchi *et al.*, 2013). Quail farming can be an affordable way to generate some extra income as quails are characterized by fast body weight gain, short rearing period and the products are in high demand in the

market (Sokol *et al.*, 2014). Quail eggs and meat are very low in fat and high in protein. Quail products can help with the treatment of diseases like liver disease, diabetes, hypertension and tuberculosis (Umera *et al.*, 2018). Unfortunately, the quail production system is hounded by many problems including infectious diseases especially those caused by gastrointestinal parasites. Reports on these diseases have been recorded from various authors across the globe (Bashtar *et al.*, 2010; Mohammad, 2012; Shemshadi *et al.*, 2014; Monte *et al.*, 2018) and in Nigeria (Umar *et al.*, 2014; Gamra *et al.*, 2015; Adelabu *et al.*, 2018). Despite the importance of quail in meeting the demand for animal protein, there is a paucity of information on the effects of gastrointestinal parasites on domestic quails in Nigeria. Therefore, the current study was aimed to determine the prevalence of gastrointestinal tract parasites in quails reared in Umuahia area of Abia State, Nigeria.

Materials and Methods

Study area

The study was conducted in Abia state which occupies about 5824 square kilometres. It is bounded in the north and northeast by Anambra, Enugu and Ebonyi states, it is bounded in the west by Imo and in the east and south-east by Cross River, Akwa Ibom and to the south by River state. Both modern and traditional poultry production is practised in the state.

Faecal sampling

Faecal samples were collected from Michael Okpara University of Agriculture quail farm and from individual quail farms in Ehimiri, Lodu, Ndume and World Bank areas. Samples were collected for screening twice a week from May 2019 to January 2020. Quails (*Coturnix japonica*) of different ages and sexes were sampled for the presence of gastrointestinal parasites. This was achieved by screening their faeces for the presence of helminth eggs and coccidian oocysts. Adult birds were restrained in a basket for about thirty minutes to void faeces which was then collected into faecal sample tubes while for younger birds, samples that were freshly voided on the floor were collected using a spatula and avoiding as much as possible contamination from litter. Faecal samples were transported in a cooler containing ice packs to the Veterinary Parasitology Laboratory of the College of Veterinary Medicine, Michael Okpara University of Agriculture, Umudike. In the laboratory, the faecal samples were preserved at 4°C until they were examined not more than 24 hours post collection. The

sex issue was not considered strictly as most of the birds were young birds and could not be restrained due to size.

Flotation method

Measurement of three grams of faeces was added to 15mls of water. This was homogenized with a spatula and passed through a 0.5mm mesh sieve. The filtrate was poured into a test tube and centrifuged at 2000rpm for five minutes. The supernatant was discarded and the sediment was thoroughly mixed before the test tube was filled to the brim with saturated sugar solution. A clean glass coverslip was placed on the test tube for five minutes after which it was carefully removed with the drop of solution attached to it and placed on a clean glass slide. The slide was viewed at $\times 10$ magnification of the light microscope. Identification of the helminths and protozoans was through morphological characteristics of their ova and cyst using the keys provided by Thienpoint *et al.* (1979).

Results and Discussion

Quails recently became very important economically because of their eggs and meat. This survey will be the first published work on parasites of quails in Abia state.

The result from the survey showed the presence of six gastrointestinal parasitic infections in the quails sampled in Umuahia, Abia State. These included *Ascaidia* spp, *Heterakis* spp, *Cappilaria* spp, *Syngamus* spp, *Strongyloides* spp and one protozoan parasite (*Eimeria* spp.). The total number of quails sampled were 300. 167(55.6%) of the quails were infected with helminths while 89(19.6%) of the quails were infected with *Eimeria* oocysts. This agrees with the study conducted by Kumar *et al.* (2003) in India where he established the presence of six species of parasite, and Adelabu *et al.* (2018) in Nigeria where four out of the six parasites recorded in this study was seen. It, however, differs from the report of several species of parasite reported by Villarreal *et al.* (2016) and Das *et al.* (2015) who reported only one species (*Ascaridia*) in his study in India.

The most prevalent of the helminth parasite species (Table 1) identified from quails in this study (*Ascaridia*) was also reported by Das *et al.* (2015). It, however, differs from Adelabu *et al.* (2018) who reported *Cappilaria* spp. as the most prevalent. *Ascaridia galli* has been reported to inflict damage to the tissue of birds by interfering with nutrient absorption causing poor growth and production, leading to death by an intestinal blockage in severe

cases (Das *et al.*, 2015). It is also worth noting that *Ascaridia* spp. is one of the most common parasites of poultry given its pathogenicity particularly in young birds. Other nematodes, like *Capillaria* spp., *Heterakis* spp., *Syngamus* spp. and *Strongyloides* spp. were reported and their presence could have been influenced by the management system and age. Helminths were more prevalent among adults and also in the deep litter system (Table 2). This could be a result of prolonged exposure to the parasite organism.

Eimeria spp. which was reported as the only protozoan parasite in this study with a prevalence of 19.6% was also reported by Adelabu *et al.* (2018) in the southwestern part of Nigeria. Adelabu *et al.* (2018) had a prevalence rate of 68%. The prevalence from this study might be due to poor management of litter in quail farms which potentiates a good environment for *Eimeria* spp proliferation and infection by the quails. *Eimeria* spp. had more prevalence among adults than young quails as seen in Table 2 and Figure 1.

Table 1: Percentage prevalence and mean faecal egg count (FEC) of individual helminth parasites identified in this study.

Helminth genus	% Prevalence	Mean FEC
<i>Ascaridia</i>	63 (37.7%)	80
<i>Heterakis</i>	41 (24.6%)	60
<i>Capillaria</i>	33 (19.8%)	40
<i>Syngamus</i>	20 (12.0%)	35
<i>Strongyloides</i>	10 (6.0%)	20

Table 2: Population dynamics and prevalence of parasite based on age and management systems

Parameters	Parasites	
	Helminths (%)	<i>Eimeria</i> (%)
Age		
Adult (> 7 weeks)	126(75.4%)	56(62.9%)
Young (≤ 7 weeks)	41(24.6%)	33(37.1%)
Management Systems		
Deep litter	136(81.4%)	63(70.8%)
Cage	31(18.6%)	26(29.2%)

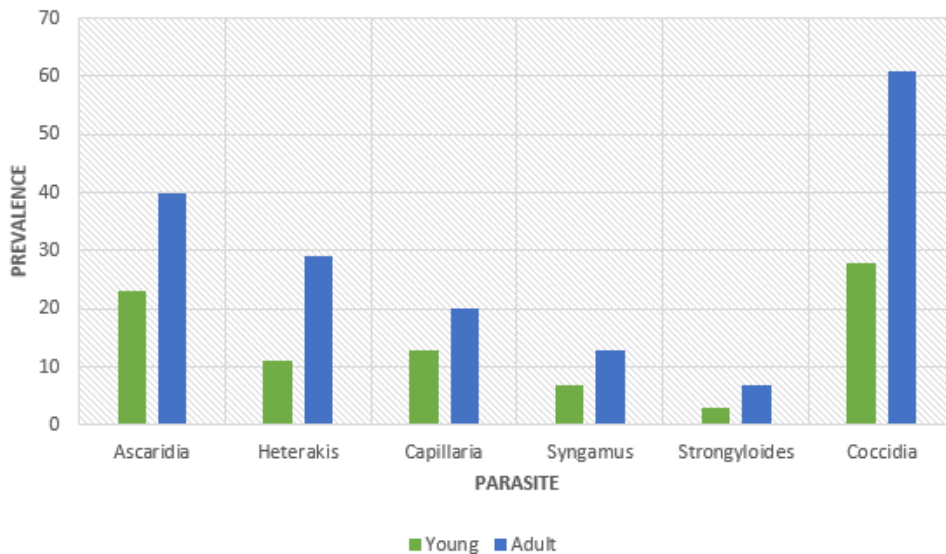


Figure 1: Prevalence of each parasite as related to their age

This report of the parasitic fauna in quails in this study area highlights the need for the development of health management practices for safer and healthier coturniculture. This study has shown evidence of parasitic infection of quails in Abia state, Southeastern Nigeria and has provided baseline data on parasitic infection in quails in southeast Nigeria. Certain epidemiological factors such as age and management systems influenced the prevalence of parasitic infection in the quails. From this study, it is of essence that quail farmers be advised to ensure they maintain proper hygiene practices on the farm. It is also good to note that though the results of this study are striking, there is a need for future study on slaughtered quails for the presence of adult parasites. Some parasites either have poor fecundity or their eggs as in the case of tapeworms which are passed out in intact proglottids narrowing the chances of their diagnosis by faecal egg counts.

Conflict of Interest

The authors declare that there is no conflict of interest.

References

- Adelabu DB, Adediran OA & Uwalaka EC (2018). Parasitic infections of commercial quails in Southwest Nigeria. *African Journal of Environmental Health Sciences*, **5**: 113-120.
- Bashtar A, Abdel-Ghaffar F, Al-Rasheid K, Mehlhorn H & Nasr I (2010). Light microscopic study on *Eimeria* species infecting Japanese quails reared in Saudi Arabian farms. *Parasitology Research*, doi.10.1590/S0100-736X2013001200008
- Das MR Laha A & Doley S (2015). Gastrointestinal Parasitism in Turkeys and Quails of Umiam, Meghalaya. *Indian Journal of Hill Farming*, **28**(1): 12-13.
- Gamra OW, Antia RE & Falohun OO (2015). Intestinal cestodes of poultry *Raillietina echinobothrida* and *Choanotaenia infundibulum* infection in a commercial Japanese quail (*Coturnix coturnix japonica*) farm in Apomu Osun state Nigeria. *Scientific Journal of Zoology*, **4**(4): 20-25.
- Kumar R, Sinha SRP & Sahey MN (2003). Seasonal and age-wise prevalence of helminth in Japanese Quail (*Coturnix coturnix japonica*) in patna, Bihar. *Indian Journal of Poultry Science*, **38**(1): 32-36.
- Mohammad NH (2012). A study on the pathological and diagnosis of *Eimeria* species infection in Japanese quail. Basrah. *Journal of Veterinary Research*, **11**(1): 1-7.
- Monte GLS, Cavalcante DG & Oliveira JBS (2018). Parasitic profiling of Japanese quails (*Coturnix japonica*) on two farms with conventional production system in the Amazon region. *Pesquisa Veterinária Brasileira*, **38**(5): 847-851.
- Onyewuchi UU, Offor IR & Okoli CF (2013). Profitability of Quail Bird and Egg Production in Imo State. *Nigerian Journal of Agriculture, Food and Environment*, **9**(1): 40 – 44.
- Shemshadi B, Ranjbar BS & Mirakhori (2014). Study on parasitic Infections of Quails in Garmsar, Iran. *International Journal of Advance in Biology and Biomedical Research*, **2**(2): 262 – 266.
- Sokol RM, Gesck MN & Michal M (2014). Toltrazuril (Baycox) treatment against coccidiosis caused by *Eimeria* spp in Japanese quails (*Coturnix coturnix japonica*). *Polish journal of veterinary sciences*, **17**(3): 465-468.
- Thienpoint D, Rochete F & Vanparijis OF (1979). Diagnosing Helminthosis through Coprophagical examination. Jansssen Research Foundation Beerse, Belgium. Pp 129-135.
- Udoh NA, Luka SA & Patrick AA (2014). Prevalence of gastrointestinal parasites of domestic turkey (*Meleagris gallopavo*) Linnaeus (1758). Slaughtered in Kaduna metropolis, Kaduna state, Nigeria. *Journal of Natural Science Research*, **4**(17): 105-109.
- Umera AE, Ejezie FE, Ibegbu MD, Ikekpeazu JE, Onyekwelu KC & Ejezie CS (2018). Effects of quail (*Coturnix Japonica*) egg diet on both the sugar and the lipid profile of alloxan induced diabetic albino rats. *Biomedical Research*, **29**(19): 18- 29
- Villarreal SM, Bruno A, Fedynich AM, Brennan LA & Rollins D (2016). Helminth infections across a Northern Bobwhite (*Colinus virginianus*) annual cycle in Fisher County, Texas. *Western North American Naturalist*, **76**(3): 2.