



Clinicopathological features and management of aspergillosis in some poultry farms in Jos metropolis, Nigeria

NO Ameji¹, OO Oladele¹, PH Bamaiyi² & LH Lombin³

1. Department of Veterinary Medicine, Surgery and Radiology, University of Jos, Nigeria
2. Department of Veterinary Microbiology and Pathology, University of Jos, Nigeria
3. Department of Veterinary Public Health and Preventive Medicine, University of Jos, Nigeria

*Correspondence: Tel.: + 234 8035907570; E-mail: amejio@unijos.edu.ng

Copyright: © 2020 Ameji *et al.* This is an open-access article published under the terms of the Creative Commons Attribution License which permits unrestricted use, distribution, and reproduction in any medium, provided the original author and source are credited.

Abstract

Aspergillosis is important in poultry production and human health but difficulty in its ante mortem diagnosis in addition to the unsuccessful outcome of most management options has made the disease a lingering nightmare to farmers. This study presents the clinicopathological features and management of aspergillosis in some poultry farms in Jos metropolis, Nigeria. Thirteen cases of aspergillosis from 12 poultry farms were confirmed and managed from April, 2019 to March, 2020 with 7.6% cases in a mixed turkey-broiler farm, 15.4% in broilers and 76.9% in layers. The ages affected ranged from 3 weeks to 21 weeks with 69.2% cases in pullet grower birds of 10 – 21 weeks compared to young chicks, 3 – 9 weeks with 30.8%. The rainy season accounted for 61.8% cases while mortality ranged from 1.0% to 17.4%. The clinical features were consistent and included dyspnoea; inappetence; retarded growth and mortality. While necropsy showed consolidated lungs with caseous nodules; liver with raised grayish or yellowish irregular nodules; peritonitis with the peritoneum and air sacs laced with caseous nodules; diphtheritic membrane and caseous nodules on intestinal mucosa; haemorrhagic bursitis with granulomata; caseous nodules on osseous tissues as well as nodules on the skin and skeletal muscles. Confirmatory diagnoses of aspergillosis were made by culturing nodules on Sabouraud's Dextrose Agar. Antifungal susceptibility testing showed CuSO₄ to be more susceptible which was used at the dosage of 3g/10L of drinking water for at least 7 days in all the cases. Concurrent bacterial infections were seen in some of the cases and were treated concurrently with antibiotics based on susceptibility testing while farmers using moldy feeds were asked to withdraw such feeds. Conclusively, aspergillosis is prevalent in Jos metropolis with severe impact on production and may be a silent killer disease in poultry due to constraints in diagnosis and its management.

Publication History:
Received: 23-06-2020
Accepted: 01-09-2020

Keywords: Aspergillosis, clinicopathological features, Jos, management, Nigeria, poultry

Introduction

Aspergillosis is an infectious and often sporadic but non contagious disease of poultry affecting the lower

respiratory tract. It is a common management problem in commercial poultry that occurs due to

immunosuppression of the host or during inhalation of an overwhelming number of fungal spores (Girma *et al.*, 2016). The disease can be acute or chronic which may manifest clinically as pulmonary, ocular, disseminated systemic and nervous forms (Dhama *et al.*, 2013). The acute form of the disease generally occurs in young birds resulting in high morbidity and mortality while the chronic form is sporadic and generally affects older birds, especially with a compromised immune system due to poor husbandry condition with lesser but lingering mortality (Girma *et al.*, 2016). In most outbreaks, mortality ranged between 5 – 90% while age of diseased birds varied from 3 days to 20 weeks (Arñe *et al.*, 2011; Girma *et al.*, 2016).

Aspergillosis is caused by *Aspergillus fumigatus* mainly but other species such as *A. flavus*, *A. niger*, *A. glaucus*, *A. nedulans* and *A. terreus* are also found associated with the disease (Arñe *et al.*, 2011). The organisms are common soil saprophytes that grow on organic matter in hot and humid environment and can penetrate egg shell to infect developing embryo with classical lesions post hatch (Girma *et al.*, 2016). Sometimes, infected eggs serve as sources of contamination of hatchery equipment with large number of resistant fungal spores. Stress, prolonged use of antibiotics or corticosteroids, concurrent infections, overcrowding, poor nutrition, poor sanitation, poor ventilation and high humidity are factors that predispose to the disease (Arñe *et al.*, 2011; Girma *et al.*, 2016).

Aspergillus organisms are important not only for the invasive infections caused in poultry and other animal species including humans but also for the contamination of food with preformed toxins (mycotoxins) which are secondary metabolites that cause mycotoxicosis when consumed (Arñe *et al.*, 2011; Girma *et al.*, 2016). Lobna *et al.* (2014) reported that water and feed contaminated by fungal spores contributed to the occurrence of Aspergillosis in birds with the isolation of *Aspergillus spp* from sputum of some poultry farm workers, indicating its public health implication.

The economic loss to farmers caused by aspergillosis is huge because treatment using conventional antifungal agents is often unsuccessful and useless. Apart from mortality as a direct effect, production is greatly affected in terms of low egg production, poor feed conversion and retarded growth rate while air sacculitis and disseminated granulomata often lead to carcass condemnation in poultry meat trade due to public health concern (Arñe *et al.*, 2011).

The organisms are ubiquitous and worldwide in distribution though more common in humid tropical environments like Nigeria where ambient temperature is between 25 – 37 °C. Most workers reported occurrence of the disease to be more during the beginning of the rain (spring) and during the fall coinciding with harvest (Dhama *et al.*, 2013; Musa *et al.*, 2014). Aspergillosis has been reported in most domesticated avian species and production types such as chicken layers, broiler breeders, turkey poults, duck breeders, goslings, great rheas, ostriches, quails as well as pigeons with devastating effects (Martin *et al.*, 2007; Arñe *et al.*, 2011).

The organism(s) after the invasion of the respiratory tract is slowly disseminated via haematogenous route to other body organs eliciting lymphocytic and phagocytic reactions to cause granulomata formation. The granulomata are white to yellow creamy or caseous nodules of varying sizes holding the organisms and are rarely penetrated by drugs (Girma *et al.*, 2016).

The refractory response to treatment of aspergillosis using most conventional antifungal drugs has made the disease a lingering nightmare to farmers once preventive measures fail and outbreak occurs (Arñe *et al.*, 2011; Dhama *et al.*, 2013; Girma *et al.*, 2016). The situation is compounded by the difficulty in early recognition of the disease ante mortem using only clinical features which no doubt might be the cause of the under reporting of the disease. This paper presents the clinicopathological features and management of aspergillosis in some poultry farms in Jos metropolis, Nigeria. The susceptibility pattern of antifungal agents *in vitro* which informed the choice of a particular antifungal agent with good response to treatment is also reported.

Case Management

The study is a prospective case series of aspergillosis in some poultry farms that were presented and managed from April, 2019 to March, 2020 at the Avian and Fish clinic of the Veterinary Teaching Hospital (VTH), University of Jos, Nigeria. Case inclusion criteria were farm owners' complaints or clinical signs of respiratory distress, retarded growth, low production and persistent mortality in the face of antibiotic treatment as well as nodular lesions within lungs and other tissues at necropsy. The clinical features, gross pathological lesions, epidemiological features especially season of occurrence and ages of affected birds, diagnostic characteristics as well as responses to treatment and control of such cases were considered. Confirmed cases of aspergillosis

were also subjected to antifungal susceptibility testing to make the best choice for therapy.

Case 1

Case history: On 08-05-2019, two dead birds from a flock of 12 weeks old 2,500 brown pullets that were sourced from Zartech hatchery in Ibadan, Oyo State were presented to the VTH, University of Jos, Nigeria with the chief complaint of persistent daily mortality for up to 2 weeks. The flock had been under treatment with Doxygen® (Gentamicin and Doxycycline) for up to a week but no improvement. The mortality pattern never exceeded two but had been consistent daily with about 25 (1.0%) birds lost from the flock. The vaccinations were up to date with the last one being an inactivated mesogenic NDV-K at 9 weeks of age. It was further revealed that the birds were fed with self-formulated feed using commercial protein concentrate mixed with maize, rice bran and palm kernel cake (PKC). The client mentioned that the PKC had been in storage for over 2 years.

Case 2

Case history: On 23-5-2019, three dead birds from a flock of six weeks old, 600 brown pullets sourced from Amo hatchery in Ibadan, Oyo State were presented to the VTH, University of Jos with the complaints of huddling together, drop in feed intake and mortality. The mortality is sporadic and staggering with a total of 11 birds (1.8%) lost before presentation. The birds were vaccinated with Livacox® (Coccidiosis vaccine) while Gumboro and ND La Sota vaccinations were also done twice. The birds were fed on commercial finished feed.

Case 3

Case history: On 23-07-2019, six dead birds from a flock of 16 weeks old 3,000 brown pullets were presented to the VTH, University of Jos with the complaints of reduced feed intake, coughing and daily mortality. The mortality has been on for a week and about 50 birds (1.6%) had died in the flock. The vaccination was up to date but due to the persistent mortality, the 3 in 1 (combined ND, EDS-70 and IB) vaccination could not be given. The farmer compounds feed with local feed ingredients for the birds.

Case 4

Case history: On 02-08-2019, two dead birds from an initial flock of 1000, four weeks old brown pullets were presented to the VTH, University of Jos with the complaints of huddling together, reduced feed intake and daily mortality. The flock had Gumboro outbreak

with current population of birds being 750. The mortality pattern in the last 3 days was 5, 4 and 2 totaling 11 birds (1.5%). The flock had been treated with amoxycol® (amoxicillin and colistin), antiviral solution, multivitamins and presently on an anticoccidial drug. The birds are fed on commercial finished feed.

Case 5

Case history: On 16-08-2019, five carcasses from a flock of 21 weeks old 1000 brown pullets were presented to the VTH, University of Jos with the complaints of coughing, reduced feed intake and daily mortality. The birds were purchased at point of lay but were stunted and had not come into lay as at the time of presentation. The mortality pattern in the last five days ranged from 3 to 7 birds per day with a total of 24 birds (2.4%) lost within a week. The entire medication and vaccination history were not certain but birds had received ciprofloxacin, anticoccidial and currently on tylosin.

Case 6

Case history: On 20-08-2019, three carcasses from a flock of 12 weeks old, 3000 brown pullets were presented to the VTH, University of Jos with the chief complaints of reduced feed intake and sudden mortality. The vaccinations are up to date and the birds' beaks were trimmed a week earlier. The birds are fed with commercial finished feed. The mortality had been increasing since first noticed almost a week before presentation with 37 birds (1.2%) lost from the flock.

Case 7

Case history: On 11-10-2019, four carcasses from a flock of 10 weeks old, 500 brown pullets were presented to the VTH, University of Jos with the complaint of persistent and rising mortality in spite of different antibiotic therapy close to two weeks. The vaccinations were done up to six weeks of age with the last vaccine being NDV – Komarov. The flock was presented about a week earlier with prescription made to treat coccidiosis and colibacillosis using amprolium and streptomycin which the farmer complied. Mortality has been staggering with about 50 birds (10%) lost within the last two weeks. The farmer compounds his chickens feed with ingredients sourced locally.

Case 8

Case history: On 18-10-2019, one live broiler of 12 weeks old and two live adult turkeys of 32 weeks old were presented to the VTH, University of Jos with the

complaints of sudden death of one broiler chicken and gasping for breath in the turkeys. The broiler chickens and adult turkeys were being reared together in a flock of eight mixed birds made up of three broiler chickens and five turkeys on a free run in the compound and fed sometimes with maize offal and whole grains.

Case 9

Case history: On 12-11-2019, two carcasses from a flock of three weeks old, 50 broiler chickens were presented to the VTH, University of Jos with the complaints of inactivity, sneezing and mortality. The birds had been vaccinated against Gumboro disease about a week ago and some antibiotic medications were given but no improvement. So far, five birds had died (10%). The birds were fed with commercial finished feed.

Case 10

Case history: On 9-12-2019, three carcasses from a flock of 16 weeks old, 1,600 brown pullets were presented to the VTH, University of Jos with the complaints of rising mortality and non-response to antibiotic treatment. There was an outbreak of suspected aspergillosis in another batch of birds in this particular farm earlier. The birds were fed with self-formulated feed using commercial protein concentrate mixed with maize, rice bran and wheat offal.

Case 11

Case history: On 23-12-2019, five carcasses from a flock of 10 weeks old, 900 brown pullets were presented to the VTH, University of Jos with the complaints of coughing and daily mortality. The mortality rate was 4.4% with the loss of 40 birds in the last 3 days before presentation. The vaccinations were up to date. The birds were fed on self-formulated feed with ingredients sourced locally.

Case 12

Case history: On 9-02-2020, two carcasses from a flock 11 weeks old, 60 broiler chickens were presented to the VTH, University of Jos with the complaints of coughing, diarrhea and mortality. About 10 birds (16.7%) had been lost before presentation. The birds were fed with commercial finished feed mixed with maize offal.

Case 13

Case history: On 15-02-2020, three carcasses from a flock of eight weeks old, 500 brown pullet chickens were presented to the VTH, University of Jos with the complaints of stunted growth and persistent

mortality. The flock was housed in an old poultry pen which was not used for quite some time though, the farmer claimed to have cleaned up before restocking. The birds were fed on commercial finished feed and mortality commenced shortly after the fowl pox vaccination at 6 weeks of age with the loss of about 15 birds (3%) from the flock.

Physical examination

Apart from the mixed broiler-turkey flock presented live to the VTH, farm visits were made to some farms with suspected cases of aspergillosis and birds were examined clinically. The clinical signs observed were dullness, gasping for breath with opened mouth; continuous hock sitting; closed eyes with a unilateral non retractive nictating membrane and white cheesy exudates underneath the eyelid was observed in one of the turkeys. Other clinical signs seen were coughing, paralysis of wings and feet, retarded growth, greenish diarrhea and loss of weight.

Post mortem findings

The post mortem lesions were consistent and included slightly emaciated carcasses; congested liver with focal nodules; whitish caseous nodules in the lungs and inner portion of the sternum; necrosis of the lungs; generalized whitish nodules of varying sizes on the peritoneum, myocardium and osseous tissues with congested and slightly swollen kidneys (Plate I). Also, in some carcasses there were mottled liver with raised granulomatous nodules; enlarged and haemorrhagic bursa of Fabricius with granulomatous nodules; thickened and cloudy airsacs laced with numerous nodules; congested kidneys with caseous nodules; suffusion of the duodenal mucosa; greenish mucoid enteritis (Plates IIa & IIb).

Other lesions were fibrinous perihepatitis and pericarditis; raised caseous nodules on the myocardium; consolidated lungs with white focal nodules; erosion of the proventriculus; severe necrosis of the caecal tonsils and haemorrhages in the caeca (Plate IIIa). In addition, there were yellowish caseous nodules on the skin and breast muscle; peritonitis; splenitis; severe air sacculitis; highly congested liver with slight bile imbibition and necrosis in one carcass; diffused petechial haemorrhages and suffusion at the upper part of the proventricular mucosa as well as yellowish caseous nodules on the intestinal mucosa with typhilitis (Plate IV).

Diagnosis

Based on the history of self-feed formulation using PKC of long storage and other locally sourced feed

ingredients, vaccination or disease induced stress, prolong use of antibiotics without response and necropsy lesions, tentative diagnoses of Aspergillosis were made in all the cases. Lungs samples and nodules from other visceral organs were sent to the microbiology laboratory of the VTH, University of Jos to be cultured on Sabouraud's Dextrose Agar (SDA) for fungal isolation and identification. Liver, spleen, heart and tracheal exudates were also sent for bacterial culture to isolate and identify any mixed bacterial infections. All cases were assessed to see the variation in case distribution based on type of poultry production, age of birds affected and season of disease occurrence among others (Table 1).

Laboratory investigations
Lungs, other affected tissues with nodular lesions from some striking cases and feed samples consumed by birds from such farms were sent to the microbiology laboratory for isolation and identification of the causative organisms. A portion of those samples were processed and cultured on Sabouraud's Dextrose Agar (SDA) at 37 °C for 4–5 days. The fungal growths on SDA was

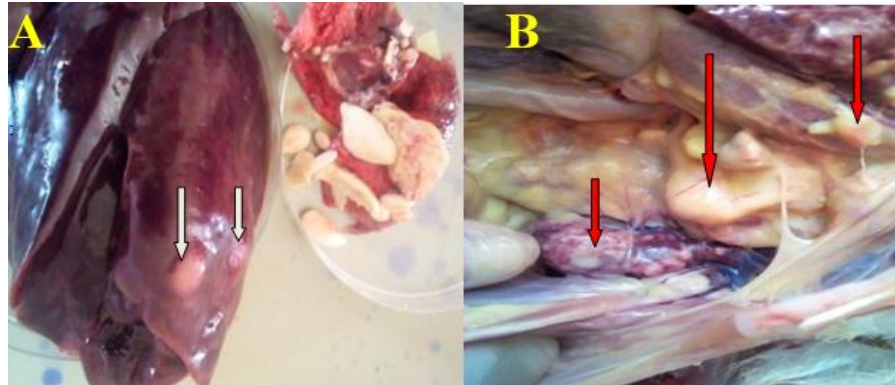


Plate I: Generalized yellowish cheesy and caseous nodules in the liver, lungs, kidneys and osseous tissue (arrows) from a flock of 12 weeks old 2,500 brown pullets (A and B)

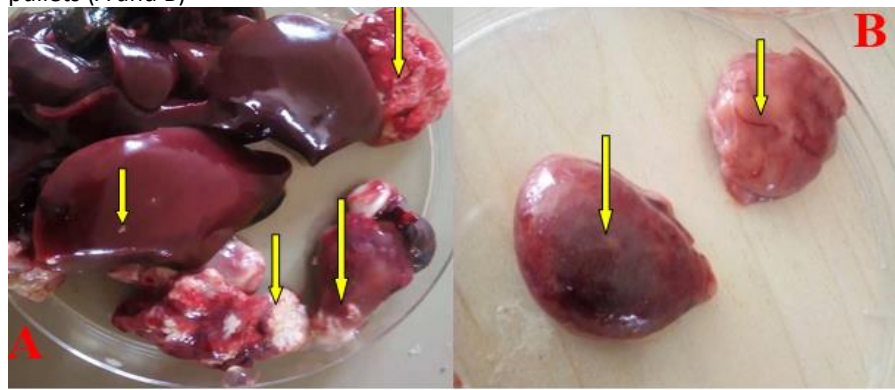


Plate II: Liver, consolidated lungs and heart with cheesy nodules (arrows) in a 6-week-old pullet with Aspergillosis (A). Nodular lesions in the spleen and bursa of Fabricius from the 11-week-old broiler with Aspergillosis (B)

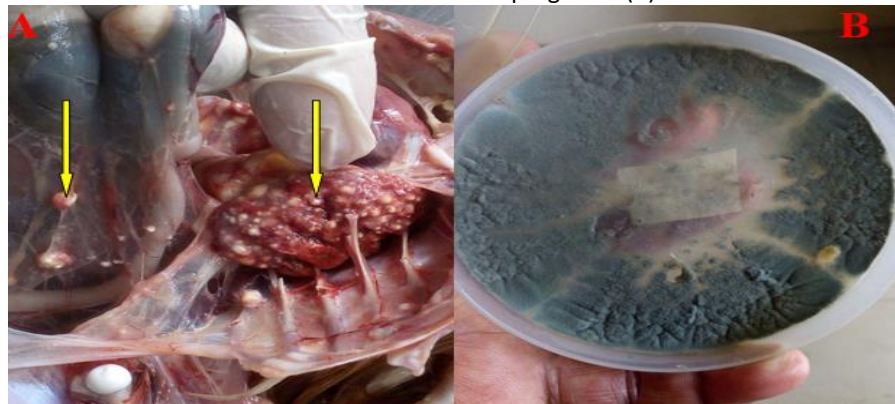

Plate III: Whitish nodules on air sac and lung in chicken (A). Lung tissue with nodules from a case of Aspergillosis in a 16-week-old brown layer yielded high growth of *Aspergillus fumigatus* on SDA (B)

Table 1: Distribution of cases of Aspergillosis based on age and season on some poultry farms in Jos metropolis, Nigeria

Type of poultry			Ages of birds affected		Season of occurrence	
Broilers	Layers	Mixed	3 – 9weeks	10 – 21weeks	April - October	Nov. – March
2 (15.4%)	10 (76.9%)	1 (7.7%)	4 (30.8%)	9 (69.2%)	8 (61.5%)	5 (38.5%)

viewed on the surface and reverse side for fungal morphology and stained with lactophenol cotton blue then, examined with the light microscope at x40 magnification (Plate VI).

The remaining portion of the tissues were processed and cultured for bacterial growth on Nutrient Agar and incubated at 37 °C for 24 – 48 hours. Bacterial isolates were examined for colonial morphology, stained with Gram's stain and subjected to other biochemical tests for identification.

Antimicrobial susceptibility testing

The fungal and bacterial isolates were subjected to antimicrobial susceptibility testing with in-house made fungal and bacterial antimicrobial discs using the principle of Kirby-Bauer disc diffusion method (CLSI, 2015). The discs were made from sterile Whatman filter paper impregnated with between 10 – 50 µg of antibiotics and between 10 – 20 µg of antifungal agents (Plate Vb). The antifungal agents used were fluconazole (20 µg); Nystatin (20 µg); Itraconazole (10 µg) and CuSO₄ (10 µg) while antibacterial agents used were gentamicin (10 µg); streptomycin (40 µg); Oxytetracycline (50 µg); Colistin (10 µg) and Enrofloxacin (20 µg).

The bacterial colonies at the growth phase to be tested were diluted in sterile normal saline to obtain 0.5 McFarland standards and compared using a Wickerham card. The inocula were streaked evenly using sterile swabs on Muller Hinton Agar. The antimicrobial discs were dispensed using sterile

forceps on the inoculated agar and incubated at 37 °C for 18 – 72 hours (CLSI, 2015).

Antimicrobial susceptibility with a diameter of zone of inhibition (DZI) of 20 – 30mm or more is taken as sensitive; DZI of 15 – 20mm is taken as intermediate while DZI of less than 14mm in diameter is taken as resistant (CLSI, 2015).

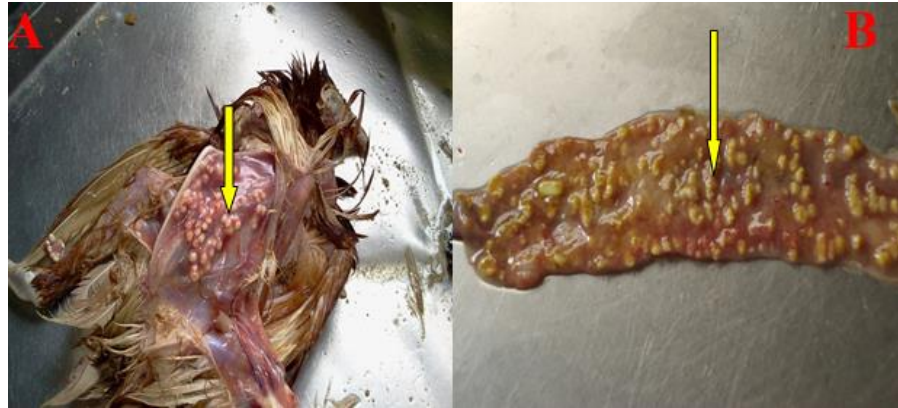

Plate IV: Skeletal muscle (A) and enteric (B) nodules (arrows) associated with Aspergillosis in a 16-week-old brown pullet

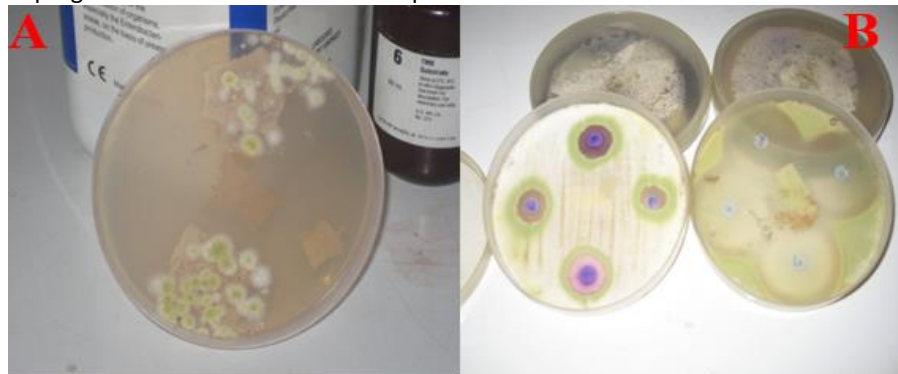

Plate V: Fluffy, whitish growth of *Aspergillus flavus* with a yellowish centre on SDA from intestinal and muscular nodules from carcass of a 21-week-old brown layer (A). Anti-fungal susceptibility testing of *Aspergillus flavus* on SDA (B)

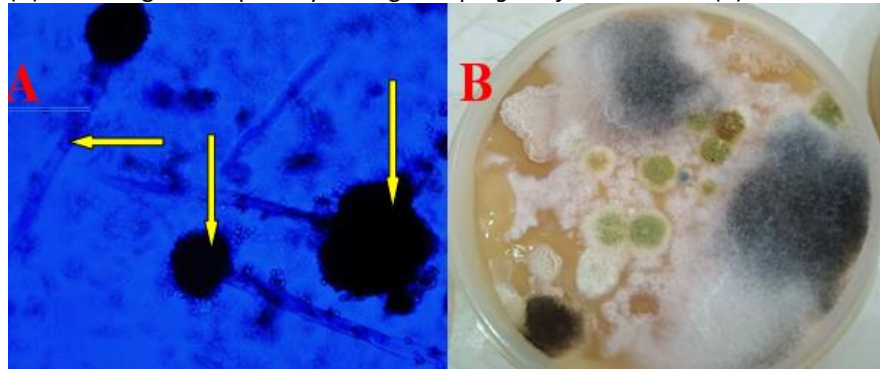


Plate VI: Stained *Aspergillus flavus* with lactophenol cotton blue showing conidiophores with flask shaped vesicle bearing conidia on phialides (A). Feed sample from a poultry farm with persistent mortality and drop in egg production yielded growth of several colonies of *Aspergillus flavus*; *A. niger* and white cottony mold on SDA (B)

Table 2: Fungal and bacterial isolates from each case and the therapeutic agent effectively used for management via drinking water

Case	Fungal organism isolated	Mixed bacterial organism	Treatment
1	<i>Aspergillus fumigatus</i>	<i>Proteus spp</i>	CuSO ₄ at 3g/10litre for 7 days Doxygen® at 1g/2L for 5 days
2	<i>Aspergillus fumigatus</i>	No growth	CuSO ₄ at 3g/10litre for 10 days
3	<i>Aspergillus fumigatus</i>	<i>E. coli</i> and <i>Proteus spp</i>	CuSO ₄ at 3g/10litre for 14 days Penprovit® at 1g/2L for 5 days
4	<i>Aspergillus flavus</i>	No growth	CuSO ₄ at 3g/10litre for 7 days
5	<i>Aspergillus fumigatus</i>	<i>Salmonella spp</i>	CuSO ₄ at 3g/10litre for 7 days Enrocare® at 2ml/4L for 7 days
6	<i>Aspergillus fumigatus</i>	<i>Klebsiella spp</i>	CuSO ₄ at 3g/10litre for 7 days Enrocare® at 2ml/4L for 5 days
7	<i>Aspergillus fumigatus</i>	<i>Klebsiella spp</i> and <i>E. coli</i>	CuSO ₄ at 3g/10litre for 7 days Colistin 4800® at 1g/3L for 5 days
8	<i>Aspergillus fumigatus</i>	No growth	CuSO ₄ at 3g/10litre for 7 days
9	<i>Aspergillus fumigatus</i>	<i>E. coli</i>	CuSO ₄ at 3g/10litre for 7 days Doxygen® at 1g/2L for 5 days
10	<i>Aspergillus fumigatus</i>	<i>Staphylococcus spp</i>	CuSO ₄ at 3g/10litre for 7 days Penprovit® at 1g/1.5L for 5 days
11	<i>Aspergillus flavus</i>	No growth	CuSO ₄ at 3g/10litre for 7 days
12	<i>Aspergillus niger</i>	<i>E. coli</i>	CuSO ₄ at 3g/10litre for 10 days Enrocare® at 2ml/4L for 5 days
13	<i>Aspergillus flavus</i>	<i>Proteus spp</i>	CuSO ₄ at 3g/10litre for 10 days Enrocare® at 2ml/4L for 5 days

Keys: Doxygen® (Doxycycline & Gentamicin). Enrocare® (Enrofloxacin 20%). Penprovit® (Penicillin, streptomycin, erythromycin, vitamins). Colistin 4800® (Colistin 4800 iu)

Laboratory results and management

The culture of nodular tissues from the cases on SDA showed the isolation and identification of *Aspergillus fumigatus* in nine (69.2%) of the cases, *A. flavus* in three (23.1%) of the cases and *A. niger* in one (7.7%) of the cases (Plates IIIb, Va and VI; Table 2). Also, bacterial isolates were obtained in nine of the cases indicating mixed infection while four of the cases yielded no bacterial growth (Table 2).

The cases were managed based on antimicrobial susceptibility testing using CuSO₄ at 3g/10 litters of drinking water for at least 7 days and appropriate antibiotic in mixed infection for at least 5 days (Plate Vb; Table 2).

Discussion

The high incidence of the cases of aspergillosis as seen from this study underscored the impact of the disease on poultry production in Jos metropolis. Some farms where these cases were reported had history of self-milling of feed while the remainder cases could be attributed to flaws in management practices such as poor litter, stress and immunosuppression from the effect of other diseases as well as prolonged use of

antibiotics which were consistent with other reports elsewhere (Arne *et al.*, 2011; Girma *et al.*, 2016). Farmers go into self-feed formulation and milling as a means of cutting down the cost of their production for maximum profit. Hence, such farmers may buy feed ingredients with high moisture content during harvest season at low cost for storage with concomitant buildup of fungal organisms on the ingredients before their eventual use in feed making (Aliyu *et al.*, 2016).

The occurrence of aspergillosis as seen in this report showed seasonal variation as reported by other workers (Arne *et al.*, 2011; Musa *et al.*, 2014; Girma *et al.*, 2016). The fungal organisms that cause the disease are ubiquitous and can cause disease any time that any of the predisposing factors are available in the environment. However, they multiply more rapidly in a hot humid environment especially during the rainy season when moisture and substrates to support their growth is high (Dhama *et al.*, 2013). Other workers strongly argue against the seasonal occurrence on the ground that the low number sometimes may be due to the difficulty in recognizing and diagnosing the disease ante mortem. This is in

addition to the disease being non-contagious and affects a few flock members at a time which may contribute to its negligence and under reporting (Girma *et al.*, 2016).

The type of poultry and age of birds affected as seen in this study underscored the economic impact of aspergillosis on poultry production. Egg laying birds were affected more by the disease with severe losses at the growing stage and just before onset of production. It is generally believed that the disease affecting birds of this age cluster is the chronic form with low morbidity but more devastating with lingering mortality due to immunosuppression (Arñe *et al.*, 2011; Dhama *et al.*, 2013).

The prevalence of aspergillosis among young birds in this study is low probably due to difficulty in diagnosis and under reporting. The form of the disease in young birds is acute with high mortality but the absence of specific signs and lesions may cause it to go unnoticed or taken as another disease (Arñe *et al.*, 2011).

Aspergillosis primarily affects the lower respiratory tract but can become disseminated via the blood stream to other organs of the body including the brain with neurologic signs (Dhama *et al.*, 2013). This study reports localized respiratory, disseminated intestinal and cutaneous aspergillosis which were earlier thought to be rare (Musa *et al.*, 2014).

Most of the cases yielded bacterial growth indicating a mixed infection but it was difficult to tell which was secondary to the other. However, the fact that most farmers use cocktail of antibiotics without appropriate prescription or antibiotic susceptibility testing could make a primary infection intractable and lead to persistence with resultant alteration of host's microflora. The study also indicated the benefits of the concurrent use of antifungal agents with susceptible antibiotics against mixed or secondary bacterial infection compared to the benefits with any of the antimicrobial agents used alone. The use of antibiotic to treat concomitant bacterial infection in the case of aspergillosis has been advocated and practiced over sometimes (Dhama *et al.*, 2013).

In this study, *Aspergillus fumigatus* species was isolated in most of the cases reported (69.2%) over others, a finding which was consistent with the reports of other workers (Arñe *et al.*, 2011; Dhama *et al.*, 2013; Musa *et al.*, 2014). It has been shown that *Aspergillus fumigatus* has smaller microconidia of about 2 – 3 µm that are able to bypass the mucociliary activity of the upper respiratory tract to initiate infection over other species with macroconidia that are easily trapped in the ciliary mucus (Arñe *et al.*,

2011). In immunocompromised birds, the clearance activity of the broncho-alveolar lymphoid tissue (BALT) in response to fungal pathogenesis is not efficient once the primary mucosal defense fails. In addition, it has been proven that *Aspergillus fumigatus* and *A. flavus* can resist cellular apoptosis and phagocytosis once infection is initiated to undergo haematogenous spread to other organs (Arñe *et al.*, 2011; Dhama *et al.*, 2013).

All the cases except one that was represented 4 weeks later were successfully treated once with copper sulphate (CuSO₄). The benefits of CuSO₄ in treating fungal and some bacterial infections have been known for quite some time (Dhama *et al.*, 2013; Musa *et al.*, 2014). This is encouraging as there are few veterinary antifungal agents that are effective and the human antifungal agents often used off label, are costly and sometimes, give variable results with relapses (Arñe *et al.*, 2011). Copper sulphate is a biocide with virucidal, fungicidal and bactericidal activities (Angel *et al.*, 2018; Lamia *et al.*, 2019). It is believed to be effective against the flu virus, methicillin resistant staphylococcus (MRSA), *Clostridium difficile* infection as well as its use in food processing and water purification have been established (Marisol *et al.*, 2013).

The mixed bacterial infections were treated concurrently with antibiotics to which the isolates were susceptible, while farmers using moldy feed ingredients were asked to withdraw such feeds. It is important to note that where the bacterial isolate from tissues of birds was susceptible to enrofloxacin, it was not administered at the same time with CuSO₄ which has divalent cations that could chelate the drug to reduce its bioavailability.

It is concluded that aspergillosis is prevalent in Jos metropolis and may be a silent killer disease in poultry due to untimely recognition and use of inappropriate antifungal agents. In addition, the study highlighted the success rate of therapy with CuSO₄, a cheaper and neglected antimicrobial agent of antiquity that was used based on in vitro susceptibility testing. It is recommended that fungal agents should be considered as frequent causes of disease in poultry due to the indiscriminate use of antibiotics and management errors which may compromise host immunity against fungal infections. Also, the use of CuSO₄ should be a treatment option in confirmed cases of aspergillosis in poultry.

Conflicts of interest

The authors declare that there is no conflict of interest.

References

- Aliyu RM, Abubakar MB, Yakubu Y, Kasarawa AB, Lawal N, Bello MB & Fardami AY (2016). Prevalence of potential toxigenic *Aspergillus* species isolated from poultry feeds in Sokoto metropolis. *Sokoto Journal of Veterinary Sciences*, **14**(1): 39-44.
- Angel P, Magaly T, Ricardo J, Paola N, Miriam T, Guillermo F & Angelica R (2018). Antimicrobial effect of copper surfaces on bacteria isolated from poultry meat. *Brazilian Journal of Microbiology*, **49**(1):113-118.
- Arn'e P, Thierry S, Wang D, Deville M, Le Loc'h G, Desoutter A, Femenia F, Nieguitsila A, Huang W, Chermette R & Guillot J (2011). *Aspergillus fumigatus* in Poultry. *International Journal of Microbiology*, Pp.14. Article ID 746356, doi:10.1155/2011/746356.
- CLSI (2015). Performance standards for antimicrobial susceptibility testing. In: Information Supplement M100-S17. Clinical Laboratory and Standards Institute, Wayne, PA, USA, 76–79.
- Dhama K, Chakraborty R, Verma AK, Tiwari R, Barathidasan R, Kumar A & Singh DS (2013). Fungal/Mycotic diseases of poultry – Diagnosis, treatment and control: A review. *Pakistan Journal of Biological Sciences*, **16**(23):1626-1640.
- Girma G, Abebaw M, Zemene M, Mamuye Y & Getaneh G (2016). A Review on Aspergillosis in Poultry. *Journal of Veterinary Science Technology*, **7**(6):382.
- Lamia B, Sandra A, Mourad B & Rachid O (2019). Antibacterial effect of copper sulphate against multi-drug resistant nosocomial pathogens isolated from clinical samples. *Pakistan Journal of Medical Science*, **35**(5): 1322-1328.
- Lobna MA, Abdel S & Ali F (2014). Epidemiological study of Aspergillosis in chickens and human contacts in chicken farms at Kalyoubia Governorate. *Journal of Agriculture and Veterinary science*, **7**(7):20-24.
- Marisol S, Aldo S, Raul A & Gabriela S (2013). Antimicrobial evaluation of copper sulphate (II) on strains of *Enterococcus faecalis*: In vitro study. *Journal of Oral Research*, **2**(3):114-118.
- Martin MP, Bouck KP, Helm J, Dykstra MJ, Wages DP & Barnes HJ (2007). Disseminated *Aspergillus flavus* infection in broiler breeder pullets. *Avian Diseases*, **51**(2):626–631.
- Musa IW, Aliyu G & Ismail A (2014). Aspergillosis in broilers: Reports of three cases from a commercial and two broiler breeder farms in Zaria, Nigeria. *International Journal of Current Microbiological and Applied Sciences*, **3**(6): 932-938.