



## Unilateral uterine torsion with a near-complete rip of the affected right horn in a parturient German shepherd bitch

DO Kodie, CO Oguntoye, NS Oyetayo & OD Eyarefe\*

Department of Veterinary Surgery and Radiology, Faculty of Veterinary Medicine, University of Ibadan, Nigeria

\*Correspondence: Tel.: +2347064468932; E-mail: odayarefe@gmail.com

**Copyright:** © 2020 Kodie *et al.* This is an open-access article published under the terms of the Creative Commons Attribution License which permits unrestricted use, distribution, and reproduction in any medium, provided the original author and source are credited.

### Abstract

Intra-parturient uterine torsion is a rare condition in bitches with multifactorial aetiologies. It is a cause of obstructive dystocia and is difficult to diagnose with most imaging techniques. Medical management of dystocia in parturient bitches with oxytocin often result in uterine rupture with severe consequences on maternal and foetal health. A three-year-old German shepherd (31kg) bitch presented to the Veterinary Teaching Hospital (VTH), University of Ibadan, Oyo State, Nigeria was diagnosed, after a caesarean section, with intra-parturient right horn torsion (180-degrees intracornual and 360-degrees at the ovarian end) and a near-complete rip of the affected horn from the uterine body. Before presentation, the bitch was said to have whelped three puppies but discontinued apparently due to perceived uterine inertia even when injected with three doses of oxytocin by a caregiver. The bitch's vital signs were abnormal and reflected signs of progressive shock. Haemogram showed severe anaemia, moderate neutrophilia with left shift, normal plasma protein level and platelet counts. An ultrasound examination revealed the presence of two foetuses in-utero but un-engaged at the bitch's birth canal. Following patient's stabilisation, a caesarean section unveiled an empty, involuting, left uterine horn, a 180 degrees intracornual twist of the right horn (separating the foetuses into two closed compartments) and a 360 degrees torsion at the ovarian end, which severely strangulated the vessels and ligament. The affected horn, vessels, and ligament were congested. The gravid horn was nearly ripped from the uterine body at the bifurcation. The torsion was corrected, foetuses evacuated and a hemicornuectomy performed. The bitch's recovery was uneventful. The diagnosis and management of obstructive dystocia is a challenge, especially in poor resource settings. The option of surgical intervention should be considered as an emergency by both pet owners and clinicians to preclude further complications, including those caused by oxytocin.

**Publication History:**  
Received: 28-05-2020  
Accepted: 23-06-2020

**Keywords:** Hemi-cornuectomy, Intra-parturient, Oxytocin, Torsion, Uterine

### Introduction

Torsion of the uterus is the twisting of the uterus or uterine horn about its long axis or around the contralateral horn (Parkinson *et al.*, 2019). The degree of torsion has been reported to vary from 180

degrees to 270 degrees (Kumru *et al.*, 2011; Eyarefe *et al.*, 2012). The condition is common in ruminants, especially cows, but relatively uncommon in bitches. Occurrence is reportedly more unilateral than

bilateral and higher in the gravid than non-gravid uterus (Biddle & Macintire, 2000). The aetiology of uterine torsion in bitches is not well understood, but several factors such as jumping, running or rolling during pregnancy, and premature uterine contraction in late pregnancy have been suggested (Parkinson *et al.*, 2019). Other factors such as foetal physical activities, partial abortion, hereditary weakness, variations in length and mobility of the proper ovarian and uterine ligaments, as well as lack of foetal fluids with violent uterine contractions in late pregnancy have also been implicated (Mohammed *et al.*, 2019). Most cases of uterine torsion have had concomitant obstruction of blood supply, congestion and/or rupture of uterine vessels, shock and foetal and/or maternal death. The condition is therefore considered a surgical emergency (Biddle & Macintire, 2000). Intra-parturient uterine torsion occurs during whelping (Eyarefe *et al.*, 2012). The incidence is rare, and the predisposing factors are still idiopathic. Eyarefe *et al.* (2012) reported a case of 270-degree intra-parturient uterine torsion without rupture in a Boerboel bitch following whelping of two puppies and hypothesised that the condition might be due to contraction and gravitational derangement in restless parturient bitches.

In this report, a case of right horn torsion (180-degrees intracornual and 360-degrees torsion at the ovarian end), complicated by a near-complete rip of the affected horn from the uterine body in a three-year-old, parturient German shepherd bitch is presented. The paucity of literature of such magnitude of uterine torsion and rupture, coupled with the need to exercise caution in oxytocin administration in parturient bitches form the objectives of the report.

## Case Report

### Case management

A three-year-old, German Shepherd bitch (31 kg) was presented to the Veterinary Teaching Hospital (VTH), University of Ibadan, Oyo State, Nigeria with a complaint that the bitch was unable to whelp more puppies despite an effort to induce whelping with intramuscular injection of three doses of oxytocin administered at 30-minute intervals. The bitch had whelped three puppies (the first at dawn, the second eleven hours later and the third after five minutes). The oxytocin was administered when no evidence of contraction was observed 24 hours after whelping of the third puppy, and she was presented to the VTH 24 hours after the oxytocin administration. The bitch has had two pregnancies previously, but only one was carried to term with whelping of 12 puppies.

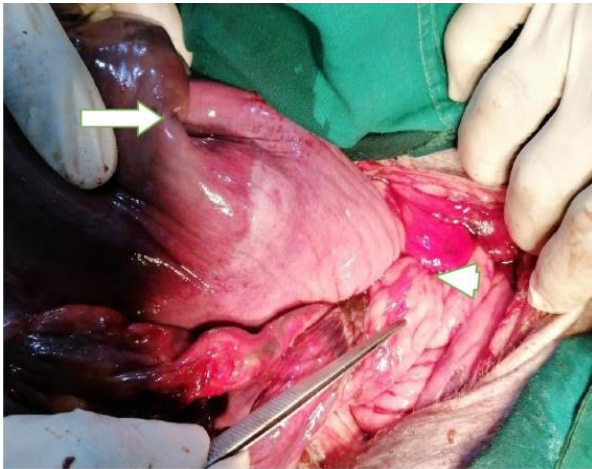
Physical examination: The bitch was lethargic, weak, and had an enlarged abdomen. There were slight serosanguinous discharges from the vulva and no evidence of abdominal contraction. The body temperature was 40.5°C, respiratory rate was 140 breaths/minute, heart rate was 165 beats/minute, ocular and oral mucous membranes were slightly pale, and capillary refill time was delayed (CRT >2 seconds).

Haematological report: The bitch was severely anaemic. Leukogram showed moderate leucocytosis characterised by moderate neutrophilia with left shift. Plasma protein and platelet counts were normal (Table 1).

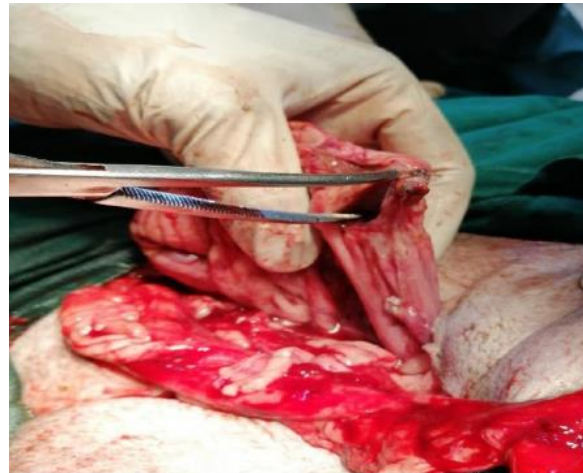Ultrasound evaluation: Ultrasound image revealed two hypoechoic structures bathed in anechoic fluid indicative of two fetuses in-utero. They were however not engaged at the birth canal.

**Table 1:** Haematology report of German shepherd with unilateral uterine torsion

Parameter	Value	Normal Range
Packed Cell Volume (PCV)	18 %	37-55 %
Haemoglobin (Hb)	5.6 g/dl	12-18 g/dl
Red Blood Cells (RBC)	$2.87 \times 10^6 \mu\text{l}$	$5.5-8.5 \times 10^6 \mu\text{l}$
Mean Corpuscular Volume (MCV)	62 fl	60-77 fl
Mean Corpuscular Haemoglobin Concentration (MCHC)	31 g/dl	32-36 g.dl/l
Platelets	$2.19 \times 10^5 \mu\text{l}$	$2-9 \times 10^5 \mu\text{l}$
Total White Blood Cells (WBC)	$22.15 \times 10^3 \mu\text{l}$	$6-7 \times 10^3 \mu\text{l}$
Segmental Neutrophils	82 %	60-70 %
Band Neutrophils	6 %	0-3 %
Lymphocytes	5 %	12-30 %
Monocytes	7 %	3-10 %
Eosinophils	0 %	2-20 %
Basophils	0 %	Rare



**Plate I:** Picture showing point of intracornual torsion (arrow) and torsion at the ovarian end (arrow head) of the right uterine horn



**Plate II:** Picture showing rip of the torsioned horn from the uterine body at the bifurcation

#### *Pre-operative protocol*

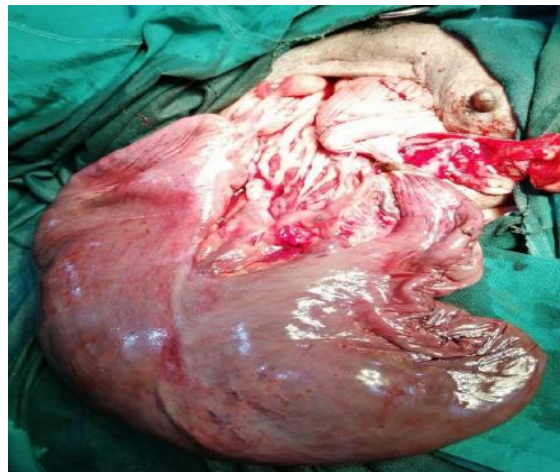**Patient stabilisation:** Intravenous infusion (Hartmann's Solution, Ashmina Ltd, Nigeria) was administered via the cephalic vein through a pre-placed gauge 21 scalp vein set. Amoxicillin (Pamoxil, Yanzhou Xier Kangtai Pharmaceutical Co. Ltd., China) (15mg/kg) was also administered intravenously. Following stabilisation for 12 hours and with improved vital signs, the patient was prepared for surgery.

**Aseptic protocol:** The ventral abdomen was prepared for aseptic surgery by clipping, scrubbing and sterilisation with povidone iodine, and the patient was draped for the procedure.

**Anaesthesia:** Butorphanol (Dolorex®, Intervet/MSD Health, UK, 10mg/ml) was administered at a dosage of 0.1 mg/kg at the onset of the procedure and two more doses as required intraoperatively. A 2% lidocaine with adrenaline (Andralocain + AD, Amakin Pharmaceutical Limited, India) was infiltrated along the incision site (skin, rectus abdominis muscle and myometrium) to access the peritoneal cavity and endometrium for foetal evacuation. Visceral splash of lidocaine was done to further enhance pain relief.

#### *Surgery*

**Surgical technique:** The abdomen was accessed via a ventral midline abdominal incision from the umbilicus to the pelvic brim as previously described (Fossum, 2018). A volume of 2.1 litres of reddish-brown, foul-smelling, abdominal fluid was suctioned from the peritoneal cavity before the uterus could be adequately manipulated and exteriorized. A 2 cm point of rupture on the left non-gravid uterine horn



**Plate III:** Picture of the right affected horn after complete untwisting of the torsion

was identified, surgically debrided and closed with 2-0 chromic gut (Chromic gut, Anhui Kangning Industrial Ltd, China) in inverting pattern. A 180-degree clockwise intracornual torsion divided the right horn into two pouches, while a 360-degree torsion strangulated the ovarian end of the right horn with the vessels (Plate 1). A near-complete rip of the right horn from the uterine body at the junction between the horn and the uterine body was observed (Plate 2). The torsion was reduced (Plate 3), and two dead non-mummified, non-putrefied foetuses were evacuated (Plate 4). A unilateral cornuectomy was performed as previously described (Kumru *et al.*, 2011). The abdominal cavity was copiously lavaged with warm saline and the laparotomy incision closed routinely in four layers with 2-0 polyglycolic acid (Covidien Ireland Limited, USA) for the peritoneum, muscles and subcutis, and size 1 Nylon sutures (Huaiyin Medical

Instruments Co. Ltd, China) for the skin, as earlier described (Fossum, 2018).

*Post-operative protocol*

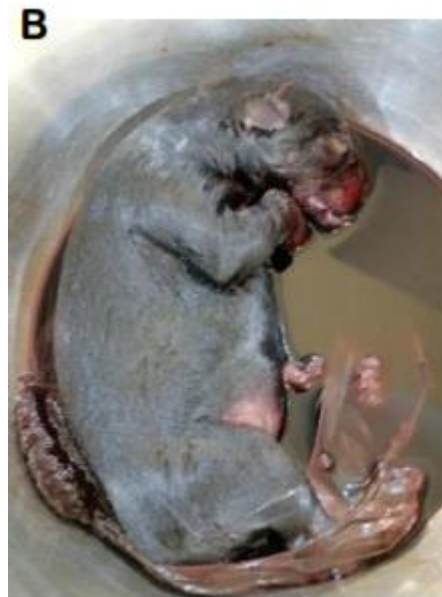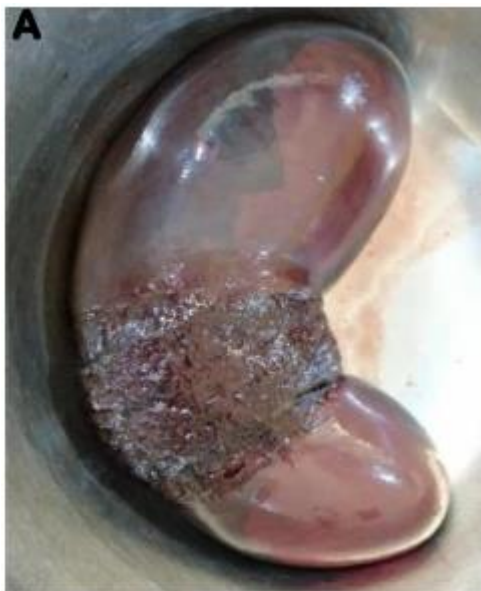Oral Amoxicillin (Amoxil, Medreich Ltd, India) (15mg/kg) was prescribed post-surgery and administered for 5 days. Healing was uneventful, and sutures were removed after eight days.

**Discussion**

The degree of uterine torsion and magnitude of rupture observed in this case is uncommon. The approach to management is also noteworthy, especially, in a poor resource setting. The bitch's poor physical status (physical status rating IV), corroborated by her laboratory data presented her as a serious anaesthetic risk, that required a well-thought-out anaesthetic protocol that could guarantee at least maternal safety. Local anaesthetic techniques are generally considered the "gold standard" for optimal maternal and foetal survival (Claude & Meyer, 2016). However, some researchers have found no difference in neonatal survival rates following either epidural lidocaine or propofol - isoflurane anaesthesia (Moon *et al.*, 2000). The poor clinical state of the bitch precluded the use of either epidural or general anaesthesia. A choice of mild sedation and some analgesia with low dose butorphanol and local infiltration of abdominal muscles with lidocaine has been recommended for a patient in poor health (Claude & Meyer, 2016), and

was employed in this case with an impressive outcome.

Uterine torsion in a pregnant bitch is relatively difficult to diagnose with most imaging techniques. Colour doppler ultrasound has however been suggested as the best diagnostic tool (Biddle & Macintire, 2000). This was not available at this hospital, which may suggest why the condition was diagnosed at surgery. The exact aetiology of uterine torsion in this case, could not be ascertained. Some authors have hypothesised that a pre-parturient torsion could occur on a uterine horn, and there is a possibility of expulsion of puppies from the untwisted or a caudal portion of the twisted horn (Mohammed *et al.*, 2019). In contrast, others have suggested a possibility of an intra-parturient torsion in the more gravid horn, caused by contractive and gravitational derangement following the complete expulsion of foetuses from the less gravid horn (Eyarefe *et al.*, 2012). In a research that established the sequence of foetal expulsion in whelping bitches, it was observed that foetal expulsion could start from any horn and involved expulsion of foetuses from alternate horns until all foetuses have been expelled ( Van Der Weyden *et al.*, 1981). In this case, the left horn was empty while the twisted right horn contained two foetuses making the later postulation on aetiology of this torsion more probable. This was further corroborated by the non-mummified and non-putrefied state of the evacuated dead foetuses.



**Plate IV:** Picture showing evacuated foetal bag with detached placenta (A) and one of the evacuated foetuses (B)

Uterine torsions result in a quickly deteriorating shock-like state associated with severe abdominal pain (Biddle & Macintire, 2000). Bitches with uterine torsion may therefore present with life threatening systemic derangements requiring prompt medical and surgical intervention. This was evident in this case as the bitch presented with signs of shock caused by strangulated vessels. The presence of neutrophilia with a left shift might be indicative of septicaemia induced by emptying of uterine fluid into the peritoneal cavity from the ruptured horns.

The action of oxytocin during parturition is to increase sodium permeability in the uterine myofibrils, stimulating uterine contraction in the presence of calcium. Oxytocin is therefore used for the medical management of primary uterine inertia (Pretzer, 2008). Oxytocin at 0.5 – 3 International Units could be administered in such cases and for uterine involution, retained placental expulsion and milk let-down in agalactic bitches (Pretzer, 2008). In this case, three shots of oxytocin instead of two (dose unknown) were administered at 30-minute intervals. The excessive use of oxytocin which is apparent in this case (administered by a non-professional) has been associated with uterine tetany, transient hypotension, foetal hypoxia and death, as well as uterine rupture (Parkinson *et al.*, 2019; Pretzer, 2008). Uterine torsion in pregnant bitches results in obstructive dystocia (secondary uterine inertia), which precludes the use of the oxytocin (Parkinson *et al.*, 2019; Pretzer, 2008). Oxytocin predisposes the uterus to rupture in secondary uterine inertia since its contractive effect pushes against the obstruction. The near-complete rip of the right uterine horn from the uterine body at the bifurcation seen in this case is suspected to be as a result of the oxytocin that was administered by the caregiver after the torsion had occurred and the bitch could not whelp any more puppies.

Uterine torsion is a surgical emergency since the condition is fatal for the dam and foetuses (Biddle & Macintire, 2000; Parkinson *et al.*, 2019). Caesarean section with partial or total ovariohysterectomy has been recommended for management depending on the severity of damage to the uterus and vessels. Unilateral cornuectomy was performed in this case to preserve the viable contralateral horn and to satisfy the owner. Subsequent pregnancies after treatment of unilateral uterine torsion by partial hysterectomy have also been reported (Kumru *et al.*, 2011), although there was a reduction in litter size.

In conclusion, since the diagnosis of primary and secondary uterine inertia is a challenge, especially in

poor resource settings, the option of surgical intervention should be considered as an emergency by both pet owners and clinicians. This will preclude complications that could arise from the use of oxytocin which is so common in this environment. Clinicians should also endeavour to educate pet owners and breeders on whelping signs and processes, and the need to call the veterinarian to forestall mal administration of ecbolic agents during whelping.

#### Acknowledgements

The authors acknowledge Mrs O. Adekunle, Mr O. O. Lasisi and Mrs Ogundiran for their immense contribution towards the postoperative care of the patient.

#### Conflicts of Interest

The authors declare no conflict of interest.

#### References

- Biddle D & Macintire D (2000). Obstetrical emergencies. *Clinical Techniques in Small Animal Practice*, **15**(2): 88-93.
- Claude A & Meyer RE (2016). Anaesthesia for Caesarean section and for the pregnant patient. In: *BSAVA Manual of Canine and Feline Anaesthesia and Analgesia*. (T Duke-Novakovski, M de Vries, C Seymour, editors) British Small Animal Veterinary Association Gloucester. Pp 366-375.
- Eyarefe OD, Oguntoye CO & Ajala OO (2012). Intraparturient uterine torsion in a boerboel bitch. (A case report). *Folia Veterinaria*, **56**(4): 31-35.
- Fossum TW (2018). *Small Animal Surgery*, fifth edition. Elsevier, Philadelphia. Pp 735-738
- Kumru IH, Seyrek-Intas K, Seyrek-Intas D, Tek HB & Wehrend A (2011). Clinical case: Unilateral en bloc ovariocornuectomy as a treatment for uterine torsion in a bitch. *Revue de Medecine Veterinaire*, **162**(2): 76-78.
- Mohammed SA, Kannan K, Narayanasamy A, Palanisamy S & Purushothaman S (2019). Management of dystocia due to unilateral uterine torsion in a Labrador bitch: A surgical approach. *Turkish Journal of Veterinary and Animal Sciences*, **43**(2): 296-298.
- Moon PF, Erb HN, Ludders JW, Gleed RD & Pascoe PJ (2000). Perioperative risk factors for puppies delivered by cesarean section in the United States and Canada. *Journal of the American Animal Hospital Association*, **36**(4): 359-368.

Parkinson T, Vermunt J & Noakes D (2019). Maternal Dystocia: Causes and Treatment. In: *Veterinary Reproduction and Obstetrics* (DE Noakes, TJ Parkinson & GCW England editors) WB Saunders Co., Philadelphia. Pp 236-249.

Pretzer SD (2008). Medical management of canine and feline dystocia. *Theriogenology*, **70**(3): 332-336.

Van Der Weyden GC, Taverne MAM, Okkens AC & Fontijne P (1981). The intra-uterine position of canine foetuses and their sequence of expulsion at birth. *Journal of Small Animal Practice*, **22**(8): 503-510.