



Necrotic enteritis and its management in 13-week old commercial pullets in Katsina, Nigeria

A Abubakar^{1*}, HB Aliyu¹, L Sa idu¹ & SG Usman²

- ¹ *Veterinary Teaching Hospital, Ahmadu Bello University Zaria, Nigeria*
- ² *Department of Veterinary Pathology, Ahmadu Bello University Zaria, Nigeria*

*Correspondence: Tel.: +2347036414691; E-mail: abdulvet.vet171@gmail.com

Copyright: © 2020 Abubakar *et al.* This is an open-access article published under the terms of the Creative Commons Attribution License which permits unrestricted use, distribution, and reproduction in any medium, provided the original author and source are credited.

Publication History:
Received: 05-11-2019
Accepted: 17-04-2020

Abstract

Necrotic enteritis is rarely reported because it is often misdiagnosed as coccidiosis due to similarity in clinical and pathological features. A field outbreak of necrotic enteritis in a flock of 13 weeks old 4,500 commercial pullets was investigated, the onset of the disease, morbidity and mortality rates were recorded. Post mortem examinations were conducted and gross lesions were documented. Tissues were collected and fixed in 10 % neutral buffered formalin and processed for histopathological examinations. Clinical signs observed were ruffled feathers, weakness, somnolence, loss of weight and diarrhoea; while the gross lesions observed were emaciated carcasses, lean abdominal fat, enlarged, pale and haemorrhagic liver; enlarged, mottled and congested spleen; mucus and diphtheritic membrane on the jejunal mucosa and enlarged kidneys. The histopathological findings of the intestine were diffused necrotic epithelial cells with marked mononuclear cells infiltration in the mucosa with severe oedema fluid. The necrotic enteritis was diagnosed based on clinical signs, pathology as well as isolation and identification of *Clostridium perfringens*. Triplesulfa[®] (sulfadimidine sodium, sulfadiazine sodium and sulfamerazine sodium); Tridox[®] L.A (20% Oxytetracycline long acting) and Enterocillin[®] (Amoxicillin trihydrate and Colistin sulphate) were ineffective, while copper sulphate at 1g/5L of drinking water was found to be effective for the treatment of the disease. The haematological values indicated lymphocytosis due to damage of the tissue caused by *C. perfringens* and the toxins produced.

Keywords: Necrotic enteritis, Commercial pullets, Copper sulphate, *Clostridium perfringens*

Introduction

Necrotic enteritis (NE) is a major disease of chickens caused by toxins of *Clostridium perfringens* type A and C, with typical hallmark in small intestinal necrosis (Umar *et al.*, 2016). NE has increased in occurrence and severity over the years. In clinical form, NE causes high mortality and in subclinical forms, affects growth and feed conversion. It is one of the most common and economically devastating

bacterial diseases of chickens in terms of performance, welfare and mortality (Wade & Keyburn, 2015). NE in chickens was first reported in the 1950s and subsequently in periodic episodes over time, depending on the region. NE is a multi-factorial disease process, in which a number of co-factors are usually required to precipitate an outbreak of the disease. The onset of NE is associated with a shift in

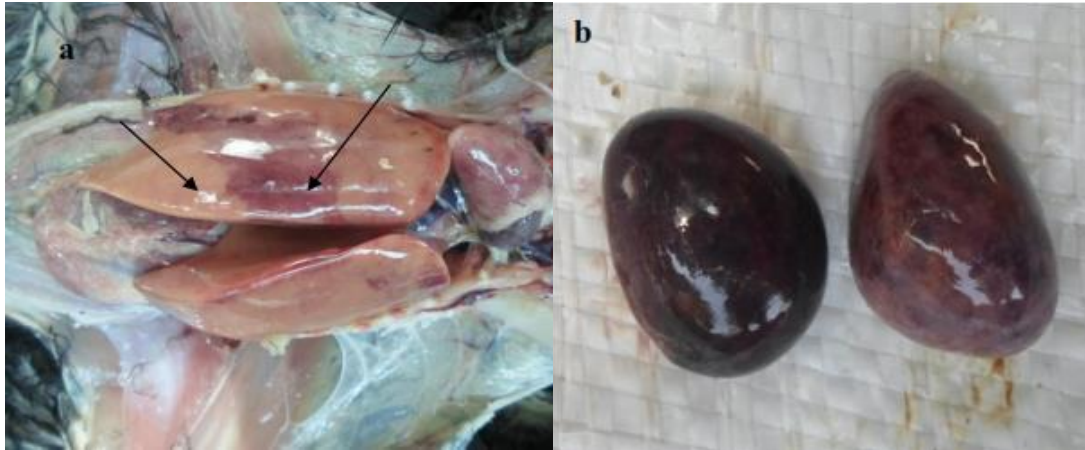


Plate I: Liver. Note (a) extensive local haemorrhages in the liver with pale areas (arrows); (b) severely enlarged, mottled and congested spleen

the microbiota present within the gastrointestinal tract (GIT) (Antonissen *et al.*, 2016).

Case Report

Case history

Four dead pullets from a flock of 4,500 were presented to the Avian clinic, Veterinary Teaching Hospital Ahmadu Bello University Zaria on 14th October, 2016. The birds were 13 weeks old and raised in a commercial poultry farm at Dan Maigauta village 4.7 Km off Danja Road, Katsina State.

The chief complaint was persistent mortality, which started 2 weeks prior to presentation and as at the day of presentation 280 birds had died (6.2%). The birds were kept on deep litter, fed on commercial grower mash (Vital feed) and treated with Amprolium 250 WSP® (Amprolium Hcl) at 1g/L of water for 5 days. When mortality continued, Diclacox® (Diclazuril) at 1ml/2L of water was administered for 2 days, after 48 hours Vitacox Plus wsp® (Sulphadimidine sodium, sulphaquinoxaline sodium, diaveridine HCl, vitamin A and Vitamin K3) at 1g/L of water in combination with Miavit® (Multivitamins) at 1 mL/20L of water for 5 days were administered. The flock was vaccinated against Marek’s disease, Newcastle disease and Gumboro disease. History further revealed that approximately 500 birds were sick.

Repeated farm visits were made and analysis was made on the clinical presentations of the disease, farm records including source of the chicks, breed, vaccination, age, major clinical signs observed, intervention and the mortality rate were recorded. Moribund and dead birds were collected and thorough post-mortem examination was conducted.

Table 1: Haematological indices of the affected chicken

Parameters	Patient’s value	Reference value
Packed cell volume (%)	26	24-43
Haemoglobin (g/dl)	8.6	8.9-13.5
White blood cell (x 10 ⁹ /L)	18.6	19.8-32.6
Heterophils (%)	18	19.8-32.6
Lymphocytes (%)	80	45.0-75.0
Monocytes (%)	0	8.1-16.5
Eosinophils (%)	0	1.5-2.7
Basophils (%)	0	1.7-4.3
Total protein (g/dl)	4.0	3.3-5.5

Reference values: Campbell (1994)

Clinical manifestation and post mortem findings

The clinical signs observed in the chickens upon farm visit were ruffled feathers, weakness, somnolence, lost of weight and watery faeces. The post mortem findings were emaciated carcasses with lean abdominal fat. The liver was enlarged, pale and haemorrhagic (Plate Ia). The spleen was severely enlarged, mottled and congested (Plate Ib). The duodenum was oedematous with mucus and diphtheritic membranes found on the jejunal mucosa (Plate II). The kidneys were enlarged. All other organs were grossly normal.

Sample collection and processing

Tissues were collected for bacteriological, histopathological, and haematological examinations. Liver was sent for bacterial culture and identification. Blood was sent for haemogram while tissues including liver, spleen, intestine and kidneys were fixed in 10% neutral buffered formalin for histological examination. Microbiology result of liver sample showed *Clostridium spp.* Histopathology result of intestine showed diffused necrosis of epithelial cells

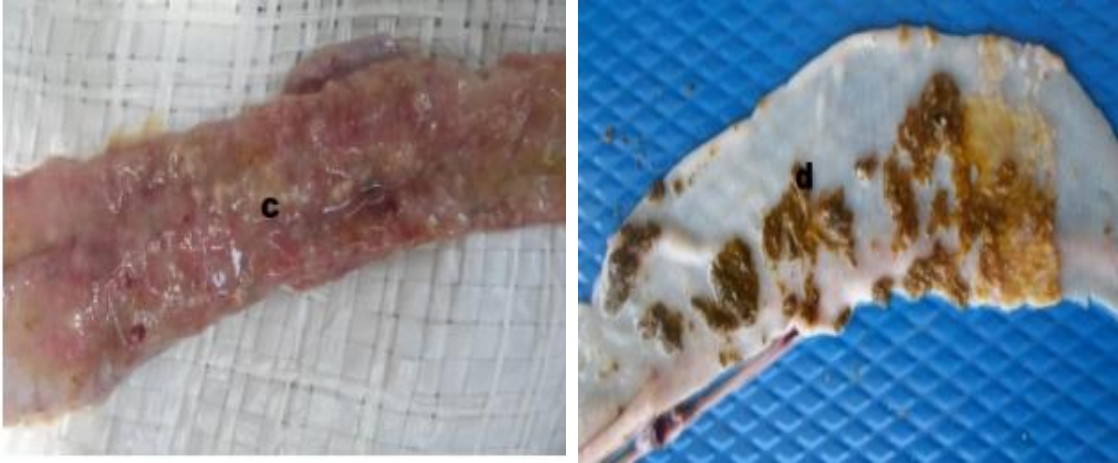


Plate II: (c) Inflamed duodenal mucosa and (d) diphtheritic membrane on the jejunal mucosa

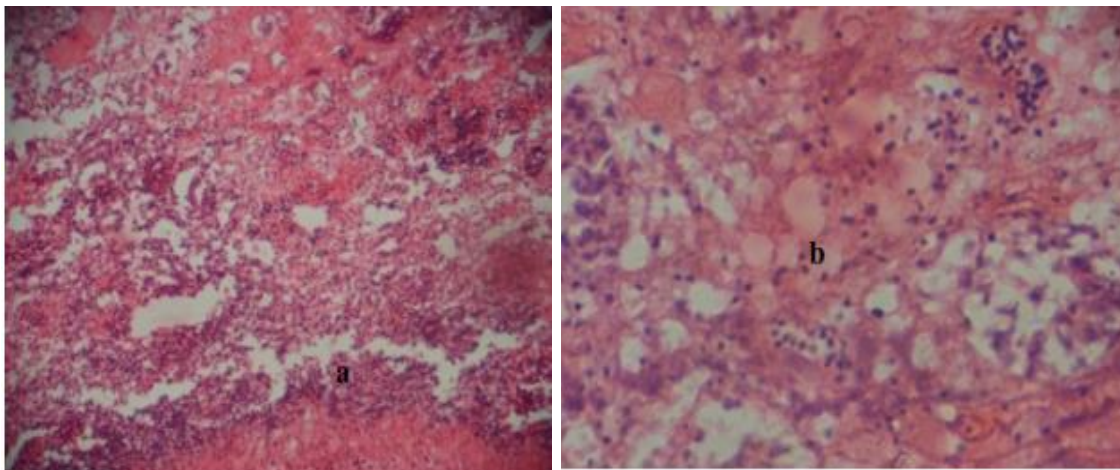


Plate III: Photomicrograph of intestine, Note; diffused necrotic epithelium with marked mononuclear cells infiltration in the mucosal area (a), severe oedema fluid (b). H & E. x 100 and 200, respectively

with marked mononuclear cells infiltration in the mucosal area. There was also sloughing off of the epithelium with severe oedema fluid in the intestine (Plate III).

Management

After tentative diagnosis was made, triple sulfa[®] (sulfadimidine sodium, sulfadiazine sodium and sulfamerazine sodium) at 1g/L of drinking water for 5 days was administered but there was very little response. Then Tridox[®] (20 % Oxytetracycline Long Acting) 2x at 3 days interval was administered at 100mg/bird intramuscularly, yet the mortality increased. Enterocillin[®] (Amoxycillin trihydrate and Colistin sulphate) was subsequently prescribed and administered at 1g/L of drinking water for 3 days. Following confirmatory diagnosis from the laboratory result, Copper sulphate was then administered at 1g/5L of drinking water. The pullets responded very

well with the copper sulphate treatment and the mortality was stopped.

Discussion

The clinical presentation of this case depicted NE in which most of the lesions are limited to the small intestine particularly the duodenum and jejunum. This is typically seen in NE infection as described by Opengart (2008). Lesions were also observed in the liver, spleen and kidneys. Clinically *C. perfringens* associated liver disease is cholangiohepatitis which is associated with both forms due to the toxin production (Kaldhusdal & Lovland, 2000).

The disease was initially diagnosed as coccidiosis, although NE may occur concurrently with coccidiosis as reported by M'Sadeq *et al.* (2015). Unfortunately, in this case the treatment was only focused on the coccidiosis using agents like Amprolium 250[®], Diclazuril[®] and Vitacox[®]. The use of these drugs without appropriate diagnosis had caused more

economic losses, drug resistance and toxicity which probably resulted in more mortality during the course of the treatment. The drugs used in an attempt to treat the condition proved ineffective as several agents were used without improvement. It is pertinent to note that the highest mortality was recorded during the oxytetracycline medication 184 birds (Figure 1) which was known to be the second most effective drug of choice against the disease. This could be as a result of stress of catching and possible injecting the bird in veins. It has been clear that antimicrobials and ionophore coccidiostats have played a major role in keeping the disease under control (Kaldhusdal *et al.*, 2016). The mortality rate recorded (18.2 %) was not consistent with the report of Dhillon *et al.* (2004), who reported NE mortality rate of 6.5 % in layers. The haematological values indicated

lymphocytosis (Table 1); which is not surprising as there was reaction of the damaged tissues to the pathogens and the toxins produced. This also supported the findings of Olkowski *et al.* (2006) who reported the histopathological changes observed in the duodenal mucosa of small intestine.

Three basic strategies used in the control of NE was suggested by M'Sadeq *et al.* (2015). These were amplification of immune response, pathogen reduction and dietary modification and/or use of feed additives. But in this case the copper sulphate given seemed to have ameliorated the condition by the cessation of mortality.

Conflicts of Interest

The authors declare no conflict of interest.

References

Antonissen G, Eeckhaut V, Van Driessche K, Onrust L, Haesebrouck F, Ducatelle R, Moore RJ & Van Immerseel F (2016). Microbial shifts associated with necrotic enteritis. *Avian Pathology*, **45**(3): 308-312.

Campbell TW (1994). Haematology. In: *Avian Medicine: Principles and Application*. (BW Ritchie, GJ Harrison, LR Harrison, editors). Wingers Publishers Incorporated, Lake Worth, Florida, USA. Pp 176–198.

Dhillon AS, Roy P, Lauerman L, Schaberg D, Weber S, Bandli D & Wier F (2004). High mortality in egg layers as a result of necrotic enteritis. *Avian Diseases*, **48**(3): 675–680.

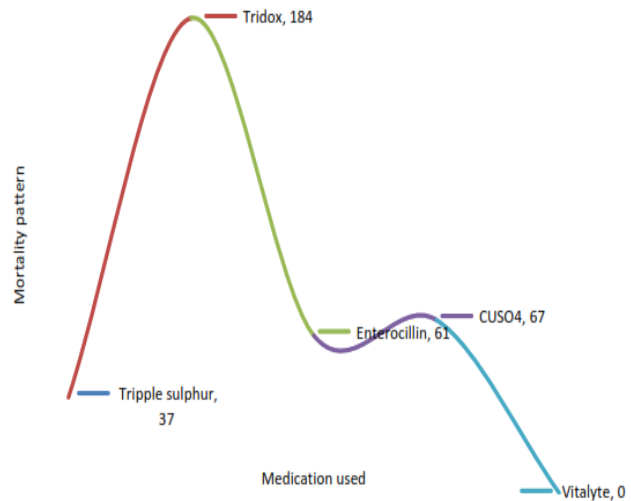


Figure 1: The mortality recorded during the different medication stages of 13-weeks old commercial pullets with necrotic enteritis

Kaldhusdal M, Benestad SL & Løvland A (2016). Epidemiologic aspects of necrotic enteritis in broiler chickens—disease occurrence and production performance. *Avian Pathology*, **45**(3): 271-274.

Kaldhusdal M & Lovland A (2000). The economical impact of *Clostridium perfringens* is greater than anticipated. *World Poultry Journal*, **16**(1): 51 – 52.

M'Sadeq SA, Wu S, Swick RA & Choct M (2015). Towards the control of necrotic enteritis in broiler chickens with in-feed antibiotics phasing-out worldwide. *Animal Nutrition*, **1**(1): 1-11.

Olkowski AA, Wojnarowicz C, Chirino-Trejo M & Drew MD (2006). Responses of broiler chickens orally challenged with *Clostridium perfringens* isolated from field cases of necrotic enteritis. *Research in Veterinary Sciences*, **81**(1): 99-108.

Opengart K (2008). Necrotic enteritis. In: *Diseases of Poultry*, YM Saif, AM Fadly, JR Glisson, LR McDougald, LK Nolan, DE Swayne, editors), twelfth edition, Blackwell Publishers, Ames, Iowa. Pp 872-879.

Umar S, Younus M, Shahzad M, Aqil K, Qayyum R, Mushtaq A, Shah MA & Munir MT (2016). Role of wheat-based diet on the pathology of necrotic enteritis in Turkeys. *Scientifica*, 1-8. Article ID 4381067, 1-8.

Wade B & Keyburn A (2015). The true cost of necrotic enteritis. *World Poultry Journal*, **31**(7): 16-17.