



Effects of the methanol leaf extract of *Palisota hirsuta* in post-surgical wound management

C Unamba-Oparah^{1*}, IC Unamba-Oparah², CA Eze³ & AO Anaga⁴

^{1.} Department of Veterinary Surgery and Radiology, Michael Okpara University of Agriculture, Umudike, Abia State, Nigeria

^{2.} Department of Veterinary Pathology, Michael Okpara University of Agriculture, Umudike, Abia State, Nigeria

^{3.} Department of Veterinary Surgery and Radiology, University of Nigeria, Nsukka, Nigeria

^{4.} Department of Veterinary Physiology and Pharmacology, University of Nigeria, Nsukka, Nigeria

*Correspondence: Tel.: +2348030942147; E-mail: unambaoparahc@gmail.com

Copyright: © 2018 Unamba-Oparah *et al.* This is an open-access article published under the terms of the Creative Commons Attribution License which permits unrestricted use, distribution, and reproduction in any medium, provided the original author and source are credited.

Publication History:
Received: 23-12- 2017
Accepted: 13-03-2018

Abstract

Plants are important in the management and treatment of wounds. Their medicinal values lie in their phytochemical constituents. *Palisota hirsuta* Reichb. Ex Endl (Commelinaceae) is used traditionally in the treatment of diseases and wounds. This study evaluates the effects of methanol leaf extract of *Palisota hirsuta* (MLEPH) in post-surgical wound management, using incision and dead space wound models in rats. Thirty albino rats were used for each model (n=30) by assigning into 5 groups of 6 each. In the incision wound model, an incision wound created surgically on the dorsum of each rat was treated daily by topical application of: Petroleum Jelly (PJ, Group I), Cicatrin® powder (Group II), 1% w/w MLEPH (Group III), 2% w/w MLEPH (Group IV) and 4% w/w MLEPH (Group V) for 10 postoperative days. Wound breaking strength and histopathology were evaluated. In the dead space wound model, a sterilized polypropylene tube was implanted in the left groin region of each rat. They were treated orally daily for 10 postoperative days as follows: 10 mL/kg 5 % Dimethylsulfoxide (DMSO, Group I), 12.5 mg/kg MLEPH (Group II), 25 mg/kg MLEPH (Group III), 50 mg/kg MLEPH (Group IV) and 100 mg/kg MLEPH (Group V). Granulation tissue formation and hydroxyproline assay were assessed. The results showed that wound breaking strength was significantly (p<0.05) higher in the MLEPH and Cicatrin® treated groups. MLEPH (4 %w/w) showed the highest wound breaking strength. This was confirmed by histopathological sections of the healing skin which showed 4% w/w MLEPH (Group V) to have the best wound healing effect. Dry granulation tissue weight was significantly (p<0.05) higher in groups IV and V. Also, the hydroxyproline content was significantly (p<0.05) higher in MLEPH treated groups III-V. From the results obtained, MLEPH has wound healing effects and can be used in post-surgical wound management.

Keywords: Incision, *Palisota hirsuta*, Post-surgical, Rats, Wound

Introduction

Extracts from plants are very important in the traditional management and treatment of many diseases. A large majority of people globally rely on herbs for various skin diseases (Raja & Sundar, 2015)

including wounds. These herbs are not only readily available, but are also cheap and affordable. The presence of life-preserving constituents in plants has made scientists to study these plants with a view to

identify potential wound healing properties inherent in them (Nayak & Pinto, 2006). Consequently, more than 70% of wound healing pharmaceutical products are plant based (Kumar *et al.*, 2007), with their medicinal values lying in their phytochemical constituents including alkaloids, flavonoids, essential oils, tannins, terpenoids, saponins and phenolic compounds (Akinmoladun *et al.*, 2007).

Palisota hirsuta Reichb. ex Endl (family Commelinaceae) is a tropical West African plant (Akobundu *et al.*, 1987). It is a robust perennial herb of about 3m high, known in some parts of Nigeria as *ikpere aturu* (Igbo), *akerejupon* (Yoruba) and *ighigewe* (Edo) (Akobundu *et al.*, 1987).

The preparation of the different plant parts are used traditionally in the treatment of skin infections, gastrointestinal disorders, hemorrhoids, kidney problems, nasopharyngeal infections, venereal diseases, oedema, gout, gun-shot wounds and swellings (Burkill, 1985).

The documented biological activities of the plant include narrow spectrum antibacterial and local anaesthetic activity (Anaga *et al.*, 2009a), liver protective activity (Anaga *et al.*, 2009b) and antinociceptive property (Woode *et al.*, 2009).

The dearth of information on the wound healing activity of *Palisota hirsuta* necessitated this study which evaluates the effects of the methanolic plant extract in post-surgical wound management, using incision and dead space wound models.

Materials and Methods

Plant material

Palisota hirsuta leaves were collected in March, from Orba in Udenu Local Government Area of Enugu State, Nigeria. These leaves were identified by a plant taxonomist in the Department of Botany, University of Nigeria, Nsukka. In the herbarium of the department, a voucher specimen annotated (UNN/BD.3912.04) was kept.

Experimental animals

Sixty male albino rats were used for the incisional and dead space wound models, aged 3-4 months, with mean weight of 175.40 ± 4.42 g were obtained from the Laboratory Animal Unit of the Faculty of Veterinary Medicine, University of Nigeria, Nsukka and used for the study. The rats were housed individually in stainless steel cages at room temperature and fed commercial feed (Vital[®] Growers feed, GCOML, Jos, Nigeria) and water *ad-libitum* throughout the course of the study. They were acclimatized for 2 weeks before the

commencement of the experiment and maintained in accordance with the recommendation of the *Guide for the care and use of laboratory animals* (DHHS, 2011).

Plant preparation

The fresh leaves of the plant, *Palisota hirsuta* were air-dried under shade. Using a hammer mill (Thomas-Wiley Laboratory Mill, USA), the dried leaves were pulverized into coarse powder and 500 g of the pulverized leaves was defatted with 100% hexane (Sigma-Aldrich Laborchemikallen GMBH, Germany) for 24 h with intermittent shaking. Further extraction with 100% methanol (Sigma-Aldrich Laborchemikallen GMBH, Germany) for 48 h with intermittent agitation was carried out. The extract obtained was concentrated *in vacuo* using rotary evaporator (Buchi Labortechnik, Switzerland) at 40°C (Handa *et al.*, 2008), designated methanol leaf extract of *Palisota hirsuta* (MLEPH) and stored at 4°C before use.

Incision wound model

The modified method described by Kokane *et al.* (2009) was used in this experiment. The thirty male rats used for this study were randomly assigned into 5 groups of 6 rats each. The rats were sedated with Xylazine (Indian Immunologicals Limited, Goliapadu, India) (5 mg/kg body weight intramuscularly) and after 5 minutes, received ketamine hydrochloride (Rotexmedica, Germany) injection (35 mg/kg body weight intramuscularly).

The dorsa of the rats (1 cm left of the vertebral column and 5 cm from the ear) were clipped liberally and disinfected using chlorhexidine (Purit[®], Nigeria) solution.

Each rat was positioned on ventral recumbency after preparation and anaesthesia. An incision wound 6 cm length x 2 mm depth was aseptically made through the skin and subcutis, 1 cm to the left of the vertebral ridge and 5 cm from the ear. The incision wound was sutured with size 3-0 silk (Anhuikang, China) using simple interrupted suture pattern. Wounding day was considered as day 0.

The 1% w/w, 2% w/w and 4% w/w MLEPH were prepared by suspending 1 g, 2 g and 4 g of MLEPH in 99 g, 98 g and 96 g of 100% Petroleum Jelly (PJ) (Unilever, Nigeria) respectively. The incision wounds created on all the rats were treated topically and once daily for 10 post-surgical days (PSD) as follows:
Group I –0.5 g 100% PJ, Negative control
Group II –0.5g 100% Cicatrin[®] powder (Neomycin Sulphate BP-1650 units and Bacitracin Zinc BP-

125units, GlaxoSmithKline, Pakistan), Positive control

Group III – 1% w/w MLEPH

Group IV - 2% w/w MLEPH

Group V - 4% w/w of MLEPH.

The stitches were removed on PSD 8. On PSD 10, the breaking strengths of the healed wounds were measured with a tensiometer using the continuous constant water technique (Kokane *et al.*, 2009). Each rat was positioned on ventral recumbency on the tensiometer with a clip anchored on either side of and equidistant to the healing wound. Water was continuously allowed to drip into a water holder until the wound tore/broke. The water was weighed and recorded.

Histopathology

Samples of the healing tissue were harvested under anaesthesia on PSD 10 from all groups and fixed in 10 % phosphate buffered formalin (Sigma-Aldrich Laborchemikallen GMBH, Germany) for 48 h. They were dehydrated in ascending concentrations of alcohol (Sigma-Aldrich Laborchemikallen GMBH, Germany), cleared in xylene (Sigma-Aldrich Laborchemikallen GMBH, Germany) for 1 h 30 minutes, and embedded in paraffin wax. Sections 5 µm thick were made and mounted on slides. The slides were stained with hematoxylin (Sigma-Aldrich Laborchemikallen GMBH, Germany), counterstained with eosin (Sigma-Aldrich Laborchemikallen GMBH, Germany) (H & E stains) and viewed under a light microscope (Bancroft, 2008).

Dead space wound model

The modified method of Nayak *et al.* (2007) was adopted for this experiment. A total of 30 male rats were used and they were randomly assigned into 5 groups of 6 rats each. The left groin region of the rats were liberally clipped and disinfected with chlorhexidine solution. The rats were sedated with Xylazine (5 mg/kg body weight intramuscularly), followed by induction of anaesthesia with Ketamine hydrochloride (35 mg/kg body weight intramuscularly).

Each rat was placed on dorsal position and a nick was made on the clipped area. Dead space wound was created by implanting a sterilized polypropylene tube (2.5 cm length by 0.25 cm diameter) into the nick using sterile forceps. The wound was sutured by placing one or two silk interrupted sutures. The day of surgical implantation was considered as PSD 0.

MLEPH was dissolved in 5 % dimethylsulfoxide (DMSO) and administered orally, once daily for 10 post-surgical days (PSD) as follows:

Group I (Negative control)- 10 ml/kg 5 % DMSO

Group II- 12.5 mg/kg MLEPH

Group III- 25 mg/kg MLEPH

Group IV- 50 mg/kg MLEPH

Group V- 100 mg/kg MLEPH.

On PSD 10, the rats were euthanized using three times the anaesthetic dose of Thiopental sodium (Panpharma, Rotexmedica France) for rats. An incision was made on the skin close to the implant. The implanted tubes were removed and granulation tissues formed on the tubes were harvested. The granulation tissues were weighed using a weighing balance to get the wet weight. They were dried in an oven at 42°C for 16 h and weighed to determine their dry weights (Nayak & Pinto, 2006).

Hydroxyproline assay

A modified method of Gurung & Skalko-Basnet (2008) was adopted for the hydroxyproline assay. Each dried granulation tissue (50 mg) was added to 1 ml 6 N HCl (Sigma-Aldrich Laborchemikallen GMBH, Germany) and autoclaved (Axiom Medical Ltd U.K) at 15 pound pressure for 3 hours. The acid hydrolysate obtained was neutralized with sodium hydroxide (Sigma-Aldrich Laborchemikallen GMBH, Germany) and made up to 10 ml with distilled water. One millilitre of each neutralized hydrolysate served as the test sample for the determination of the hydroxyproline content. Pipetted in succession into each test tube were 1 ml 0.01 M Copper sulphate (Sigma-Aldrich Laborchemikallen GMBH, Germany), 2.5 N Sodium hydroxide (Sigma-Aldrich Laborchemikallen GMBH, Germany) and 6 % Hydrogen peroxide (Sigma-Aldrich Laborchemikallen GMBH, Germany). The solution in each tube was mixed and shaken occasionally for a period of 5 minutes, after which the tubes were placed in a water bath at 80°C for 5 minutes with frequent vigorous shaking. The tubes were chilled in ice and water bath. Into each tube, 4 ml of 3 N Sulphuric acid (H₂SO₄) (Sigma-Aldrich Laborchemikallen GMBH, Germany) was added with agitation. Two millilitres (2 ml) p-dimethylaminobenzaldehyde (Sigma-Aldrich Laborchemikallen GMBH, Germany) solution was added to each tube and the content of each tube was thoroughly mixed. The tubes were placed in a water bath at 70°C for 16 minutes, and in tap water to cool. The content of each tube was transferred into a cuvette and read at 540 nm wavelength. Test tube 1 was the blank. The amount of hydroxyproline

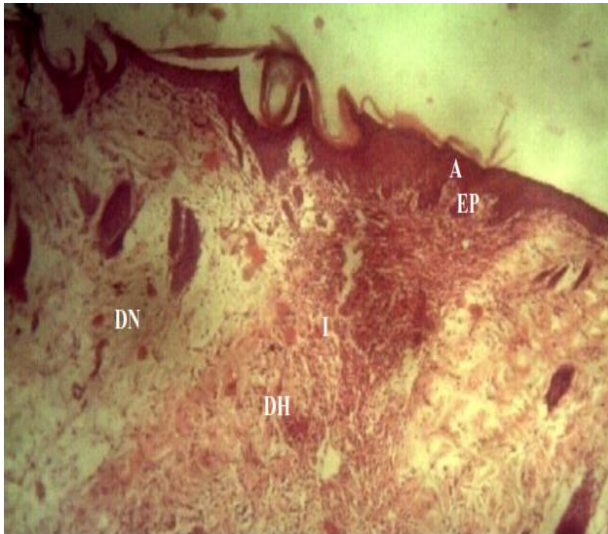

Plate I: Histopathological section of the skin from rats treated with PJ (Group I) x 10. (H&E stain)
A, Acanthosis; I, the incision line showing no adnexia; EP, Epidermal peg; DN, Dermis of the normal skin; DH, Dermis of healing skin

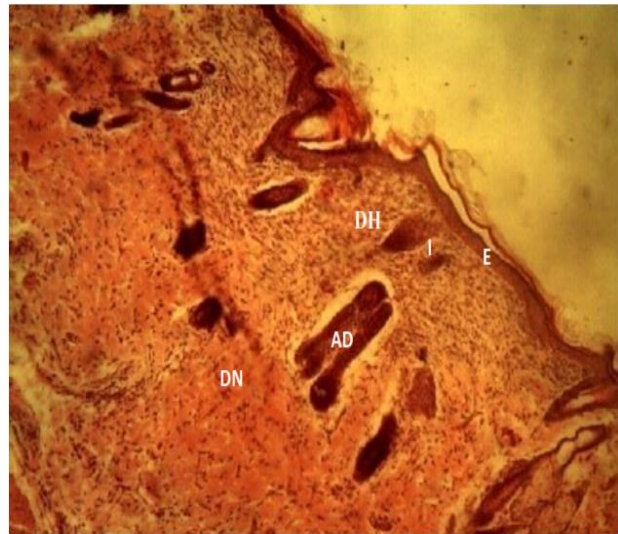


Plate II: Histopathological section of the skin from rats treated with Cicatrin® (Group II) x 10. (H&E stain)
I, line of incision; AD, Adnexia; E, Epidermis; DN, Dermis of the normal skin; DH, Dermis of healing skin

was established using a standard curve prepared with pure L-hydroxyproline at the same time.

Data analysis

Statistical analysis was performed using SPSS software® (Version 13.0 for Windows, SPSS Inc., Chicago, USA). The data were presented as mean ± standard deviation (SD) and analyzed using one way analysis of variance. The variant means were separated using least significant difference (LSD) post hoc test at $p < 0.05$.

Results

Effect of MLEPH on wound breaking strength

The results as presented in Figure 1 showed that the wound breaking strength of 427.01 ± 39.07 , 451.49 ± 20.94 , 550.58 ± 25.55 and 569.57 ± 10.88 g for groups II-V respectively were significantly ($p < 0.05$) higher than that of group I (391.94 ± 39.59 g). MLEPH-treated groups IV (550.58 ± 25.55 g) and V (569.57 ± 10.88 g) showed significantly ($p < 0.05$) higher wound breaking strength than group II (427.01 ± 39.07 g).

Histopathology of the Effect of MLEPH on incision healing wound

The Healing skin sections from PJ-treated group I showed the absence of adnexa, presence of

Table 1: Effect of MLEPH on Granulation Tissue formation

Groups	Treatments	Wet granulation(g)	Dry granulation (g)
I	10 ml/kg DMSO	0.30 ± 0.05	0.06 ± 0.02
II	12.5 mg/kg MLEPH	0.42 ± 0.02^a	0.10 ± 0.00
III	25 mg/kg MLEPH	0.47 ± 0.05^a	0.11 ± 0.02
IV	50 mg/kg MLEPH	0.65 ± 0.05^a	0.18 ± 0.02^a
V	100 mg/kg MLEPH	0.81 ± 0.15^a	0.28 ± 0.10^a

Values are expressed as Mean ± SEM (n=6)

^a $p < 0.05$ when compared to control (group I)

acanthosis of the epidermis and epidermal pegs (Plate I) while the healing skin sections of the Cicatrin®-treated group II showed development of adnexa at the incision line, absence of acanthosis but the epidermis was not as near-normal as in MLEPH-treated group V (Plate II). MLEPH- treated group V showed development of more adnexa, absence of acanthosis and a near-normal epidermis and dermis (Plate III).

Effect of MLEPH on granulation tissue formation

The wet granulation tissue was significantly ($p < 0.05$) higher in MLEPH-treated groups than in the DMSO-treated (control) group. When dry, the granulation tissue in MLEPH-treated groups IV (0.18 ± 0.02 g) and V (0.28 ± 0.10 g) were significantly ($p < 0.05$) higher than the control (0.06 ± 0.02 g). However, groups II and III showed no significant ($p > 0.05$) variation from the control (Table 1).

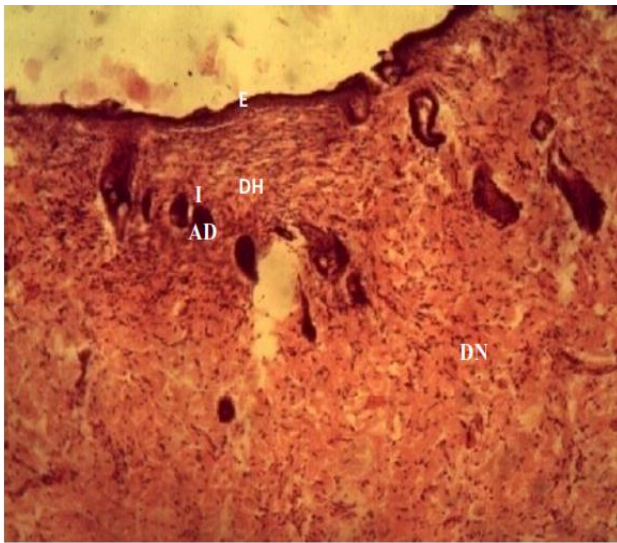


Plate III: Histopathological section of the skin from rats treated with MLEPH (Group V) x 10.(H&E stain) I, line of incision; AD, Adnexia; DH, Dermis of healing skin; DN, Dermis of the normal skin; E, Epidermis

Effect of MLEPH on hydroxyproline content

In the dead space wound model, hydroxyproline content was 433.32 ± 7.35 , 469.28 ± 6.56 , 460.00 ± 27.31 mg/100g dry tissue for groups III, IV and V, respectively; and was significantly ($p < 0.05$) higher than that of group I (394.68 ± 15.85 mg/100g dry tissue) (Figure 2).

Discussion

The effects of the methanolic leaf extract of *Palisota hirsuta* on post-surgical wound management using different wound models were studied in rats. The results demonstrated the efficacy of MLEPH in post-surgical wound management. The wound breaking strength is a measure of the rate of collagen synthesis and also the maturation process (Tara *et al.*, 2006). The rats that received the extract at 4 % w/w showed the highest wound breaking strength. This is in agreement with the findings of the author where 4 % w/w MLEPH in excision wound model had the best activity, reducing epithelialization period and increasing percentage wound contraction (Unamba-Oparah *et al.*, 2017). The histopathology of the healing skin sections in incision wound model further confirmed the above result in that the skin sections from MLEPH-treated group V (4 % w/w) (the best of the MLEPH-treated groups in wound healing activity) showed proliferation of adnexa, absence of acanthosis and a near-normal epidermis and dermis, a mark of advanced wound healing compared to the

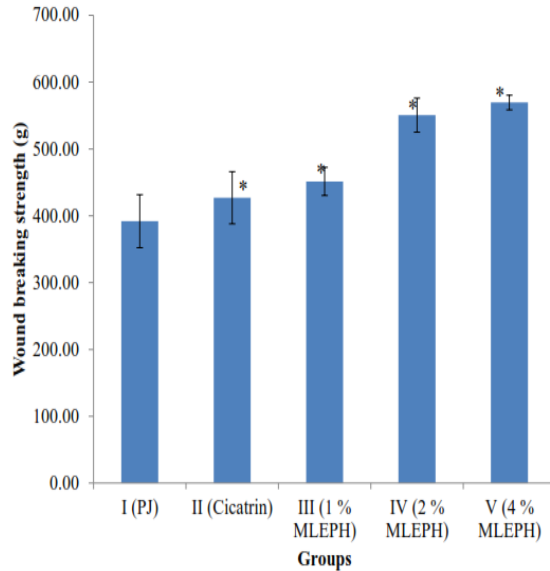


Figure 1: Effect of MLEPH on Wound breaking strength *P < 0.05 when compared with control (group I)

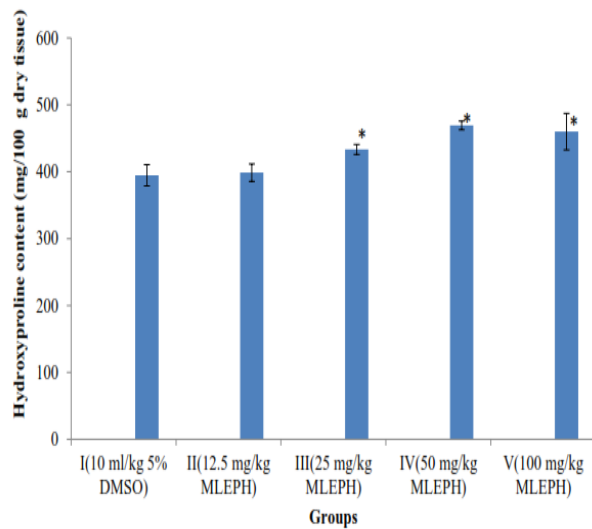


Figure 2: Effect of MLEPH on Hydroxyproline content *P < 0.05 when compared to control (group I)

control group (PJ) which showed evidence of delayed healing with absence of adnexa, presence of acanthosis of the epidermis and epidermal pegs. The Cicatrín® treated group showed development of adnexa, absence of acanthosis but the epidermis and dermis were not as near-normal as observed in the 4% w/w MLEPH treated group V; a confirmation that the wound healing activity of Cicatrín® treated group II was not as good as that of MLEPH-treated group V. The significantly higher wet and dry weights of the granulation tissue (MLEPH-treated groups IV and V)

and higher hydroxyproline content in MLEPH-treated groups III-V was a proof of high collagen lay and maturation. Also, the higher weight of dry granulation tissue was an indication of the presence of higher protein content (Muralidhar *et al.*, 2011). Anaga *et al.*, (2009a) have shown the phytochemical constituent of the methanol leaf extract of *P. hirsuta* to include tannins, flavonoids, glycosides and proteins, with tannins and flavonoids being the dominant constituent. Flavonoids, due to their astringent, antimicrobial and antioxidant effects (Soni & Singhai, 2012) may be responsible for the wound healing activities of this plant.

In conclusion, the extract significantly increased the wound healing indices like: wound breaking strength, granulation tissue formation and hydroxyproline content. The best activity of the extract was seen at 4% w/w concentration (wound breaking strength) and 50 mg/kg (hydroxyproline content). The results therefore showed that *P. hirsuta* leaf extract has wound healing effects and can be utilized in post-surgical wound management. Further studies to isolate/separate the active principle(s) in *P. hirsuta* responsible for its wound healing activity are recommended.

References

- Akinmoladun AC, Ibukun EO, Afor E, Akinrinlola BL, Onibon TR, Akinboboye O, Obuotor EM & Farombi EO (2007). Chemical constituents and antioxidant activity of *Alstonia boonei*. *African Journal of Biotechnology*, **6**(10): 1197–1201.
- Akobundu IO & Aggakwa CW (1987). A Handbook of West African Weeds. International. Institute of Tropical Agriculture, Ibadan, 1-521.
- Anaga AO, Eke IG & Chah KF (2009a). Some pharmacological properties of methanolic extract of *Palisota hirsuta* leaves. *Tropical Veterinarian*, **27**(4): 37-47.
- Anaga AO, Ndukwe CP & Shoyinka SVO (2009b). Hepatoprotective effect of the methanolic leaf extract of *Palisota hirsuta* against CCl₄ - induced hepatic damage in mice. *Tropical Veterinarian*, **27**(1): 17-27.
- Bancroft JD (2008). Theory and Practice of Histological Techniques. Elsevier Health Sciences, Philadelphia. Pp 217-365.
- Burkill HM (1985). The useful plants of West Tropical Africa. Royal Botanic Gardens, Kew. Pp 405.
- Department of Health and Human Services (2011). *Guide for the Care and Use of Laboratory Animals*. National Research Council, National Academy, Washington DC., **46**:1-246.
- doi.org/10.1163/1573-3912.
- Gurung S & Skalko-Basnet N (2008). Wound healing properties of *Carica papaya* latex: In vivo evaluation in mice burn model. *Journal of Ethnopharmacology*, doi.org/10.1016/j.jep.2008.10.030.
- Handa SS, Khanuja SPS, Longo G, Rakesh DD (2008). Extraction Technologies for Medicinal and Aromatic Plants. First edition, no. 66.: United Nations Industrial Development Organization and the International Centre for Science and High Technology, Italy. Pp 22-33.
- Soni H & Singhai AK (2012). A recent update of botanicals for wound healing activity. *International Research Journal of Pharmacology*, **3**(7): 1-7.
- Kokane DD, More RY, Kale MB, Nehete MN, Mehendale PC & Gadgoli CH (2009). Evaluation of wound healing activity of root of *Mimosa pudica*. *Journal of Ethnopharmacology*, **124**(2): 311–315.
- Kumar B, Vijayakumar M, Govindarajan R, & Pushpangadan P (2007). Ethnopharmacological approaches to wound healing-exploring medicinal plants of India. *Journal of Ethnopharmacology*, **114**(2): 103-113.
- Muralidhar A, Babu KS, Sankar TR, Reddanna P & Latha J (2011). Evaluation of wound healing properties of bioactive fractions from the extract of *Butea monosperma* (lam) stem bark. *International Journal of Phytomedicine*, **3**(1): 41–49.
- Nayak B & Pereira LMP (2006). *Catharanthus roseus* flower extract has wound-healing activity in Sprague Dawley rats. *BMC Complementary and Alternative Medicine*, **6**(1):41.
- Nayak BS, Pereira LP & Maharaj D (2007). Wound healing activity of *Carica papaya* L. in experimentally induced diabetic rats. *Indian Journal of Experimental Biology*, **45**:739–743.
- Raja NRL & Sundar K (2015). Promotion of wound healing by leaf extracts of *sesbania aegyptiaca* in albino rats. *Research Journal of Medicinal Plant*, doi.org/10.3923/rjmp.2015.116.126.
- Tara VS, Chandrakala S, SachidanandaA, Kurady BL, Smita S & Ganesh S (2006). Wound healing activity of alcoholic extract of *Kaempferia galanga* in Wistar rats. *Indian Journal of Physiology and Pharmacology*, **50**(4): 384–390.
- Unamba-Oparah C, Unamba-Oparah IC, Eze CA & Anaga AO (2017). Evaluation of wound healing and antibacterial activities of *Palisota hirsuta* methanol leaf extract. *Journal of Veterinary*

and Applied Sciences, **7**(1):21-28.
Woode E, Boakye-Gyasi E, Ainooson GK, Ansah C & Duwiejua M (2009). Anti-Nociceptive Effects and the Mechanism of *Palisota hirsuta* K.

Schum. Leaf Extract in Murine Models. *International Journal of Pharmacology*, **5**(2): 101-113.