



Incidence, indication and prognosis of ovariohysterectomy in dogs in Abeokuta, Nigeria

TA Ajadi^{1*}, FA Makinde², OO Adebayo² & AI Adeleye²

¹ Department of Veterinary Public Health and Reproduction, Federal University of Agriculture, Abeokuta, Ogun State, Nigeria

² Veterinary Teaching Hospital, Federal University of Agriculture, Abeokuta, Ogun State, Nigeria

*Correspondence: Tel.: +2349086456080; E-mail: ayisat_ajadi@yahoo.com

Copyright: © 2018 Ajadi *et al.* This is an open-access article published under the terms of the Creative Commons Attribution License which permits unrestricted use, distribution and reproduction in any medium, provided the original author and source are credited.

Publication History:
Received: 24-10- 2017
Accepted: 09-01-2018

Abstract

Case records of dogs that underwent ovariohysterectomy at the Veterinary Teaching Hospital, Federal University of Agriculture, Abeokuta (FUNAAB) between January, 2010 and December, 2016 were reviewed to determine the prevalence, indication and prognosis of this surgical condition. Data recorded include breed and age of the dogs at presentation and reason for ovariohysterectomy. Information on type of anaesthetic techniques, outcome of the surgery and occurrence and severity of complications were also noted. Ovariohysterectomy was performed in nine out of two thousand, two hundred and eighty five dogs that were presented during this period. The nine dogs included seven breed types which were Rottweiler (2), Samoyed (2), Alsatian (1), Doberman (1), Boerboel (1), Lhasa apso (1) and Pug (1). Mean age of the dogs presented for ovariohysterectomy was 5.7 ± 2.9 years with the age ranging between 18 months and 10 years. Indications for ovariohysterectomy in the dogs were pyometra (4), ovarian adenocarcinoma (2), transmissible venereal tumour (1), intra-uterine foreign body (1) and elective request (1). Surgical outcome was good in seven of the dogs, while one dog died secondary to hypovolemia after surgery and another dog was euthanized a week after surgery due to poor renal function. Five of the dogs had moderate obesity about six months after surgery, while a dog had mammary adenocarcinoma two years after ovariohysterectomy. It was therefore concluded that elective ovariohysterectomy is not routinely performed in dogs at the Veterinary Teaching Hospital, FUNAAB, while most cases are performed for management of reproductive tract diseases. Further data are required to authenticate or disprove the findings in this study.

Keywords: Adenocarcinoma, Elective, Ovariohysterectomy, Prevalence, Pyometra

Introduction

Ovariohysterectomy (OVH) is the surgical removal of the ovary and the uterus. It is performed both as an elective procedure and as a therapeutic surgical procedure to treat a number of female reproductive disorders. It can also be performed as an adjunct to a number of surgical procedures such as mastectomy to reduce the risk of recurrence of malignant mammary tumour (Kristiansen *et al.*, 2013) and

following surgical resection of vagina prolapse to prevent recurrence of the prolapse (Kim *et al.*, 2008) and a last resort for managing recurrent pyometra. OVH is a very common elective surgery in dogs in the United States. Current reports from the American Society for Prevention of Cruelty against Animals indicated that 83% female dogs are neutered (Belanger *et al.*, 2017). Benefits of elective OVH

include eliminating unintended reproduction which in turn reduces the number of dogs that are unwanted and euthanized in shelters, prevention of sexually transmitted disease, pregnancy toxemia, metabolic disease and dystocia (Kustritz, 2007; McKenzie, 2010). Elective OVH also helps to prevent reproductive disorders such as pyometra, mammary tumours and ovarian cancer (Belanger *et al.*, 2017). Numerous studies evaluating the correlation of behaviour with OVH have shown reduced aggression, roaming and urine marking. Neutering also reduces the risk of biting in certain breeds of dogs (Casey *et al.*, 2014), while ovariohysterectomized dogs have been shown to have lifespan increased by 26.3% compared to intact bitches (Hoffman *et al.*, 2013).

In spite of the benefits of OVH in dogs, several detriments have been associated with elective OVH in dogs. Elective OVH has been reported to increase the risk of occurrence of tumours such as transitional cell carcinoma, osteosarcoma and haemangiosarcoma (Kustritz, 2007) as well as increase the risk of occurrence of orthopaedic disorders such as hip dysplasia and cranial cruciate ligament rupture (Hart *et al.*, 2014). Other complications of ovariohysterectomy include obesity, urinary tract disorders, diabetes mellitus and hypothyroidism (Angioletti *et al.*, 2004; Lund *et al.*, 2006).

Despite the fact that castration and ovariohysterectomy are routinely performed in dogs in developed countries, castration is seldom performed in Nigeria. A survey of dog owners' perception about castration in dogs showed that most dog owners in Nigeria considered castration to be cruelty to dogs and are unwilling to castrate their dogs (Ajadi *et al.*, 2013). The same reason might apply to ovariohysterectomy in dogs in Nigeria. However, there appears to be dearth of information on records of ovariohysterectomy in dogs in Nigeria. This paper reviews the records of cases of ovariohysterectomy in dogs performed at the Veterinary Teaching Hospital, Federal University of Agriculture, Abeokuta, Ogun State, Nigeria.

Materials and Methods

Data collection

The case records of dogs presented at the Veterinary Teaching Hospital, Federal University of Agriculture, Abeokuta, Ogun State between January, 2010 and December, 2016 were reviewed to determine the frequency and indication for performing ovariohysterectomy in dogs. Data recorded include

breed and age of the dogs at presentation and the indication for ovariohysterectomy. Information on type of anaesthetic techniques, use of post-operative analgesic, use of post-operative antibiotics, outcome of the surgery and occurrence as well as severity of adverse effects such as obesity, orthopaedic problems, neoplastic diseases and urinary tract diseases were also noted.

Data analysis

The data obtained were subjected to descriptive statistics, while rate of performance of ovariohysterectomy was calculated as the percentage (%) of number of dogs presented for castration out of the total number of dogs registered at the hospital during that period.

Results

Out of the two thousand, two hundred and eighty five dogs registered at the Veterinary Teaching Hospital, FUNAAB during this period, there were only 9 recorded cases of ovariohysterectomy in dogs (Table 1) giving a rate of 0.39%. The breeds of dogs that were presented for ovariohysterectomy were 7 namely Rottweiler (2), Samoyed (2), Alsatian (1), Doberman (1), Boerboel (1), Lhasa apso (1) and Pug (1). Mean age of the dogs presented for ovariohysterectomy was 5.7 ± 2.9 years with the age ranging between 18 months and 10 years. Indications for ovariohysterectomy in the dogs were pyometra (4), ovarian adenocarcinoma (2), adjunct to transmissible venereal tumor (TVT) chemotherapy (1), intra-uterine foreign body (1), while only 1 of the dogs was ovariohysterectomized due to elective request. Out of the dogs diagnosed with pyometra, 3 had closed pyometra (Plate I & II), while 1 had recurring open pyometra. The 2 dogs with ovarian adenocarcinoma had cystic neoplastic ovarian mass attached to the kidney (Plate III) necessitating a unilateral nephrectomy in addition to ovariohysterectomy. The dog with TVT had a perivulvar mass (Plate IV) that extended into the vagina, while the dog with intrauterine foreign body (Plate V) had a broken portion of a swab stick migrating into the uterine body. General anaesthesia was used in all the 9 cases, but epidural anaesthesia with lignocaine injection was used in addition to the general anaesthesia in one of the 9 cases. The common drugs used included, xylazine, ketamine, diazepam and propofol. In all the nine cases, ventral midline approach was used to gain access into the abdominal cavity. Prognosis was good in 7 of the

Table 1: Records of ovariohysterectomy in dogs presented to the Veterinary Teaching Hospital, Federal University of Agriculture, Abeokuta

S/N	Breed	Indication	Method of Anaesthesia	Outcome	Post OVH complications
1	Rottweiler	Open strangulated pyometra	Epidural Lignocaine Ketamine-xylazine anaesthesia	Surgery was successful with minimal complication	Moderate obesity
2	Boerboel	Ovarian adenocarcinoma	General anaesthesia with Ketamine, xylazine and diazepam	Surgery was successful with minimal complication	Moderate obesity
3	Lhasa apso	Closed pyometra	General anaesthesia with Ketamine, xylazine and diazepam	Surgery was successful with minimal complication	Mammary adenocarcinoma two years post OVH.
4	Pug	Elective request	General anaesthesia with Ketamine, xylazine and diazepam	Surgery was successful with minimal complication	Moderate obesity
5	Samoyed	Closed pyometra	General anaesthesia with diazepam + propofol combination	Dog died due to hypovolemia	None
6	Alsatian Cross	Adjunct to chemotherapeutic management of genital transmissible venereal tumour	General anaesthesia with Ketamine, xylazine and diazepam	Surgery was successful with minimal complication	Moderate obesity
7	Rottweiler	Intrauterine foreign body	General anaesthesia with Ketamine, xylazine and diazepam	Surgery was successful with minimal complication	Moderate obesity
8	Doberman	Ovarian cystadenocarcinoma	General anaesthesia with Propofol Diazepam combination	Surgery was successful, however dog was euthanized due to worsening renal function	Vomition and weight loss
9	Samoyed	Closed pyometra	General anaesthesia with diazepam + propofol combination	Surgery was successful with minimal complication	None

dogs, while 1 dog died secondary to hypovolemia immediately after surgery and another dog was euthanized 1 week after surgery due to poor renal

function after surgery. Following surgery, 5 of the dogs had moderate obesity about 6 months later, while 1 dog had mammary adenocarcinoma (Plate

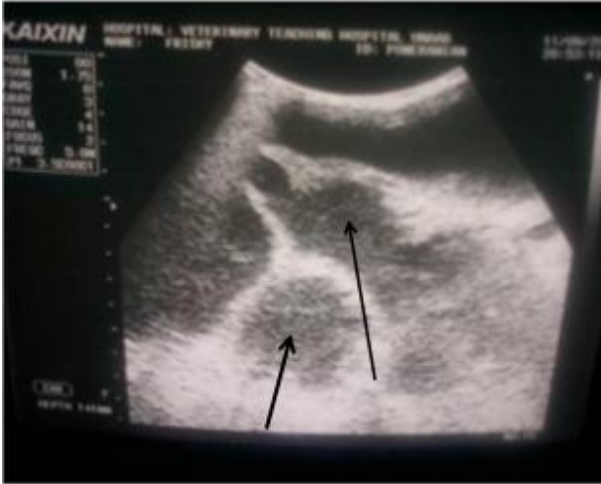

Plate I: Abdominal ultrasound image of a seven year old Samoyed with closed pyometra showing central anechoic area (arrows)

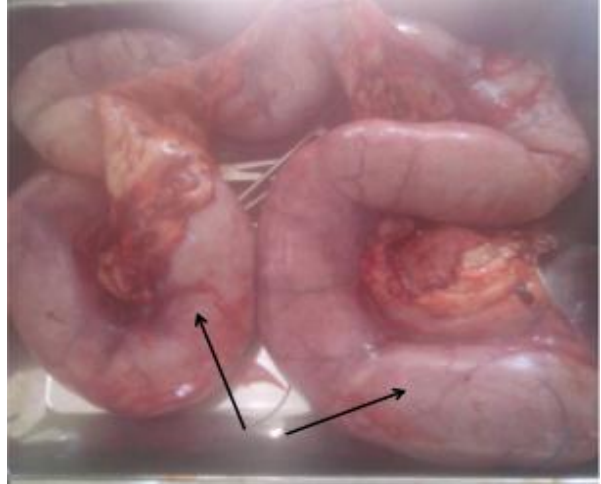

Plate II: Resected uterus from a seven year old Samoyed with closed pyometra with uterine horns distended with pus (arrows)

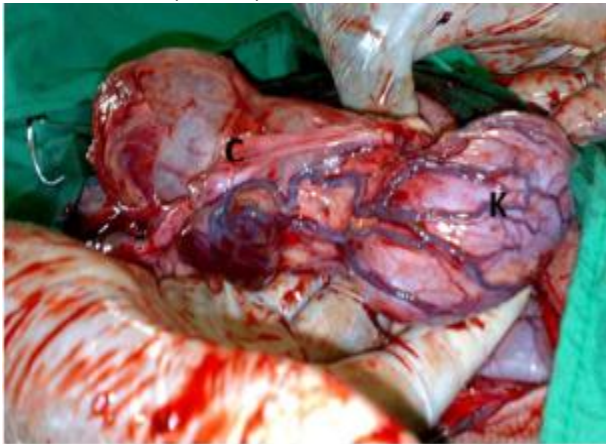


Plate III: Intraoperative picture of a two year old Doberman with ovarian cystadenocarcinoma (C) and adjacent kidney (K)

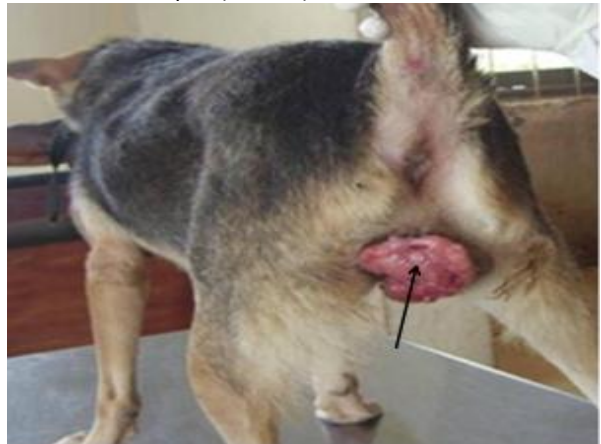

Plate IV: Four year old Alsatian cross with peri-vulva transmissible venereal tumour (Arrow)

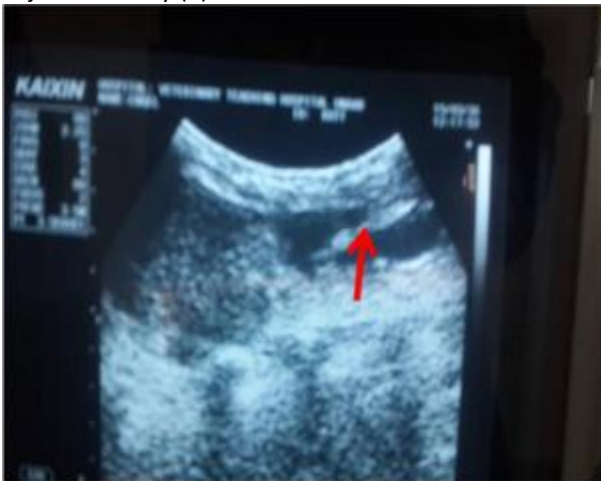

Plate V: Abdominal ultrasound of a five year old Rottweiler with intra-uterine foreign body (Arrow)

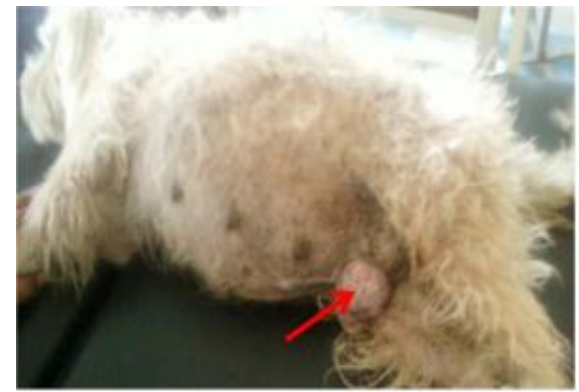

Plate VI: Twelve year old Lhasa apso with mammary adenocarcinoma two years after ovariohysterectomy was performed secondary to closed pyometra

VI) 2 years after.

Discussion

The result of this study showed that the rate of performance of ovariohysterectomy at the Veterinary Teaching Hospital, FUNAAB is very low. This may reflect the general trend about the status of ovariohysterectomy in dogs in Nigeria. This low prevalence of ovariohysterectomy in this study is contrary to the high rate of about 81% reported in the United States (Trevejo *et al.*, 2011). The low rate of ovariohysterectomy may not be unconnected to the perception of dog owners that castration in dogs is cruel (Ajadi *et al.*, 2013). It may also be due to the fact that majority of dogs are kept solely for breeding or security purposes and ovariohysterectomy is believed to have negative impact on these purposes (Amber, 2008). Other reasons for the poor rate of ovariohysterectomy in dogs in this study may be due to the perceived adverse effect and complications associated with the procedure.

One of the main aims of this study was to determine the indication for owners seeking for ovariohysterectomy in dogs. Only one of the dogs presented was ovariohysterectomized for elective reason. Others were performed as surgical treatment of reproductive disorders such as pyometra, ovarian tumours and other uterine disorder. One dog was ovariohysterectomized to prevent recurrence of transmissible venereal tumour after the completion of chemotherapy with vincristine. This finding suggests that ovariohysterectomy is primarily performed in dogs in Nigeria as a required or an emergency procedure. In addition, this study also showed that pyometra is likely a relatively common reproductive disease of dogs in Nigeria. Pyometra is a polysystemic dioestral disease of adult bitches characterized by hyperplasia of the endometrium and infiltration of inflammatory cells (Kempisty *et al.*, 2013). It is believed to be the commonest of the reproductive diseases of dogs with estimated prevalence of 25% (Kida *et al.*, 2006). The result of this study also indicated that ovarian adenocarcinoma may be relatively common in dogs in Nigeria.

All the 7 breeds of dogs presented for ovariohysterectomy were exotic breeds. The breeds of dogs presented for ovariohysterectomy were well distributed among the large and small breeds of dogs and none of the breeds was over-represented or under-represented as earlier reported (Trevejo *et al.*, 2011). Although the overall number of dogs

presented for OVH was very small only the exotic breeds of dogs were presented for OVH. This may be associated with economic capabilities of the owners of local breeds of dogs to present their dogs for routine veterinary care (Amber, 2008). The large number of stray local dogs in Nigeria and the attendant risk of spread of rabies to humans and other animals necessitate an urgent need for more awareness on the benefit of ovariohysterectomy in dogs.

Dogs presented for ovariohysterectomy has been estimated between 6 – 12 months of age in the United States (Trevejo *et al.*, 2011). This is to ensure that the dogs have been neutered before they are taken for adoption (Kustritz, 2007). The mean age of dogs presented for ovariohysterectomy in this study (5.5 ± 2.9 years; range 18 months – 10 years) is relatively higher compared to that reported in the United States. This may be connected with the fact that most of the dogs presented for ovariohysterectomy were diagnosed of uterine and/or ovarian diseases. The mean age of 5.5 ± 2.9 years (range 18 months – 10 years) of the dogs presented for ovariohysterectomy may thus reflect the age incidence of these uterine or ovarian diseases. Previous studies reported the incidence age of pyometra to be between 5 – 10 years with mean age being 5.5 years (Kempisty *et al.*, 2013), while the median incidence age of ovarian neoplasm was reported to be twelve years (Harit & Haimeri, 2016).

There are certain risks associated with ovariohysterectomy. These include development of orthopaedic conditions, cognitive decline, and a predisposition to some neoplasms (Kustritz, 2007; Belanger *et al.*, 2017). In the current study, one of the ovariohysterectomized dogs died secondary to hypovolemia, while another dog was euthanized due to poor outcome (renal failure due to metastasis of ovarian cancer into the kidneys). These findings may be more related to the primary diseases that necessitated the ovariohysterectomy rather than the procedure itself. However, majority of the dogs that had favourable outcome following surgery developed obesity. The high prevalence of obesity following ovariohysterectomy might be responsible for the increased risk of orthopaedic diseases such as anterior cruciate ligament rupture and hip dysplasia (Belanger *et al.*, 2017), however orthopaedic complications were not observed in the dogs probably because of insufficient follow up time. Ovariohysterectomy has been reported to reduce the risk of the development of canine mammary

tumours depending on the time at which the procedure is performed (Kustritz, 2007). On the contrary, a recent study indicated that ovariohysterectomy did not reduce the risk of mammary tumour development in dogs (Beauvais *et al.*, 2012). In this study, one dog developed mammary adenocarcinoma about 2 years after ovariohysterectomy. The dog was neutered at ten years of age due to development of closed pyometra. Hence, it seems OVH predisposed to the occurrence of mammary adenocarcinoma

In conclusion, this study suggests that most cases of ovariohysterectomy are performed secondary to ovarian tumours and uterine pathology such as pyometra. It also showed that the poor rate of performance of ovariohysterectomy might be related to economic factors, welfare concerns and development of complications such as obesity, mammary tumours and behavioural changes in the dogs. In the light of the benefits of ovariohysterectomy to reduce population of stray dogs and prevent against the development of certain reproductive pathologies, proper client education to inform the owners of the possible risks associated with ovariohysterectomy is recommended. In addition, the population of dogs in this study is too small and covers a small area. Therefore, we suggest a further study involving larger areas and more animals to determine the significance of our findings in this study.

References

- Ajadi TA, Oyeyemi MO & Ajadi RA (2013). Practices and concerns of castration of dogs in Nigeria. *Bulletin of Animal Health Production in Africa*, **61**(3): 453-459.
- Amber B (2008). *Pet ownership and trade – Global report (Online)*. Global Companion Animal Ownership and Trade: Project Summary. www.wspa-international.org/globalreport_tcm9-10875.pdf, retrieved 24-09-2012.
- Angioletti A, De Francesco I, Vergottini M & Battocchio ML (2004). Urinary incontinence after spaying in the bitch: incidence and oestrogen-therapy. *Veterinary Research Communication*, **28**(1): 153-155.
- Beauvais W, Cardwell JM & Brodbelt DC (2012). The effect of neutering on the risk of mammary tumours in dogs: A systematic review. *Journal of Small Animal Practice*, **53**: 314–322
- Belanger JM, Bellumori, TP, Bannasch DL, Famula RT & Oberbauer AM (2017). Correlation of neuter status and expression of heritable disorders. *Canine Genetics and Epidemiology*, doi 10.1186/s40575-017-0044-6.
- Casey RA, Loftus B, Bolster C, Richards GJ & Blackwell EJ (2014). Human directed aggression in domestic dogs (*Canis familiaris*): Occurrence in different contexts and risk factors. *Applied Animal Behaviour Science*, doi.org/10.1016/j.applanim.2013.12.003.
- Harit SP & Haimeri P (2016). Cystic ovaries and ovarian neoplasia in the female dog: A systematic review. *Reproduction in Domestic Animals*, **51**(S1): 3-11.
- Hart BL, Hart LA, Thigpen AP & Willits NH (2014). Long-term health effects of neutering dogs: Comparison of Labrador Retrievers with Golden Retrievers. *PLoS ONE*, **9**(7): e102241.
- Hoffman JM, Creevy KE & Promislow DL (2013). Reproductive capability is associated with lifespan and cause of death in companion dogs. *PLoS ONE*, **8**(4): e61082.
- Kempisty B, Bukowska D, Wozna M, Piotrowska H, Jackowska M, Zuraw A, Ciesiolka S, Antosik P, Maryniak H, Ociepa E, Porowski Sz, Brussow KP, Jaskowski JM & Nowicki M (2013). Endometritis and pyometra in bitches: A review. *Veterinarni Medicina*, **58**(6): 289–297.
- Kida K, Baba E, Torii R, Kawate N, Hatoya S, Wijewardana V, Sugiura K, Sawada T, Tamada H & Inaba T (2006). Lactoferrin expression in the canine uterus during the estrous cycle and with pyometra. *Theriogenology*, **66**(5): 1325-1333.
- Kim BS, Kim HS, Kim KC, Park CH, Oh KS & Son CH (2008). Vaginal prolapse by ovarian follicular cysts in a female Jin-do dog. *Korean Journal of Veterinary Research* **48**(2): 223-225.
- Kristiansen VM, Nodtvedt A, Breen AM, Langeland M, Teige J, Goldschmidt M, Jonasdottir TJ, Grotmol T & Sørenmo K (2013). Effect of ovariohysterectomy at the time of tumor removal in dogs with benign mammary tumors and hyperplastic lesions: A randomized controlled clinical trial. *Journal Veterinary Intern Medicine*, **27**(4): 935-942.

- Kustritz MV (2007). Determining the optimal age for gonadectomy of dogs and cats. *Journal of*
- Lund EM, Armstrong PJ, Kirk CA & Klausner JS (2006). Prevalence and Risk factors for Obesity in Adult Dogs from Private US Veterinary Practices. *International Journal of Applied Research in Veterinary Medicine*, **4**(2): 177-186.
- McKenzie B (2010). Evaluating the benefits and risks of neutering dogs and cats. *Perspectives in American Veterinary Medical Association*, **23**(11): 1665-1675.
- Agriculture, Veterinary Science, Nutrition and Natural Resources*, **5**(45): 1-17.
- Trevejo R, Yang M & Lund EM (2011). Epidemiology of surgical castration of dogs and cats in the United States. *Journal of the American Veterinary Medical Association*, **238**(7): 898–904.