



Morphogenesis of the midbrain of grey breasted helmeted guinea fowl at pre-hatch

N Wanmi^{1*}, JO Nzalok² & MO Samuel¹

^{1.} Department of Veterinary Anatomy, College of Veterinary Medicine, University of Agriculture, Makurdi, Benue State, Nigeria

^{2.} Department of Veterinary Anatomy, Faculty of Veterinary Medicine, Ahmadu Bello University, Zaria, Kaduna State, Nigeria

*Correspondence: Tel.: +2348034696906; E-mail: nathanielwanmi2014@gmail.com

Copyright: © 2018 Wanmi *et al.* This is an open-access article published under the terms of the Creative Commons Attribution License which permits unrestricted use, distribution, and reproduction in any medium, provided the original author and source are credited.

Publication History:
Received: 24-06-2017
Accepted: 24-10-2017

Abstract

This study was carried out to investigate the development of the midbrain in the grey breasted helmeted guinea fowl. Domestication of grey helmeted guinea fowl is increase but scanty documentation on the development of midbrain (mesencephalon) and how it relates to the neurobiology of this bird is lacking. A total of sixty six (66) fertilized guinea fowl eggs were purchased from National Veterinary Research Institute (NVRI) Vom, Jos, Plateau state, Nigeria and used for this study. Grossly, in the wild grey breasted helmeted guinea fowl, the optic lobe develops following development of midbrain and the midbrain appeared first on day 10 of incubation flank by the optic lobes on each sides. There was steady increase in the weights of the midbrain up to day 28 of incubation. This was expressed graphically at pre-hatch period which went up at day 17 and dropped at day 20 of incubation. Significant increases ($P \leq 0.0001$) of the midbrain were seen on days 23 and 26. This indicates that as body and brain weights were increasing, there was a concurrent increase in midbrain weight. Morphologically, the midbrain was fully developed at pre-hatch period. This indicates that contribution from optic lobe to auditory-visual systems is fully developed in the wild grey breasted helmeted guinea fowl immediately after hatching and is capable of surviving independently.

Keywords: Grey, Helmeted, Midbrain, Morphogenesis, Pre-hatch

Introduction

The helmeted guinea fowl (*Numida meleagris galeata*) is a native to Africa and belongs to the Phylum, *Chordata*; Subphylum *Vertebra*; Class *Aves*; Order *Galliformes* and Family, *Numidae* (Baruwa & Sofoluwe, 2016). It is widely distributed in the Guinea Savannah zone of Nigeria and estimated at 44 million in captivity (Ayeni *et al.*, 1983).

Developmentally, in avians, the central nervous system develops from the neural plate, an epithelial sheet that arises from the dorsal ectoderm of the developing embryo (Hallonet *et al.*, 1990). After neural tube closure, series of vesicles that can be clearly distinguished morphologically at the anterior

end indicate an anterior-posterior axis development (Joyner, 2002). The mesencephalon (midbrain) comprises of the optic lobes, which are the visual roof, often-named optic tectum, in mammalian species and superior colliculus in man (Northcutt, 2002). Audition is of critical importance to a wide range of behaviour in birds, such as prey capture, individual and species recognition, vocal learning and mate selection. As a result of the range of behaviour that rely upon acoustic cues, studies of avian audition have revealed marked specie differences in hearing range and the ability to localize sounds and discriminate pitch, intensity and

temporal differences (Agawala *et al.*, 2001). From this and other evidences, it is clear that several groups have evolved unique auditory specializations: localization of prey using only acoustic cues, vocal learning and echolocation in birds. Given that birds share many behavioural and neural similarities (Mogensen & Divac, 1993) with mammals, it is certain that such correlations also exist in bird midbrain.

Study on the development of the avian brain includes histomorphogenesis of the cerebellum of the grey breasted helmeted guinea fowl (Wanmi *et al.*, 2016), glial cells in the CNS of healthy Passeriformes birds (Yokota *et al.*, 2008) and the development of chicken cerebellar cortex (Serdar & Emrah, 2010). Despite these studies, there exists dearth of information on the histomorphogenesis of the midbrain of grey breasted helmeted guinea fowl in Nigeria.

This investigation attempts to find the variations in the developmental anatomy of the midbrain in the grey breasted helmeted guinea fowl with regards to their gross developmental structure and histogenesis, which may be helpful in understanding the neurobiology of this specie of bird.

Materials and Methods

Experimental design

A total of 66 fertilized guinea fowl eggs were purchased from National Veterinary Research Institute (NVRI) Vom, Jos, Plateau State, Nigeria. The eggs were transported to a private hatchery owned by Bitrus and Sons, Turu Vom, still in Jos and incubated using their incubation guide. During incubation, the eggs were turned regularly (minimum of three times) each day for the first 24 days according to method modified by Moreki *et al.* (2012).

Sixty one eggs (seven eggs per day) for pre-hatch study were collected from days 5, 8, 11, 14, 17, 20, 23, 26 and 28 which was the last day for pre-hatch collection. A small opening was made on the large air space area and the entire egg dropped into a labeled container of 10 percent buffered formalin for proper fixing (Gosomji, 2014).

Extraction of embryo/foetus

This was done at pre-hatch using a scalpel blade and clean transparent dish. The blunt side of the scalpel blade was used with the egg held on the palm, and a gentle tap made on the egg until a crack was formed. Then, the crack was gently widened manually and

the embryo collected in a white dish, the procedure as modified by Salami (2009).

Extraction of brain

At pre-hatch, because the entire skull was soft and pliable, scalpel blade and rat tooth forceps were used for extraction of the brain. At post-hatch, the keets were euthanized using Nembutal at 40 mg/body weight. Thereafter, decapitation was made and the heads fixed in 10 % neutral buffered formalin for 3 – 5 days. After proper fixation, a dissection was made at the angle of the beak up to the level of the occipital bone. The upper portion of the dissected area was pulled off gradually using the rat tooth forceps until the entire brain was exposed. The cranial nerves were severed to ease the lifting of the brain from the cranium. Extracted brain samples were fixed for three days in Bouin's solution for routine staining.

Separation of the midbrain

The cerebellum was located on the dorsal portion of the brain stem with three peduncles: the restiform body connected to the medulla, the brachium pontis that connects cerebellum to the pons and the brachium conjunctivum that connects cerebellum to the midbrain. These peduncles were severed using a scalpel blade to expose the entire brainstem.

The midbrain or mesencephalon was located just caudal to the level of chiasma opticum rostrally and at the level of ponto-mesencephalic region caudally. After the midbrain removal, the anterior portions left are the diencephalon and the cerebrum. At the boundary between the diencephalon and cerebrum, an incision was made revealing the cerebral hemispheres held together by the corpus callosum. Each hemisphere was freed by a longitudinal incision. These landmarks were cut across using the scalpel blade to extract the midbrain.

Gross anatomy and morphometry

Sixty one midbrain samples were used for morphometry and five midbrain samples were used for morphology. The weights of the midbrain were taken using digital electronic balance; (Model JJ1000, Max. 1000g, d=0.01g, e=10d, No. 211011011098, Made in China) and Analytical Weighing balance, (Adventure QHAUS Corporation, Item No. AR3130, Max. Capacity= 310g Readability= 0.001g). Photographs of the dorsal and ventral aspects were taken using cannon digital camera (4x optical zoom lens 5.0 - 20.0 mm, 15.1 mega pixels Apple, Cannon) and Digital Handheld

Table 1: Weights of the helmeted guinea fowl midbrain embryo at days 5 - 28 of incubation (in gram) (n=7)

Days	Minimum	Maximum	Mean ± SD
5	0.0001	0.0007	0.0004 ± 0.0003*
8	0.0001	0.0040	0.0011 ± 0.0008*
11	0.0003	0.0041	0.0015 ± 0.0012*
14	0.0007	0.0020	0.0019 ± 0.0005*
17	0.0013	0.0114	0.0032 ± 0.0017*
20	0.0010	0.0021	0.0016 ± 0.0005*
23	0.0012	0.0110	0.0035 ± 0.0034**
26	0.0014	0.0117	0.0052 ± 0.0041**
28	0.0020	0.0145	0.0081 ± 0.0054*

**; Significant, n; *, Not significant, Number of birds used per day, SD; Standard Deviation

Microscope (Magnification 1000x, 5x Zoom).

Data analysis

Morphometric data on the midbrain was analyzed using Statistical Package for Social Science (SPSS) version 17.0. In the analysis, the descriptive statistics was expressed as Mean ± SD. Result was subjected to student t-test and p value of the difference in weights between one incubation day and another. P≤ 0.0001 was considered significant.

Results and Discussion

Pre-hatch morphometry: The mean weight of the midbrain of the helmeted guinea fowl on day 5 of incubation was 0.0004 ± 0.0003 g. On day 20, there was a drop in the mean weight of the midbrain to 0.0016 ± 0.0005 g which later went up to 0.0035 ± 0.0034 g on day 23 of incubation which was significant (Table 1). The line graph indicated that on days 17 and 23, there was decrease in the mean weight of the midbrain during pre-hatch period (Figure 1).

In the helmeted guinea fowl, two types of yolk were observed which were the milk and yellow colour yolks (Plate I). On day 2 of incubation, areas of blood clot appeared on the side of the yolk where future embryo will be formed (Plate II). The point where there was formation of blood clot later tends to encircle indicating initiation of embryo formation has begun and at this point blood vessels were not seen on day 3 (Plate III). On day 4 of incubation, the

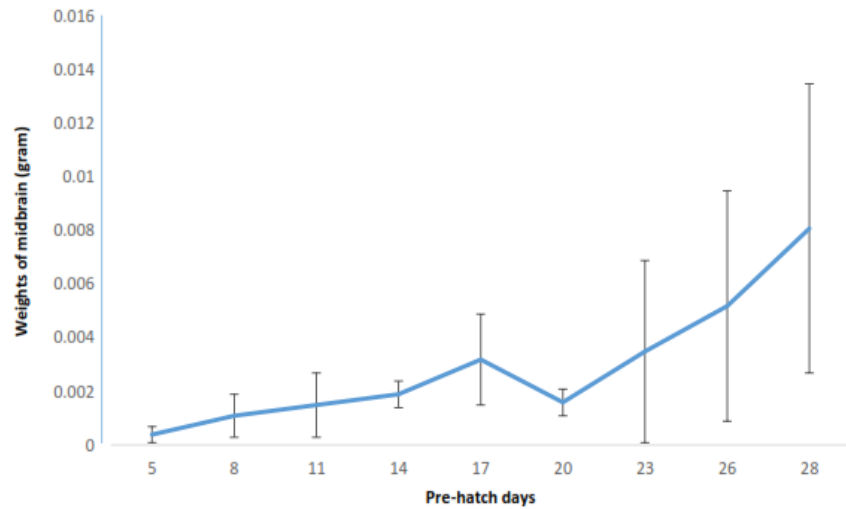


Figure 1: Weight of the midbrain helmeted guinea fowl embryo during days 5-28 pre- hatch period in gram

embryo of the helmeted guinea fowl appeared as J-shaped or figure of inverted nine (9) on the surface of the yolk with blood vessels being visible. The exteriorized embryo was observed to have an oval rostral projection as the brain and a black spot as the optic placode (head region) and a caudal tail (Plate IV). On day 5, blood vessels were elaborate and the developing embryo at this point turned and was seen as a round object, still on the surface of the yolk. It was observed that the cerebrum including the longitudinal fissure, components of brain stem and spinal cord has been formed (Plate V). The midbrain was first seen on the day 10 of incubation (Plate VII). Thereafter, there was relatively no pronounced gross change observed until on day 21 when the midbrain was fully formed (Plate VIII).




Plate I: Two forms of egg yolk, A; Milk colour egg yolk, B; Yellow colour egg yolk, day 1 of incubation, X12.1

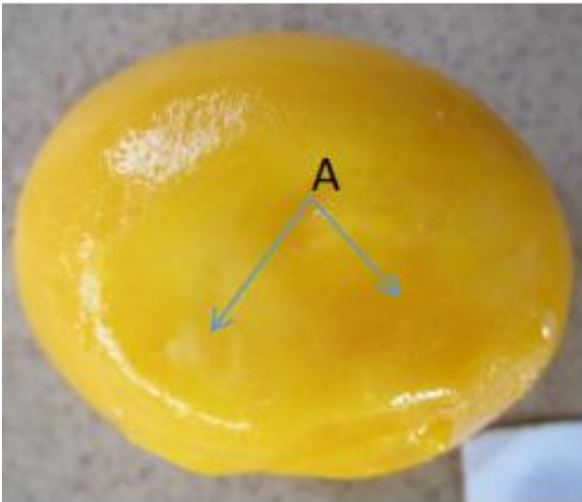


Plate II: Egg yolk of helmeted guinea fowl indicating, A; Areas of blood clott on the surface egg Yolk, day 2 of incubation, X12.1

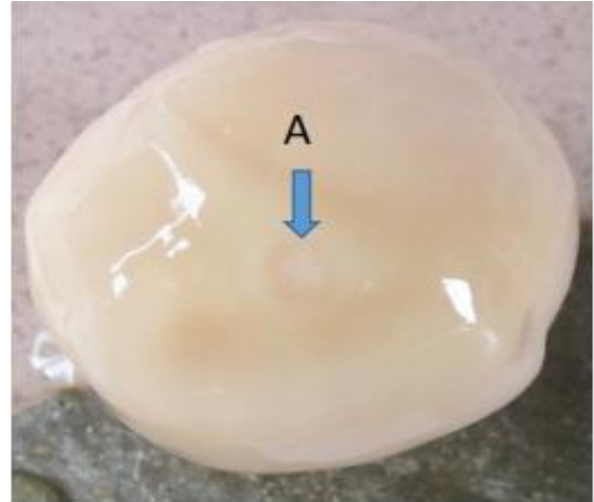


Plate III: Yolk of helmeted guinea fowl indicating, A; An encircled Point of future embryo development, day 3 of incubation, X12.1

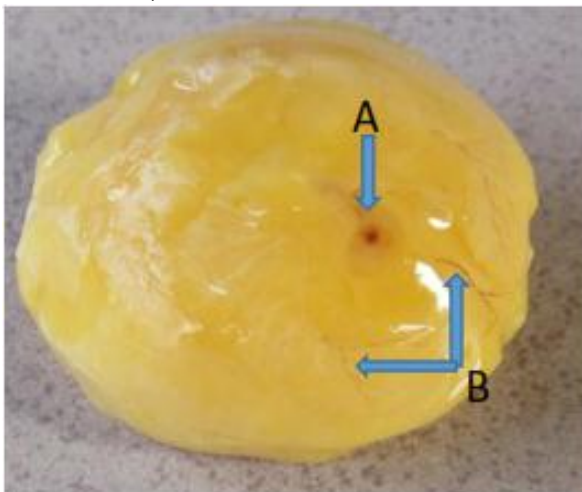
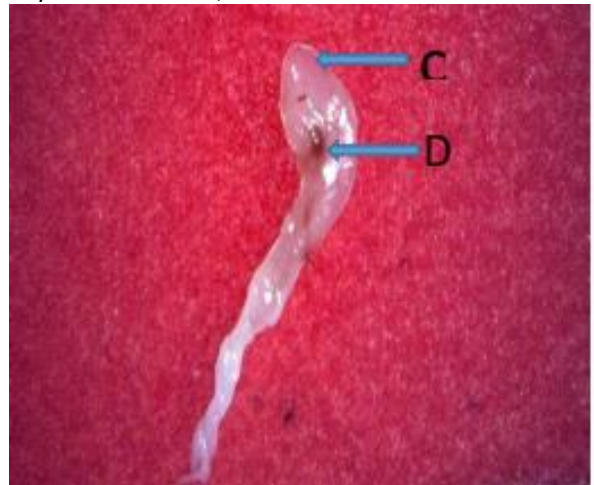

Plate IV: Development of the embryo of the helmeted guinea fowl showing, A; J-shaped embryo, B; blood vessels, C; The brain, D; The eye, day 4 of incubation, X12.1



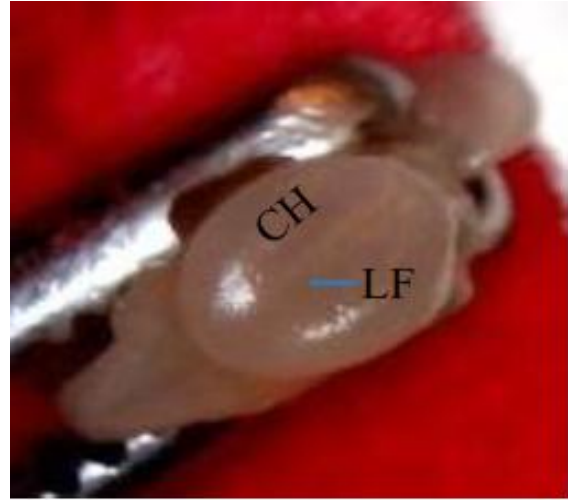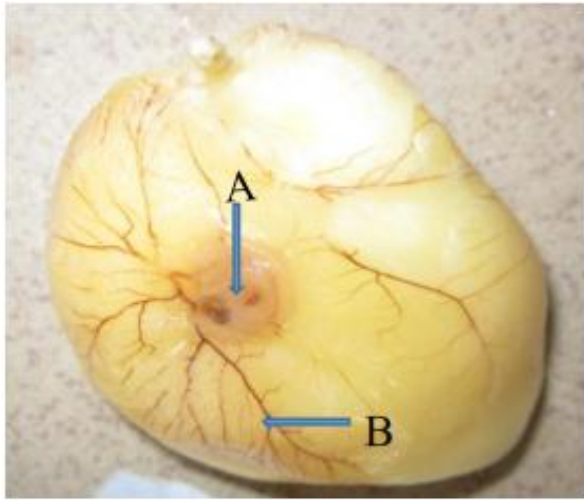


Plate V: Developing embryo of the helmeted guinea fowl showing A; an oval shaped embryo, B; Blood vessels, CH; Cerebral hemisphere, LF; Longitudinal fissures, day 5 of incubation, X12.1

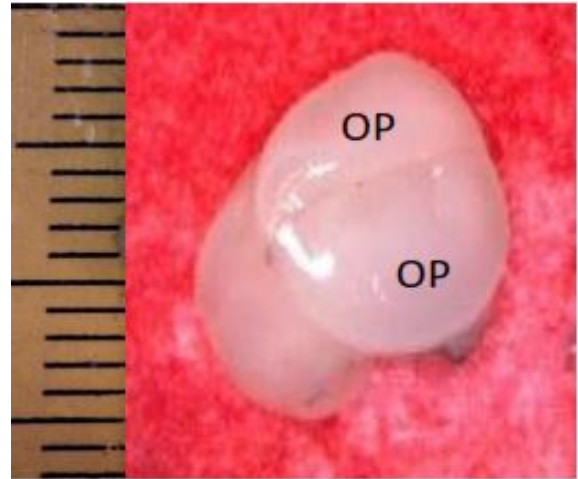
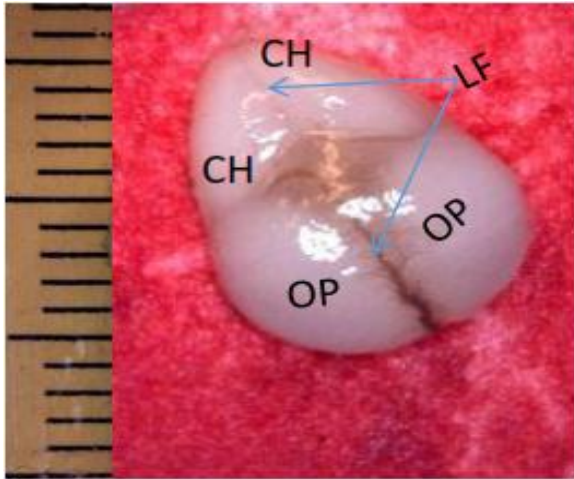


Plate VI: Dorsal and lateral view of the brain of the embryo of the helmeted guinea fowl, CH; Cerebral hemisphere, OP; Optic lobe, LF; Longitudinal fissure, day 8 of incubation, X500

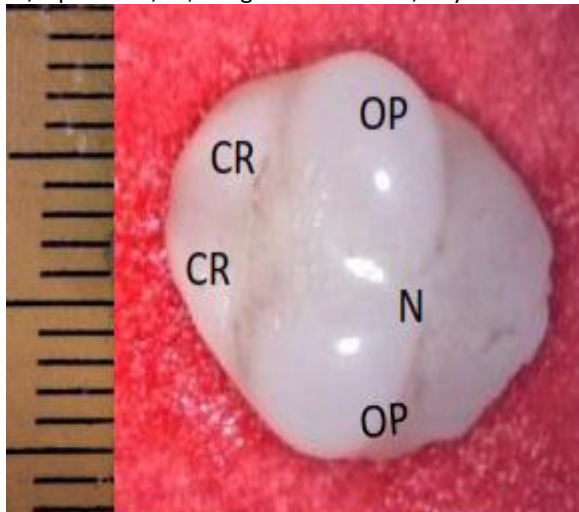


Plate VII: Dorsal and ventral view of the developing brain of helmeted guinea fowl, CR; Cerebral hemisphere, OP; Optic lobe, N; Notch, MB; Midbrain, MO; Medulla oblongata, Day 10 of incubation period, X500

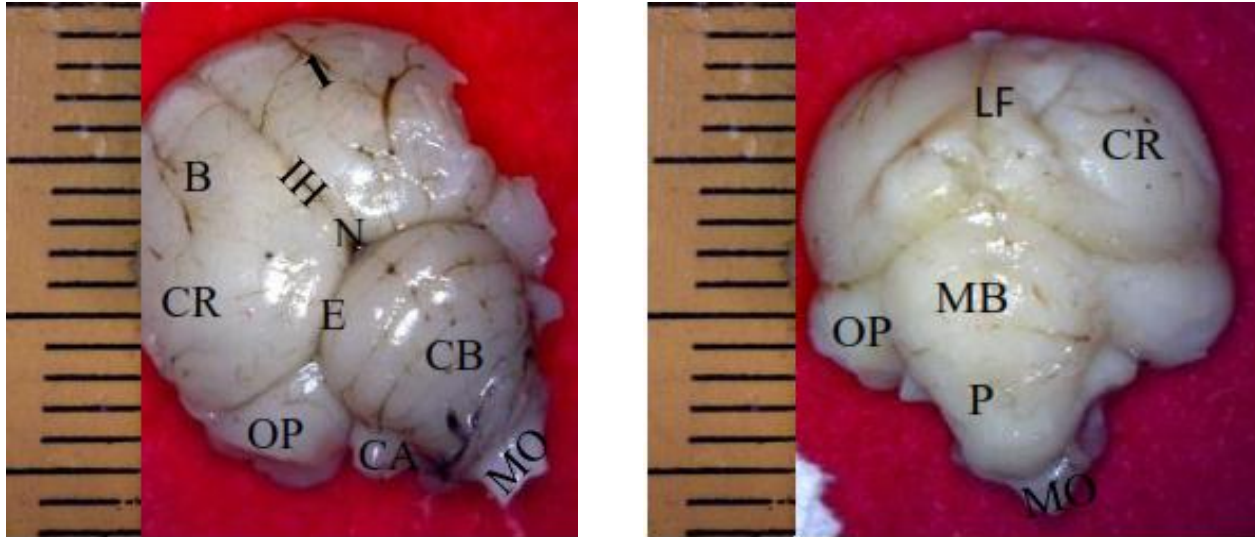


Plate VIII: Brain of helmeted guinea fowl at point of hatch, B; Wulst, CR; Cerebrum, LF; Longitudinal, IH; Interhemispheric fissure, fissure, N; Notch, E; Transverse fissures, OP; Optic lobe, CB; Cerebellum, CA; Cerebellar auricle, MO; medulla oblongata, MB; Midbrain, P; Pons 1; Valleculla, day 21 of incubation, X500

In this present study, there was a steady increase in the midbrain weight but was not constant. This is in agreement with the findings of Portmann & Stingelin (1961); that brain weight always increases less than that of the body weight; and that galliformes had the lowest values, which were not constant and could thus differ in the birds of the same body weight. The helmeted guinea fowl had two types of egg yolks, the yellow coloured and milk coloured. The egg yolk plays a significant role during pre-hatch development of the embryo by primarily providing it with the necessary nutrients required for its development (Naber & Squires, 1993). At day 2 of incubation, blood clot was first noticed, and by the fifth day, blood vessels were prominent. In the helmeted guinea fowl, one of the first organ systems to develop is the vascular system with blood vessels being visible on day 4 of incubation. Blood islands were seen soon after day 1 of incubation and the circulation was established on day 2 of incubation in the chicken (Bellairs & Osmond, 2005). This supports the fact that vascular system is the first to be formed during embryogenesis of the galliformes. The embryo of the helmeted guinea fowl appeared first on the fourth day of incubation with a rostral projection of the brain and an eye-spot referred to as lens placode, and a caudal tail with a stripped middle part as the body. This developmental order was reported in the chicken (Eyal-Giladi & Kochav, 1975). Gosomji (2014) reported that the gastrointestinal tract (GIT) first develop on the 8th day of incubation and an osteogenic development in grey breasted guinea fowl on day 10 of incubation

(Salami, 2009). This indicated that during avian embryogenesis, the circulatory system is the first organ to appear and subsequently, the nervous system (midbrain) developed alongside with it in the Galliformes.

In conclusion, development of the midbrain in birds is unique as it relates to its auditory-visual functions in live birds. Therefore, formation of the midbrain at day 10 pre-hatch in the grey breasted helmeted guinea fowl may be used as a baseline information for comparative study in other species of bird

Acknowledgement

All technical staff of NVRI Vom, Plateau state and those of Department of Veterinary Anatomy, Ahmadu Bello University, Zaria, Kaduna state, Nigeria.

References

- Agawala S, Sanders TA & Ragsdale CW (2001). Sonic hedgehog control of size and shape in midbrain pattern formation. *Science*, **291**: 2147-2150.
- Ayeni JSO, Olowo-Okorun MO & Aire TA (1983). The biology and utilization of helmeted guinea-fowl (*Numida meleagris galeata*, Pallas) in Nigeria. III. Gizzard weights and contents. *African Journal of Ecology*, **21**(1): 11–18.
- Baruwa OI & Sofoluwe NA (2016). Profitability and resource use efficiency of guinea fowl (*Numida meleagris*) production under tropical conditions. *Journal of Livestock Science*, **7**: 97 – 106.

- Belliars R & Osmond M (2005). *The Atlas of Chick Development*. Second edition, Elsevier Academic Press, Oxford. Pp 159-169.
- Eyal-Giladi H & Kochav S (1975). From cleavage to premature streak formation, a complementary normal table and a new look of the first stage of the development of the chick. I. General morphology. *Developmental Biology*, **49** (2): 321-337.
- Gosomji I (2014). Morphogenesis of the Gastrointestinal Tract of the Helmeted Guinea Fowl (*Numida meleagris galeata*). MSc thesis. Department of Veterinary Anatomy, Faculty of Veterinary Medicine, Ahmadu Bello University, Zaria. Pp 63-71.
- Hallonet ME, Douarin ML & Teillet MA (1990). A new approach to development of the cerebellum provided by the quail-chick marker system. *Development*, **108**(1): 19-31.
- Joyner AL (2002). Establishment of Anterior-Posterior and Dorsal-Ventral Pattern in the Early Central Nervous System. In: *Mouse Development* (J Rossant, PPL Tam, editors), Academic Press, San Diego. Pp 107-126.
- Mogensen J & Divac I (1993). Behavioural effects of ablation of the pigeon-equivalent of the mammalian prefrontal cortex. *Behaviour Brain Reserve*, **55**(1): 101-107.
- Moreki JC, Nobo G & Nsoso SJ (2012). Feed intake, body weight, average daily gain, feed conversion, ratio and carcass characteristic of helmeted guinea fowl fed varying levels of phane meal (*Imbrasia belina*) as replacement of fishmeal under intensive system. *International Journal of Poultry Science*, **11**(6): 278 - 284.
- Naber FC & Squires MW (1993). Early detection of the presence of a vitamin premix in layer diets by egg albumen riboflavin analysis. *Poultry Science*, **72**(10): 1989-1993.
- Northcutt RG (2002). Understanding vertebrates brain evolution. *Integrative and Comparative Biology*, **42** (4): 743-756.
- Pettingil OS (1985). *Ornithology in Laboratory Field*, fourth edition. Cornell University Ithace, New York. Pp 94-96.
- Portmann A & Stingelin W (1961). The Central Nervous System. In: *The Biology and Comparative Physiology of Birds*, (AJ Marshall, editor). Academic Press, New York. Pp 37-48.
- Salami SO (2009). Studies on the Onset of Osteogenesis in Grey Breasted Guinea Fowl (*Numida meleagris galeata*). PhD thesis. Ahmadu Bello University, Zaria, Nigeria.
- Serdar A & Emrah S (2010). The development of chicken cerebellar cortex and the determination of AgNOR activity of the Purkinje cell nuclei. *Belgian Journal of Zoology*, **140**(2): 216-224.
- Wanmi N, Onyeanusu BI, Nzalak JO & Aluwong T (2016). Histomorphogenesis of the cerebellum of the grey breasted helmeted guinea fowl (*Numida meleagris galeata*) at pre-hatch and post-hatch study. *Animal Molecular Breeding*, **6**(4): 1-10.
- Yokota O, Tsuchiya K, Hayashi M, Kakita A, Ohwada K, Ishizu H, Takahashi H & Akiyama H (2008). Glial clusters and perineuronal glial satellitosis in the basal ganglia of neurofibromatosis type 1. *Acta Neuropathologica*, **116**(1): 57-66.