



## A nine - year retrospective study of avian neoplastic diseases in Zaria, Kaduna state, Nigeria

NA Sani<sup>1\*</sup>, HB Aliyu<sup>2</sup>, IW Musa<sup>3</sup>, AM Wakawa<sup>3</sup>, SE Abalaka<sup>1</sup>, SB Oladele<sup>4</sup>, L Sa'idu<sup>2</sup>  
& PA Abdu<sup>3</sup>

<sup>1.</sup> Department of Veterinary Pathology, University of Abuja, Abuja, Nigeria

<sup>2.</sup> Veterinary Teaching Hospital, Ahmadu Bello University, Zaria, Kaduna state, Nigeria

<sup>3.</sup> Department of Veterinary Medicine, Ahmadu Bello University, Zaria, Kaduna state, Nigeria

<sup>4.</sup> Department of Veterinary Pathology, Ahmadu Bello University, Zaria, Kaduna state, Nigeria

\*Correspondence: Tel.: +23480 32176723; E-mail: saninuhuabdul@yahoo.com

### Abstract

Avian neoplastic diseases have been identified as one of the leading causes of mortality and production losses in commercial chickens in Nigeria. Although available reports described the trend of Marek's disease in Zaria, Kaduna state, they did not take cognizance of other neoplastic diseases of poultry hence the need for this study. The clinic records of the Avian Clinic of the Veterinary Teaching Hospital (VTH), Ahmadu Bello University (ABU), Zaria, were examined for cases of all avian neoplastic diseases from 2002 to 2010. The overall prevalence of avian neoplastic diseases was 7.58% (234/3085). Marek's disease (MD) and avian leukosis (AL) were the only avian neoplastic diseases of poultry reported during the period under review. Marek's disease contributed 85.90% (201/234) of the total avian neoplastic diseases outbreaks while AL was responsible for only 14.10% (33/234) of the outbreaks. The overall prevalence of MD was 6.25% (201/3085) while that of AL was 1.07% (33/3085). Chicken (99.57%) and duck (0.43%) were the only species of birds affected by the diseases. The types of chickens that were affected include commercial layers (97.85%), exotic broilers (0.86%), exotic cockerels (0.86%) and Nigerian indigenous chicken (0.43%). The average age of poultry affected was 20.17 (SD=±2.6) weeks for MD and 41.43 (SD=±15.4) weeks for AL. Weight loss (55.98%), ruffled feathers (47.01%), diarrhea (39.79%) and leg paralysis (17.52%) were the most reported clinical signs. The most consistent gross lesions observed were hepatomegaly (76.50%), emaciated carcass (75.64%), renomegaly (52.56%) and splenomegaly (44.87%). Neoplastic growths were mostly observed on the liver (46.58%), kidney (28.2%) and heart (25.21%). The sciatic nerve (20.51%) and bursa of Fabricius (3.85%) were also affected. There is a remarkable increase in the cases of avian neoplastic diseases over the study period which underscores the importance of a National control program for these important diseases of poultry.

**Keywords:** Avian neoplastic diseases, Avian leukosis, Clinico-pathological changes, Marek's disease, Prevalence

Received: 22-10- 2016

Accepted: 03-01-2017

### Introduction

Avian neoplastic diseases have been identified as one of the leading causes of mortality and production problems in commercial poultry in Nigeria (Sani *et al.*, 2012; Ukashatu *et al.*, 2012; Musa *et al.*, 2013; Kumbish *et al.*, 2015). The avian neoplastic diseases of economic importance are Marek's disease (MD), avian leukosis (AL) and

reticuloendotheliosis (RE) (Payne & Venugopal, 2000).

Marek's disease is a disease of chickens caused by a herpesvirus (Schat & Nair, 2008), which is shed from the feather follicles of infected birds (Baigent & Davison, 2004). Avian leukosis is caused by avian leukosis viruses (ALVs) classified into five subgroups (A, B, C, D and J) based on their host range, viral

envelope interference, and cross-neutralization patterns (Payne & Fadly, 2003). Avian leukosis virus subgroups A and B are more commonly associated with lymphoid leukosis and less commonly erythroid leukosis, while ALV subgroup J is mainly associated with myeloid leukosis (Payne & Fadly, 2003). In most cases, the clinical signs and pathological findings of avian neoplastic diseases are similar and therefore, it is difficult to differentiate them clinically (Davidson, 2004).

Although some work have been done to evaluate the level of occurrence of MD in the study area (Wakawa *et al.*, 2012; Jwander *et al.*, 2013; Musa *et al.*, 2013), to date there seems to be no report on the prevalence of AL in Zaria, Nigeria. However, Fatunmbi & Adene (1986) and Olabode *et al.* (2009) carried out retrospective studies on MD and AL in Ibadan and Ilorin, respectively.

This study examined the trend of the cases of avian neoplastic diseases diagnosed at the Avian Clinic, Veterinary Teaching Hospital (VTH), Ahmadu Bello University (ABU), Zaria, Nigeria, from 2002 to 2010.

**Materials and Methods**

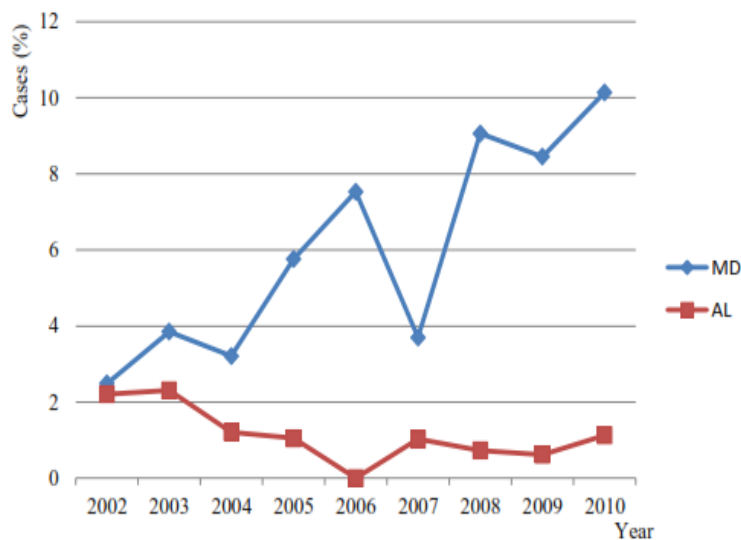
The data used for this study was obtained from the clinic records of the Avian Clinic, VTH, ABU, Zaria, Nigeria. The records examined were from 2002 to 2010. The number of avian neoplastic disease cases recorded, as well as the total number of cases recorded for all other avian diseases over the study period were considered. A case was considered as any report to the VTH, ABU, Zaria, which was diagnosed as avian neoplastic disease. Diagnoses of avian neoplastic diseases were majorly by history of

the case, clinical signs observed by the clinician and by post-mortem examination of carcasses of affected birds. Other information, such as age of birds, types of bird, clinical signs, gross lesions, concurrent diagnoses and differential diagnoses of avian neoplastic diseases were also considered. The avian species submitted at the Avian Clinic for examination included chicken, duck, guinea fowl, ostrich, turkey and quail.

The prevalence of avian neoplastic diseases from 2002 to 2010 was determined in percentages using Microsoft Office Excel<sup>®</sup> whereas the ages of birds affected by avian neoplastic diseases were summarized into means, and the means were compared for statistical significance ( $p < 0.05$ ) using SPSS<sup>®</sup> version 17.

**Results**

A total of 3,085 cases of various poultry diseases were diagnosed during the period of the study. Results of this study showed an overall prevalence of avian neoplastic diseases to be 7.59% (234/3085), with the lowest prevalence of these diseases recorded in 2004 (4.42%) while the highest prevalence was in 2010 (11.26%) (Figure 1). Marek’s disease and AL were the only neoplastic diseases of poultry recorded, and contributed 85.90% (201/234) and 14.10% (33/234) respectively, over the study period. A prevalence of 6.52% (201/3085) was recorded for MD while a prevalence of 1.07% (33/3085) was recorded for AL during the study period. The result of this study showed that chicken and duck were the only species of birds affected by



**Figure 1:** The prevalence of Marek’s disease and avian leukosis diagnosed at the Avian Clinic, VTH, ABU, Zaria from 2002 - 2010

avain neoplastic diseases. The types of chicken affected by these diseases included commercial layer (97.85%), exotic broiler (0.86%), exotic cockerel (0.86%), and Nigerian local chicken (0.43%).

The results of this study showed that the average age at which MD affected chickens was 20.17 (SD= ±2.6) weeks, while the average age at which AL affected chickens was 41.43 (SD= ±15.4) weeks (Table 1). The age of the duck that was affected by avian neoplastic disease could not be ascertained.

The clinical signs in chickens affected by avian neoplastic disease included weight loss (55.98%), ruffled feathers

**Table 1:** The average ages in which Marek's disease and avian leukosis were diagnosed at the Avian Clinic, VTH, ABU, Zaria from 2002 – 2010

Year	Average age in weeks at which Marek's disease was diagnosed	Average age in weeks at which avian leukosis was diagnosed
2002	23.13	48.67
2003	17.2	42
2004	23.67	35.33
2005	19.55	72
2006	18	0
2007	18.13	42.8
2008	18.82	22.67
2009	23.49	43
2010	19.58	25

(47.01%), diarrhea (39.79%), somnolence (34.19%), paralysis of the legs (17.52%) and wings (4.27%), torticollis (12.39%) and stunted growth (15.81%). Other signs recorded included soft shelled eggs (1.3%), whitish eggs (0.86%) and drop in egg production (0.86%). The respiratory signs recorded were dyspnea (5.98%), coughing (4.27%) and sneezing (3.42%). The clinical signs in the duck included weight loss, diarrhea, ruffled feathers and sneezing.

The post-mortem lesions recorded in chickens with avian neoplastic diseases during the period under review included enlarged liver (76.50%), emaciated carcass (75.64%), congested liver (52.56%) and enlarged kidneys (52.56%). Neoplastic nodular lesions were observed on the liver (46.58%), kidney (28.2%), heart (25.21%), proventriculus (24.36%), lungs (19.66%), spleen (17.09%), intestine (14.10%), thoracic cage (3.42%) and pancreas (0.86%). Other lesions recorded include splenomegaly (44.87%), raised proventricular glands (41.45%), haemorrhagic proventricular mucosa (22.22%), enlarged sciatic nerve (20.51%), regressed follicles (14.96%) and enlarged bursa of Fabricius (3.85%). The post-mortem lesions in the duck were emaciated carcass, enlarged liver with neoplastic multifocal nodular lesions.

The diseases diagnosed concurrently with MD included Newcastle disease (24.88%), fowl typhoid (3.48%), coccidiosis (2%), aspergillosis (1.49%), fowl pox (1%), colibacillosis (0.5%), pullorum disease (0.5%), and chronic respiratory disease (0.5%) as shown in Table 2. Avian leukosis (31.34%), Newcastle disease (24.88%), fowl typhoid (6.97%), aspergillosis (6.47%), coligranuloma (6.47%) and tuberculosis (3.48%) were listed as differential diagnoses of MD. Concurrent diseases recorded for AL included Newcastle disease (24.24%), lousiness (6.06%), fowl

typhoid (3.03%) and helminthosis (3.03%), while those diseases listed as differential diagnoses for AL included MD (39.39%), Newcastle disease (12.12%), fowl typhoid (6.06%) and colibacillosis (3.03%) as shown in Table 3.

### Discussion

Reports in Nigeria have placed avian neoplastic diseases among the leading diseases causing devastating economic losses to the poultry industry (Sani *et al.*, 2012; Wakawa *et al.*, 2012; Jwander *et al.*, 2013; Musa *et al.*, 2013; Kumbish *et al.*, 2015; Okonkwo, 2015). This study was carried out to evaluate the outbreaks of avian neoplastic diseases diagnosed at the Avian Clinic, VTH, ABU from 2002-2010. The prevalence of these economically important avian diseases increased from 2002 to 2010. More than 97% of the outbreaks in chickens occurred in commercial layers. This is likely because commercial chicken owners invest a lot of resources in their farms and would therefore be more likely to report any abnormality to the clinic. The commercial chickens are also more likely to be purchased from the same source so that the chickens could be infected right from the hatchery. Only one outbreak of MD was reported in duck and another outbreak in Nigerian local chicken. The local chickens in Nigeria are known to be hardy and therefore resistant to many infectious diseases (Sani *et al.*, 2011). The low prevalence of avian neoplastic diseases in Nigerian local chicken may also be attributed to poor disease reporting as most of the owners of this type of chickens have little knowledge concerning disease reporting or no access to medical services. The rural dwellers are usually poor and may not be able to afford veterinary services even when available, and often keep very small numbers of chickens.

**Table 2:** Avian diseases associated with Marek's disease based on clinic records at the Avian Clinic, VTH, ABU, Zaria from 2002 - 2010

Avian diseases associated with Marek's disease	Frequency of avian diseases diagnosed with Marek's disease	Frequency of avian diseases diagnosed as differentials to Marek's disease
Newcastle disease	50	50
Fowl pox	2	0
Colibacillosis	1	12
Aspergillosis	3	13
Fowl typhoid	7	14
Tuberculosis	0	7
Lymphoid leukosis	0	63
Helminthosis	3	0
Fowl cholera	0	1
Nutritional defficiency	3	8
Lousiness	3	0
Coligranuloma	0	1
Coccidiosis	4	0
Chronic respiratory disease	1	0

**Table 3:** Avian diseases associated with avian leukosis based on clinic records at the Avian Clinic, VTH, ABU, Zaria from 2002 - 2010

Avian diseases associated with avian leukosis	Frequency of avian diseases diagnosed with avian leukosis	Frequency of avian diseases diagnosed as differentials to avian leukosis
ND	8	4
Fowl typhoid	1	2
MD	0	13
Lousiness	2	0
Fowl cholera	0	1
Helminthosis	1	0
Colibacillosis	0	1

Marek's disease and AL were the only avian neoplastic diseases diagnosed during the study period. Fatunmbi & Adene (1986) and Olabode *et al.* (2009) also reported MD and AL as responsible for avian neoplastic diseases in South-West, Nigeria. Although reticuloendotheliosis is also a cause of neoplasm in chickens, the outbreak is not commonly encountered in the field and coupled with the fact that it could easily be confused with MD and AL (Murphy *et al.*, 1999). While the prevalence of MD increased over the period of the study from 2.49% in 2002 to 10.14% in 2010 which agreed with findings of Wakawa *et al.* (2012), Jwander *et al.* (2013) and Musa *et al.* (2013), that of AL decreased from 2.31% in 2002 to 1.13% in 2010. It is however not clear what is responsible for the increase in the outbreaks of MD as vaccination against this disease is often instituted although most of, if not all the vaccines used for this purpose are foreign, which may not confer the required immunity to chickens in Nigeria against the disease considering that several strains of the virus exist. Increase incidence of MD in many

countries was reported by Dunn & Gimeno (2013), and was attributed to higher virulent strains of the virus and presence of immunosuppressive diseases. The reasons for the decline in the outbreaks of AL could not also be discerned. Avian leukosis unlike MD, is not vaccinated against. Furthermore, there seem to be no National policy in place to control the disease in Nigeria.

Differentiating between MD and AL is difficult, especially where cutting edge diagnostic facilities and skilled manpower are inadequate. That is probably the reason why in most cases of MD reported, AL was a differential diagnosis and vice versa. It seems age of the chickens affected by avian neoplastic diseases was often used to differentiate MD from AL in this study, as there was a significant difference ( $<0.05$ ) between the age ( $20.17 \pm 2.6$ ) of chickens affected by MD and the age ( $41.43 \pm 15.4$ ) of chickens affected by AL. This could however be misleading as AL outbreaks have been reported in younger chickens (Balachandran *et al.*, 2009; Sani *et al.*, 2012), and MD in older chickens (Balachandran

et al., 2009; Wakawa et al., 2012; Jwander et al., 2013; Musa et al., 2013).

Most of the clinical signs and gross lesions were similar for both MD and AL. The clinical signs of various avian neoplastic diseases are not pathognomonic (Davidson, 2004) and co-infection of these neoplastic inducing viruses of poultry may influence the clinical outcome of the disease (Davidson & Borenstein, 1999). Also, the pathognomonic lesions such as neoplastic involvement of the sciatic nerve, which are used to differentiate MD from AL was observed in only 20.51% of the avian neoplastic disease outbreaks, whereas neoplastic involvement of the bursa of Fabricius, which is a pathognomonic lesion of AL was observed in only 3.85% of neoplastic disease

outbreaks during the period of the study. It is also worthy of note that neoplastic lesions on the rib cage was observed in 3.42% of the cases of avian neoplastic diseases. This lesion is thought to be pathognomonic for myeloid leukosis (Xu et al., 2004).

This study has shown that the prevalence of avian neoplastic disease, especially MD, is on the rise and measures must be put in place to arrest this dangerous trend. Therefore, a National program for the control of avian neoplastic diseases is urgently needed in Nigeria. A multidisciplinary research aimed at evaluating the status of each of the causes of avian neoplastic diseases in Nigeria will be of utmost importance. The economic impact of this group of avian diseases to the poultry industry in Nigeria should also be studied.

## References

- Baigent SJ & Davidson F (2004). Marek's disease virus: biology and life cycle. *In: Marek's disease: An Evolving Problem* (Davison F, Nair V, editors). Elsevier Academic Press, London, UK. Pp 62–77.
- Balchandran C, Pazhanivel N, Vairamuthu S & Murali-Manohar B (2009). Marek's disease and lymphoid leukosis in chicken- A histopathological survey. *Tamilnadu Journal of Veterinary and Animal Science*, **5**(4): 167-170.
- Davidson I (2004). Differential diagnosis of avian oncogenic viruses. <http://www.poultrymed.com/files/Oncogenic.ic>. retrieved 08-02-2010.
- Davidson I & Borenstein R (1999). Multiple infections of chickens and turkeys with avian oncogenic viruses: prevalence and molecular analysis. *Acta Virologica*, **43**(2-3): 136-142.
- Dunn JR & Gimeno IM (2013). Current status of Marek's disease in the United States and worldwide based on a questionnaire survey. *Avian Diseases*, **57**(2s1): 483-490.
- Fatunmbi OO & Adene DF (1986). A ten year prevalence study of Marek's disease and avian leukoses at Ibadan, Nigeria. *Acta Veterinaria Brno*, **55**(1-2): 49-53.
- Jwander LD, Abdu PA, Ibrahim NDG & Nok AJ (2013). Retrospective studies of Marek's disease diagnosed in some towns in Nigeria, 2000-2009. *Journal of Veterinary Advances*, **3**(7): 203-210.
- Kumbish PR, Ahmed JS, Solomon P, Wungak YS, Akanbi O, Tekki S, Joannis TM, Moses GD, Barde I.J, Meseko CA & Okewole PA (2015). Outbreak of myelocytomatosis in layer chickens Involving some commercial farms in Nigeria: Morphohistological lesions and the detection of its antigen using antigen capture ELISA. *African Journal of Cellular Pathology*, **5**(9): 18-21.
- Murphy FA, Paul J, Gibbs E, Horznek MC & Studdert MJ (1999). *Veterinary Virology*, 3<sup>rd</sup> edition, New York Academic Press. Pp 364-389.
- Musa IW, Bisalla M, Mohammed B, Sa'idu L & Abdu PA (2013). Retrospective and clinical studies of Marek's disease in Zaria, Nigeria. *Journal of Bacteriology Research*, **5**(2): 13-21.
- Okonkwo C (2015). An outbreak of Marek's disease in adult layer chickens in Umuahia, Abia state, Nigeria. *Annual Research and Review in Biology*, **7**(3): 200-205.
- Olabode HOK, Jwander LD, Moses GD, Ighodalo E & Egbaidomeh SA (2009). Prevalence of avian leukosis and Marek's disease in Ilorin, Kwara state, Nigeria. *Nigerian Veterinary Journal*, **30**(3): 64-68.
- Payne LN & Fadly AM (2003). Leukosis/sarcoma Group. *In: Diseases of Poultry*, (BW Calneck, HJ Barnees, CW Beard, CR McDougald, YX Saif, editors), eleventh edition. Iowa state University Press, Ames, Iowa. Pp 465-519.
- Payne LN & Venugopal K (2000). Neoplastic diseases: Marek's disease, avian leukosis and reticuloendotheliosis. *Review Science Technical, Office of International Epizootics*, **19**(2): 544-564.
- Sani NA, Oladele SB, Raji MA & Ibrahim DG (2011). Seroprevalence of avian leukosis virus

- antigen using ELISA technique in exotic broilers and Nigerian local chickens in Zaria, Nigeria. *Veterinary World*, **4**(8): 345-348.
- Sani NA, Oladele SB, Raji MA & Ibrahim NDG (2012). Seroprevalence of avian leukosis virus antigen using ELISA technique in commercial exotic-layer chickens in Zaria and its environs. *African Journal of Microbiology Research*, **6**(21): 4438-4442.
- Schat KA & Nair V (2008). Marek's disease. In: *Diseases of Poultry* (Saif YM, Fadly AM, Glisson JR, McDougald LR, Nolan LK & Swayne DE, editor) twelfth edition. Blackwell Publishing, Ames Iowa, USA. Pp 452-514.
- Ukashatu S, Magaji AS, Najamuddeen G & Saulawa MA (2012). Survey of poultry diseases among exotic breeds of poultry in Katsina metropolis, Katsina state, Nigeria. *Scientific Journal of Zoology*, **1**(3): 69-73.
- Wakawa AM, Muhammad ZK, Aliyu HB & Mohammed B (2012). A retrospective analysis of Marek's disease diagnosed at Poultry Clinic of Ahmadu Bello University, Zaria, Nigeria. *Journal of Veterinary Advances*, **2**(8): 424-429.
- Xu B, Dong W, Yu C, He Z, Lv Y, Sun Y, Feng X, Li N, Lee LF & Li M (2004). Occurrence of avian leukosis virus subgroup J in commercial layer flocks in China, *Avian Pathology*, **33**(1): 13-17.