



## Placenta retention in the cow: Report of three cases

KA Raheem<sup>1\*</sup>, NVS Uchechukwu<sup>1</sup>, E Odirichukwu<sup>1</sup> & O Onyegbulam<sup>2</sup>

1. Department of Veterinary Surgery and Theriogenology, Michael Okpara University of Agriculture, Umudike, Nigeria
2. Veterinary Teaching Hospital, Michael Okpara University of Agriculture, Umudike, Nigeria

\*Correspondence: Tel.: +2349031310693, E-mail: ayoraheem1@yahoo.com

### Abstract

Retention of placenta is one of the most common postpartum conditions in farm animals associated with infertility when not treated promptly and adequately. In this report, three different cases of placenta retention recently handled at Veterinary Teaching Hospital, Michael Okpara University of Agriculture, Umudike, Abia State, Nigeria are described. In the first case, the cow had a normal calving but the placenta was not expelled about 20 hours after calving. This was treated successfully with oxytocin after oestrogen priming of the uterus. The placenta was expelled 6 hours after the oxytocin injection. The second cow had a dystocia with the foetal head stuck and hanging out of vulva for over 12 hours before veterinary consultation. Episiotomy was done to deliver the dead calf and was associated with placenta retention. The case was successfully treated by applying gentle traction on the little stump of the placenta hanging out of the vulva. The third case was observed in a cattle market in which parturition was induced by stress of transporting the cow over a long distance. A pendulous weight was hung on the little placenta stump hanging from the vulva. On the following morning, treatment could not be continued as the cow had been sold off. Conditions capable of causing stress should be avoided in pregnant animal. In conclusion, this report has shown that retention of placenta is a frequent clinical phenomenon in cattle and can be successfully treated with gentle traction and oxytocin administration.

**Keywords:** Cow, Fertility, Oestrogen, Oxytocin, Placenta, Traction

Received: 11-02- 2016

Accepted: 17-06-2016

### Introduction

Retention of placenta (ROP) is one of the most common post-parturient conditions in cow. Parturition occurs at the end of gestation and can be delineated into three stages (Noakes *et al.*, 2009). The first culminates into dilation of the cervix. The second stage is expulsion of the foetus while the third stage terminates at the expulsion of placenta. In ruminant, the maternal caruncle fuses with the foetal cotyledon like a 'hand-in-glove' to produce placentome, a functional unit of the placenta (Senger, 2005). This mode of placentation in cow like other ruminants has been described as synepitheliochorial (based on five layers of membrane between the maternal and the foetal blood) and cotyledonary (based on the shape of chorionic villi around the foetus and the distribution of the contact sites between the foetus and the maternal endometrium) (Bowen, 2011).

Two factors are crucial for effective expulsion of cow placenta during parturition. First there must be detachment of the placenta from the maternal

caruncle. Secondly, there must be enough expulsive force from the uterine contraction to initiate further detachment and cause expulsion of detached placenta with no mechanical obstruction. Whenever there is a compromise in either of these two underlying factors, ROP is imminent (Jackson, 2004). Collagenase secreted by the placenta during parturition leads to weakening of the mechanical link and subsequent detachment of the placenta from the uterus. The mechanical actions of uterine contraction during the first and second stages of parturition stimulate compression of the placentomes and begin the separation of the two parts (foetal cotyledons and maternal caruncle), while placenta expulsion from the uterus is effectively completed with further contraction during the third stage (Hafez & Hafez, 2006). These mechanisms require some time. Therefore, placenta is not said to be retained in cattle until 12 hours after parturition (Jackson, 2004).

ROP has a significant adverse impact on health, welfare, milk productivity and reproduction of affected animals in the postpartum period (Laven & Peters, 1996). Therefore, for cattle production to be more economically viable, the incidence of ROP has to be reduced and the adversity of the condition mitigated through prompt medical attention to treat the condition.

In this article, we report three cases of ROP in cow, two of which were presented to Veterinary Teaching Hospital, Michael Okpara University of Agriculture, Umudike, Abia State, Nigeria while the last one was observed during an ambulatory visit to a cattle market. The causes, treatment and preventions of this postpartum condition are further discussed.

### Case History and management

#### Case 1

A White Fulani cow was bought from a Fulani Herdsman with no history of vaccination, deworming and previous treatment. The breeding history was not also known. The owner noticed the animal to be pregnant by the enlargement of the abdomen at the time of purchase as he was being told by the seller. Few months after purchase, the cow calved successfully over the night but the placenta still remained in the uterus. On presentation of the case to the Veterinary Teaching Hospital, Michael Okpara University, Umudike, basic clinical parameters were taken (Table 1). Further examination revealed the cow was in good body condition. The hair coat was good and the animal was alert. A lubricated gloved hand was made into a cone shape and inserted into the vaginal to evaluate its content. This digital palpation of the vagina with thumb, fore and middle fingers caused the animal to strain which made a piece of the placenta to hang out of the vulva. Therefore, an attempt made to manually remove the stump by applying gentle traction failed. Therapeutic treatment was evident. The cow was given 10 mg oestrogen (Oestradiol Cypionate ECP<sup>®</sup>, Up John, USA) injection intramuscular. This was successively followed by 20 IU oxytocin injection intramuscular. The placenta dropped about 6 hours after the oxytocin injection. The cow was kept on broad spectrum

long acting antibiotic- Oxy-T Q<sup>®</sup> 20 mg/Kg (De Santo Pharm, Nig.) by intramuscular injection start.

#### Case 2

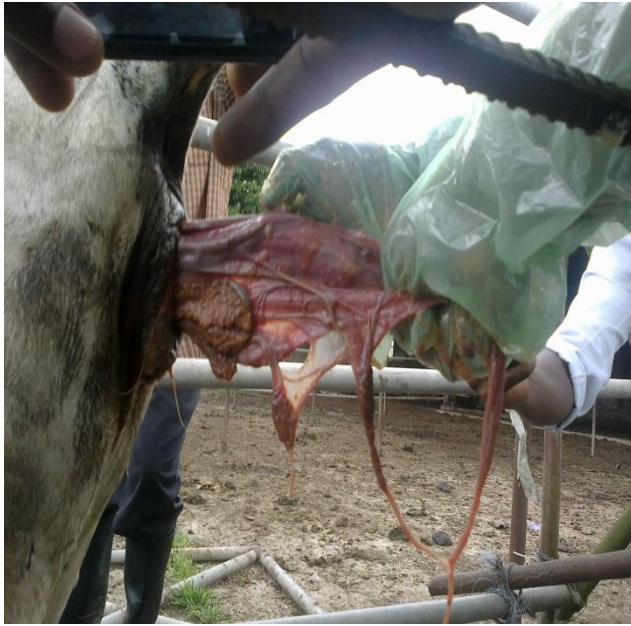The attention at the Veterinary Teaching Hospital was called for a cow belonging to the University Student and Research Farm of Michael Okpara University of Agriculture, Umudike. The cow had dystocia with a dead foetus whose head was hanging out of the vulva. The clinical parameters were taken (Table 1). Episiotomy was done to deliver the dead calf and was associated with ROP. The case was treated by applying gentle traction on the little stump of the placenta hanging out of the vulva (Plate I) and the whole of the placenta was successful pulled out of the uterus (Plate II). The cow was then treated with broad spectrum antibiotics (Penstrept<sup>®</sup>) at 1ml/20kg body weight daily intramuscularly for 5 days.

#### Case 3

The case was seen during an ambulatory visitation to a cattle market. A pregnant White Fulani Cow was transported over 20 hours from Northern to Eastern, Nigeria. It delivered a healthy calf immediately after arrival. Clinical parameters of the cow were taken (Table 1) and were within the normal range of values. The animal was on sternal recumbency and had to be assisted to stand up. Inability to stand was attributable to general weakness as the pedal reflex was present and no evident of fracture on the limbs. Tran-rectal palpation was done to eliminate the presence of another foetus in the uterus. Diagnosis was induced parturition due to stress. The period of delay in placenta expulsion was not up to 12 hours as at the time of our visit, although ROP is imminent in this case. An attempt was made to manually remove the hanging placenta stump but could not be completely expelled. Then, a pendulous weight was tied on to the hanging stump such that movement of the cow would gradually exert minimal pressure to the point of attachment with the maternal caruncle and eventually be expelled (Plate III). We expected to treat the condition on the following day for retained placenta as done for case 2 first before using case 1 approach but the animal had been sold before our arrival.

**Table 1.** Clinical parameters of the cows treated for placenta retention

|                    | Cow 1   | Cow 2   | Cow 3   |
|--------------------|---------|---------|---------|
| Rectal temperature | 38.4 °C | 38.0 °C | 39.0 °C |
| Heart rate         | 57 bpm  | 60 bpm  | 55 bpm  |
| Respiratory rate   | 35 cpm  | 39 cpm  | 41cpm   |
| Pulse rate         | 54 bpm  | 55 bpm  | 63 bpm  |



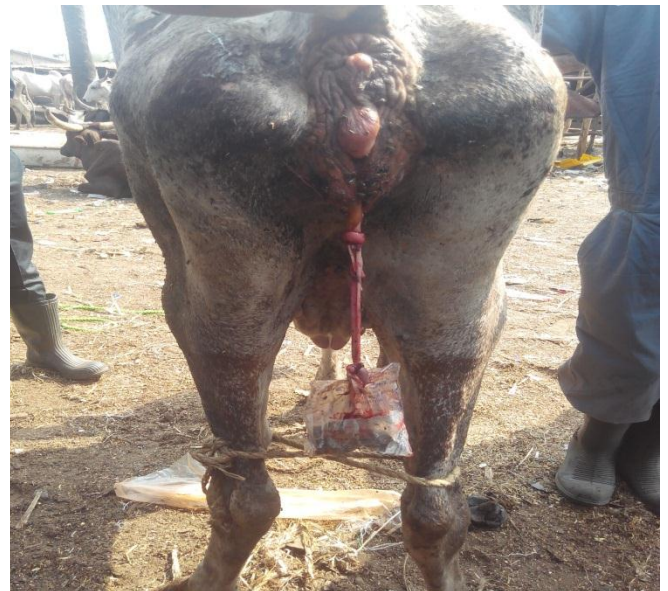
**Plate I:** Gradual traction was gently applied on the placenta hanging stump from the vulva



**Plate II:** A whole placenta after it was completely pulled out of the uterus

### Discussion

Retention of placenta in farm animals is a serious post-parturient disorder which occurs in the last phase of parturition. The incidence of ROP in cow is estimated to be 4-16% (Amin *et al.*, 2013), which is relatively higher than other farm animals (Ayele *et al.*, 2014). The 'finger-in-glove' like cotyledon placentation in cow is believed to contribute to the condition (Peter, 2013). Predisposing factors to ROP are dystocia, milk fever and multiple births as well as many other metabolic or reproductive conditions including stress (Trevisi *et al.*, 2008) capable of compromising the detachment and expulsion cascade of the placenta from the maternal uterus. In this report, the cause of ROP in case 1 could not be ascertained. The second case 2 was caused by dystocia due to absolute foetal oversize. In case 3, stress induced-parturition was observed. The mechanism of stress inducing parturition involves the release of cortisol which is an important hormone in parturition regulation (Senger, 2005). The weakness observed in cow 3 led to failure of the cow to generate adequate uterine contraction necessary for placenta expulsion during the third stage of labour. The first line of treatment for ROP is to ensure via trans-rectal palpation that no foetus remains in the uterus. Trans-rectal palpation will stimulate uterine contraction enough to expel the retained placenta or make a little stump of placenta to hang out of the vulva. Then, a gradual traction could be gently applied to the hanging placenta stump. Sometimes this approach as explored in case 2 is what is required to expel the placenta. A forceful traction should be avoided as it will produce



**Plate III:** A pendulous weight tied to the placenta stump hanging out of the vulva

haemorrhage and further complicate the condition.

The next line of action is therapeutic treatment of ROP which involves using an ecbolic to initiate contraction of the uterus. The most common drugs of choice in the field are oxytocin and prostaglandins  $F_{2\alpha}$  (Amin *et al.*, 2013). Oxytocin is a preferred drug especially when detachment has occurred (Miller & Lodge, 1984). However, there is a prior need for the uterus to be primed with oestrogen before an optimal response to the contractility effect of the oxytocin can be initiated (Bossmar *et al.*, 2007). Oestrogen is believed to elevate expression of oxytocin receptors in the endometrium (Wathes & Hamon, 1993; Robinson *et al.*, 2001). Oxytocin has to bind to oxytocin receptor in order to elicit its effect (Wathes *et al.*, 1999). The positive



response of placenta expulsion observed in case 1 further substantiates this concept. Injection of collagenase into the placental end of the umbilical artery facilitated separation of placenta from the cow uterus under an experimental setting (Eiler & Hopkins, 1993). Advancement of this mode of therapy into clinical practice for treating ROP in bovine, mare and woman is viable as bacterial collagenase efficiently break down placenta in an *in vitro* study when placenta samples from human, equine and bovine were incubated with bacterial collagenase (Fecteau *et al.*, 1998). As a last resort, hysterectomy is indicated for ROP that fails to respond to the aforementioned treatments. Sometimes, uncomplicated cases of ROP are normally left untreated due to poor response to manual removal and uncertain effects of ecobolic agents (Arthur & Bee, 1996). This however requires a certain level of conviction of the owners to allow for natural expulsion. Untreated retained placenta undergoes autolysis but is not expected to be released before 6 to 10 days after calving. It is worthy to mention that as efficient as this method is, it may be associated with risk of infection, the main reason why it was not utilised in these cases.

The cow in case 3 was sold out for meat. The uterus may not be condemned and erroneously passed for human consumption due to inadequate inspection in Nigerian abattoirs (Raheem & Ameen, 2008). Therefore, there is a public health

implication of eating such meat since that uterus was highly susceptible to microbial contamination. Good management that implements adequate breeding records and sufficient feeding-regime as well as other farm variables conducive for establishing eutocia (normal parturition) are important factors that reduce the incidence of ROP as well as its negative impact on reproductive efficiency and farm economics (Islam *et al.*, 2013). Retention of placenta predisposes the cow to infertility as a result of infection to the uterus. In addition, uterus involution is delayed, sequel to which is anoestrus and reduced fertility in the affected animal due to prolong inter-oestrus interval (Grunert, 1986). None of the cows in this report showed systemic condition as the clinical parameters were within the normal range for this specie. It was obvious that the uterus/placenta had not been contaminated as the expelled placenta looked fresh.

In conclusion, this report has shown that retention of placenta is a frequent clinical phenomenon in cattle and is successfully treatable with gentle traction and oxytocin administration. It is reasonable to envisage that the ROP after being successfully treated in these cows will not affect their future reproductive efficiency especially when the placenta did not show evidence of infection that could have been transferred to the uterus.

## References

- Amin Rooh Ul, GR Bhat, A Ahmad, Partha Sarathi Swain & G Arunakumari (2013). Understanding patho-physiology of retained placenta and its management in cattle: a review. *Veterinary Clinical Science*, **1**(1): 01-09.
- Arthur GH & Bee D (1996). In *Veterinary Reproduction and Obstetrics* (GH Arthur, DE Noakes, H Pearson & TJ Parkinson, editors) Seventh edition, London. B. Saunders.
- Ayele G, Mekibib B & D Sheferaw (2014). Postpartum problem of dairy cows in management of small and medium scale production systems in Wolaita, Sodo, Ethiopia. *African Journal of Agricultural*, **9**(36): 2775-80.
- Bossmar T, Osman N, Zilahi E, Haj MAE, Nowotny N & Conlon JM (2007). Expression of the oxytocin gene, but not the vasopressin gene, in the rat uterus during pregnancy: influence of oestradiol and progesterone. *Journal of Endocrinology*, **193** (1):121-126.
- Bowen R (2011). Placental structure and classification. In *Pathophysiology of the Reproductive System* (Colorado State University <http://www.vivo.colostate.edu/hbooks/pathphys/reprod/placenta/structure.html>, retrieved 10-01-2014).
- Eiler H & FM Hopkins (1993). Successful treatment of retained placenta with umbilical cord injections of collagenase in cows. *Journal of American Veterinary Medical Association*, **203**(3):436-443.
- Fecteau KA, JC Haffner & H Hiler (1998). The potential of collagenase as a new therapy for separation of human retained placenta: Hydrolytic potency on human, equine and bovine placentae. *Placenta*, **19** (5):379 – 383.
- Grunert E (1986). *Etiology and pathogenesis of bovine retained placenta*. In: *Current Therapy in Theriogenology*. Second edition, W13 Saunders Co. Philadelphia, London, Toronto, Mexico city. PP. 237-242.
- Hafez ESE & Hafez B (2006). *Reproduction in Farm Animals*. Seventh edition. Blackwell Publishing Limited, UK Pp 261-278.

- Islam MH, Sarder MJU, Jahan SS, Rahman M, zahan M, Kader MA & Hossain KMM (2013). Retained placenta of dairy cows associated with managemental factors in Rajshahi, Bangladesh. *Veterinary World*, **6**(4): 180-184.
- Jackson P (2004). *Handbook of Veterinary Obstetrics*. Saunders, Edinburgh, United Kingdom. Pp 218-220.
- Laven RA & Peters A (1996). Bovine retained placenta: etiology, pathogenesis and economic losses. *Veterinary Record*, **139**(19): 465–71.
- Miller BJ & Lodge JR (1984). Postpartum oxytocin treatment for prevention of retained placentas. *Theriogenology*, **22**(4): 385-388.
- Noakes DE, Parkinson TJ & England, GC (2009). *Veterinary Reproduction and Obstetrics.. Ninth Edition*. Elsevier, China. Pp 950.
- Peter AT (2013). Bovine placenta: a review on morphology, components and defects from terminology and clinical perspectives. *Theriogenology*, **80**(7): 693–705.
- Raheem AK & Ameen SA (2008). The future roles of veterinarian in food safety in Nigeria. *Nigeria Veterinary Journal*, **69**(3): 64-67.
- Robinson RS, GE Mann, GE Lamming & DC Wathes (2001). Expression of oxytocin, oestrogen and progesterone receptors in uterine biopsy samples throughout the oestrous cycle and early pregnancy in cows. *Reproduction*, **122**(6): 965-979.
- Senger PL (2005). *Pathways to pregnancy and parturition*, Current Conceptions, *Second edition*. Pullman, WA, xii, Pp 373.
- Trevisi E, Ferrari AR & Bertoni G (2008). Productive and metabolic consequences induced by the retained placenta in dairy cows. *Veterinary Research Communication*, **32**(1): 363–366.
- Wathes DC, Borwick SC, Timmons PM, Leung ST & Thornton S (1999). Oxytocin receptor expression in human term and preterm gestational tissues prior to and following the onset of labour. *Journal of Endocrinology*, **161**(1): 143-151.
- Wathes DC & M Hamon (1993). Localization of oestradiol, progesterone and oxytocin receptors in the uterus during the oestrous cycle and early pregnancy of the ewe. *Journal of Endocrinology*, **138**(3): 479-492.