



## Novel use of ear sockets as points of traction in partial foetotomy in Bunaji cows

AA Bello<sup>1\*</sup>, S Danbirni<sup>2</sup>, G Mohammed<sup>2</sup>, JS Rwuan<sup>1</sup>, AK Mohammed<sup>3</sup> & AKB Sackey<sup>2</sup>

<sup>1.</sup> Department of Theriogenology and Production, Faculty of Veterinary Medicine, Ahmadu Bello University, Zaria.

<sup>2.</sup> Department of Veterinary Medicine, Faculty of Veterinary Medicine, Ahmadu Bello University Zaria.

<sup>3.</sup> National Animal Production Research Institute, Shika, Ahmadu Bello University Zaria

\*Correspondence: Tel.: +234803 6153483, E-mail: adehabello@abu.edu.ng

### Abstract

Dystocia was managed in 4½-, 3- and 3½-year-old Bunaji and Bunaji-Friesian cross cows at the University farm, a Fulani camp and an Institutional farm, respectively. Clinical examination showed normal vital parameters, straining, well relaxed perineum, oedematous vulva, fully engorged mammary glands and extended foetal fore-limbs. Vaginal exploration revealed fully relaxed cervixes, dead foetuses in anterior longitudinal presentation and dorso-sacral positions. The necks and heads were flexed laterally and dorsally. Dystocia of foetal causes due to postural abnormalities (lateral and dorsal flexion of the neck) were diagnosed. Amputations of fore-limbs of the foetuses at the point of the shoulders using Thygesen<sup>®</sup> foetotome and obstetrical wire were done. A crutch-repeller placed between the neck and the stump of shoulder of the amputated fore-limb was then used to repel the foetuses into the uteri to achieve extension of the neck. Extension of the flexed necks and heads was achieved by the use of three-point traction on the heads and repulsion concurrently. Traction was used to deliver the dead foetuses while guarding the points of amputation in the birth canals. It was concluded that the ear socket can be used as a new point of traction along with or in place of the eye socket in partial foetotomy for relieving dystocia with non-viable foetus in Bunaji cows.

**Keywords:** Bunaji cow, Dystocia, Ear, Foetotomy, Obstetrical-wire, Traction

Received: 28-08- 2015

Accepted: 16-02-2016

### Introduction

Dystocia is one of the common obstetrical problems encountered in large animal practice especially in the bovine species (Wehrend *et al.*, 2002; Hussein & Abdellah, 2008; Jos, 2008; Otto, 2011). Most dystocia are due to maternal or foetal causes (Dhadake *et al.*, 2005), with the foetal causes occurring more commonly (Wehrend *et al.*, 2002). Depending on a number of factors, different methods and approaches are adopted for relieving dystocia which include foetotomy (total or partial), caesarean section, mutation, forced extraction, symphysiotomy and episiotomy (Wehrend *et al.*, 2002). Use of foetotomy has been reported in both domestic (Mortimer *et al.*, 1984; Wehrend *et al.*, 2002; Leduc, 2007) and wild (Schaftenaar *et al.*, 2010) animals. The three cardinal aims of relieving dystocia are: (a) saving the dam, (b) saving the foetus and (c) maintaining normal fertility of dam

and foetus where possible. These three cardinal aims should be the focus and pursued without overlooking any, but with priority accorded in the order (a-c) in which they are highlighted.

Foetotomy generally is a technique in which a dead foetus is dismembered in the uterus to reduce its size for delivery (Mortimer *et al.*, 1984; Wehrend *et al.*, 2002; Leduc, 2007). The technique has been applied severally in the bovine and other species (Wehrend *et al.*, 2002; Jos, 2008). In achieving this procedure, several obstetrical instruments are used which include foetotome, obstetrical wire, obstetrical hooks, mandibular snare, crutch repeller, etc, and these instruments are applied at specific points for cutting, traction and repulsion (Otto, 2011). Consistent clinical use of these instruments over the years indicated the need to explore further the application of some of

them, especially in some peculiar clinical field situations. This report is describing for the first time the experiences gained over the years during management of three clinical cases in which a new point of traction using the eye hooks and obstetrical wire were explored to relieve dystocia by partial foetotomy.

### **Case History and management**

#### *Case 1*

The attention of the ambulatory team of the Veterinary Teaching Hospital (VTH), Ahmadu Bello University Zaria, was drawn to a 4½-year-old Bunaji cow that had dystocia at Ahmadu Bello University Farm. The cow had delivered normally without assistance previously in her first calving. Labour was noticed at about the 17th hour the previous day after the herd returned from grazing. The following clinical findings were observed: normal vital parameters, straining, well relaxed perineum, oedematous vulva, fully engorged mammary glands and foetal fore-limbs presentation. Vaginal exploration revealed a fully relaxed cervix, dead foetus in an anterior longitudinal presentation and dorso-sacral position. The forelimbs were extended but the neck and head were flexed laterally. The condition was not long standing and the cow was alert.

Dystocia of foetal cause due to postural abnormality (left lateral flexion of the neck) was diagnosed (not illustrated). Case management was done by partial foetotomy. Lubrication was not necessary because the condition was not long standing, except for thorough washing of the vulva and the presented limbs liberally with water. The obstetrical instruments were equally washed and disinfected with Purit® (Chlorhexidine and Centromide; Saro LifeCare Ltd, Apapa, Lagos, Nigeria). Restraint was on sternal recumbency with the cow tilted slightly to the right and the hind limbs extended anteriorly and stabilized with ropes. Amputation of the left forelimb of the foetus at the point of the shoulder was done using the Thygesen® foetotome and obstetrical wire (saw wire) (Otto, 2011). The procedure was repeated on the right forelimb at the same point with the same instruments. A crutch-repeller placed between the neck and the stump of shoulder of the amputated left fore-limb was then used to repel the foetus into the uterus. Three-point traction was applied by placing two eye hooks and use of mandibular snare. One eye hook each was applied at right and left ear sockets and both affixed to obstetrical chains, and the mandibular snare at the diastamer space of the lower mandibular bone. Extension of the flexed neck and head was achieved by the use of the three-point traction on the head and repulsion concurrently. Traction was used to deliver the

foetus while guarding the points of amputation with the hand in the birth canal following the neck and head extension. The uterus was explored for possible additional foetuses, foetal membranes and uterine tears or ruptures, all of which proved negative. The entire perineum was cleaned and washed thoroughly with water containing disinfectant and the cow was induced by gentle tap with the free hand to stand in order to check for possible paralysis of the hind quarters and other traumatic injuries which were also not detected as the cow moved freely without sign of pains or difficulties. Oxytetracycline – long acting (Tridox®; FARVET, Holland) was administered at the gluteal muscle at 20 mg/kg body weight, deep i/m, to the cow after the procedure. Water and feed were then offered to help overcome exhaustion and fatigue, at which the cow fed normally and was monitored for thirty minutes.

#### *Case 2*

Ambulatory team of the Veterinary Teaching Hospital (VTH), Ahmadu Bello University, Zaria attended to a 3-year-old Bunaji cow that had dystocia at a Fulani camp. The 3-year-old cow was a primer. Labour was noticed at about the 18th hour the previous day after the herd returned from grazing. Clinical signs observed were normal vital parameters, straining, well relaxed perineum, oedematous vulva, fully engorged mammary glands and foetal fore-limbs presentation. Vaginal exploration revealed a fully relaxed cervix, dead foetus in an anterior longitudinal presentation and dorso-sacral position. The forelimbs were extended but the neck and head were flexed laterally. The condition was not long standing and the cow was alert.

Dystocia of foetal cause due to postural abnormality (right lateral flexion of the neck) was diagnosed (Fig. 1). Case management was done by partial foetotomy. Similarly, lubrication was not necessary, except for thorough washing of the vulva and the presented limbs liberally with water. The obstetrical instruments were washed and disinfected with Purit® (Chlorhexidine and Centromide; Saro LifeCare Ltd, Apapa, Lagos, Nigeria). Restraint was on sternal recumbency with the cow tilted slightly to the right and the hind limbs extended anteriorly and stabilized with ropes. Amputation of the left forelimb of the foetus at the point of the shoulder was done using the Thygesen® foetotome and obstetrical wire (saw wire) (Otto, 2011). The procedure was repeated on the right forelimb at the same point with the same instruments. A crutch-repeller placed between the neck and the stump of shoulder of the amputated left fore-limb was used to repel the foetus. Three-point traction was applied by placing two eye hooks and use of

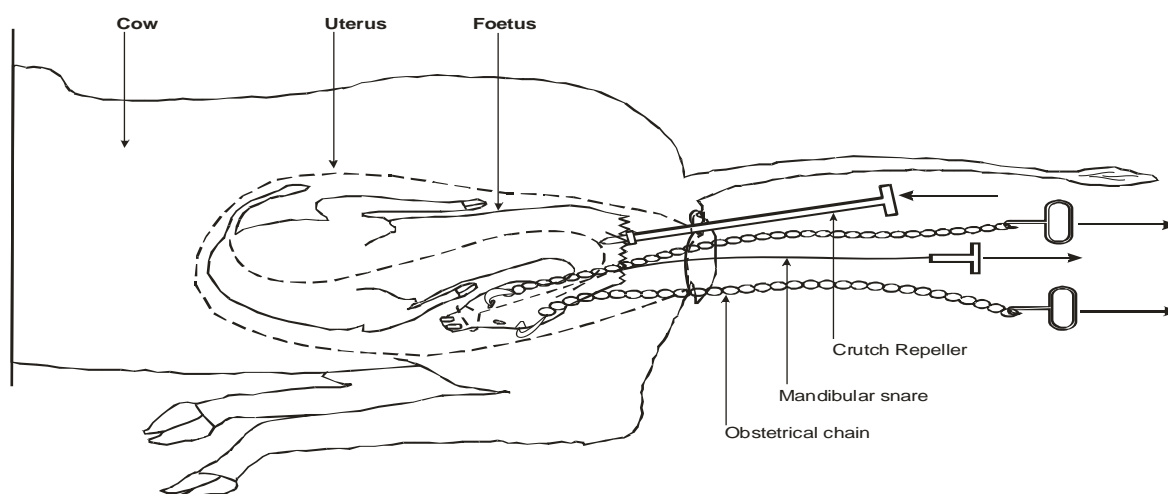
mandibular snare. One eye hook was applied at the medial cantus of the right eye and the other at the left ear socket and both affixed to obstetrical chains, and the mandibular snare at the diastamer space of the lower mandibular bone (Fig. 1). Extension of the flexed neck and head was achieved by the use of the three-point traction on the head and repulsion concurrently. Traction was used to deliver the fetus while guarding the points of amputation with the hand in the birth canal following the neck and head extension. The uterus was explored for possible additional foetus, foetal membranes and uterine tears or ruptures, all of which proved negative. The entire perineum was cleaned and washed thoroughly with water containing disinfectant and the cow was induced by gentle tap with the free hand to stand in order to check for possible paralysis of the hind quarters and other traumatic injuries which were also not detected as the cow moved freely without sign of pains or difficulties. Oxytetracycline – long acting (Tetranor®; JAT, China) was administered at the gluteal muscle at 20 mg/kg body weight, deep i/m, to the cow after the procedure. Water and feed was then offered to help overcome exhaustion and fatigue, at which the cow fed normally and was monitored for up to about twenty minutes.

### Case 3

Similarly, a case was handled by the Animal Health Unit of National Animal Production Research Institute (NAPRI), Shika, Ahmadu Bello University, Zaria of a 3½-year-old Bunaji-Friesian cross cow that had dystocia at the Dairy Farm of the Institute. The cow had delivered normally without assistance previously in her first calving. Labour was noticed 60 hours before handling. The following clinical findings were observed: vital parameters were normal except for temperature (39° C), straining, well relaxed perineum,

oedematous vulva, fully engorged mammary glands, foetal fore-limbs presentation and mild dehydration. Vaginal exploration revealed a fully relaxed cervix, dead foetus in an anterior longitudinal presentation and dorso-sacral position. The forelimbs were extended but the neck and head were flexed dorsally.

Dystocia of foetal cause due to postural abnormality (dorsal flexion of the neck) was diagnosed (not illustrated). Case management was done by rehydrating with 5% dextrose saline (total of 3,000 ml), liberal pumping of normal saline into the uterus for lubrication and partial foetotomy. The obstetrical instruments were washed and disinfected with Purit® (Chlorhexidine and Centromide; Saro LifeCare Ltd, Apapa, Lagos, Nigeria). Restraint was on sternal recumbency with the cow tilted slightly to the right and the hind limbs extended anteriorly and stabilized with ropes. Amputation of the left forelimb of the foetus at the point of the shoulder was done using the Thygesen® foetotome and obstetrical wire (saw wire) (Otto, 2011). The procedure was repeated on the right forelimb at the same point with the same instruments. A crutch-repeller placed between the neck and the stump of shoulder of the amputated left fore-limb was used to repel the foetus into the uterus to achieve extension of the neck. Obstetrical wire was used to perforate the soft tissue in-between ramus of lower mandibular bone to form a loop and the ends drawn to the outside. This was necessary because the obstetrical wire was the only available 'traction' instrument at that moment. Extension of the neck was achieved by applying traction on the mandible with the obstetrical wire loop while guarding the mouth. Traction was used to deliver the fetus using rope placed on foetal neck while guarding the points of amputation with the hand



**Figure 1:** Illustration of extension of right lateral flexion of the neck and head in a Bunaji (White Fulani) cow following amputation of fore-limbs. Note eye hooks at ear and eye sockets and the direction of force indicated by arrows

in the birth canal following the neck and head extension. The uterus was explored for possible additional fetuses, foetal membranes and uterine tears or ruptures, all of which were not found. The entire perineum was cleaned and washed thoroughly with water containing disinfectant. Oxytetracycline – long acting (Tridox®; FARVET, Holland) was administered at the gluteal muscle at 20 mg/kg body weight, deep i/m, to the cow after the procedure. The cow was induced by gentle tap with the free hand to stand in order to check for possible paralysis of the hind quarters and other traumatic injuries. But the cow could not stand for about six hours, where it had to be assisted to stand by being manually lifted up, and no paralysis or traumatic injury was found. Water and feed were then offered to help overcome exhaustion and fatigue, at which the cow fed normally and was monitored for 24 hours.

### Results and Discussion

Partial foetotomy technique used in this report successfully relieved the dystocia and is the commonest form of foetotomy in the bovine species as reported by Leduc (2007) and Otto (2011). A significant aspect of this report is the novel use of the ear sockets and the in-between ramus of lower mandibular bone as new points of traction using the eye hook and the obstetrical wire respectively. More so, the “extra label use” of the obstetrical wire used as a traction instrument in contrast to the conventional application as a saw or cutting instrument is another new approach. Particularly the ear socket provided a good and balanced point for the hooks for traction

### References

Dhadake SM, Birade SA, Chinchkar SR, Badgujar CR, Gulavane SU & Dagli NR (2005). Comparative study of foetotomy and caesarean section in buffaloes. *The Journal of Bombay Veterinary College*, **13** (1- 2): 42 – 45.

Hussein H & Abdellah MR (2008). Effect of dystocia, fetotomy and caesarean section on the liver activities and concentration of some serum biochemical parameters in dairy cattle. *Animal Reproduction Science*, **105** (3 – 4):384 – 391.

Jos JV (2008). The caesarean operation in cattle: a review. *Iranian Journal of Veterinary Surgery –Supplementary for the 2<sup>nd</sup> ISVS and ISVSAR*, 82 – 100.

Leduc F (2007). Partial foetotomy. *American College of Theriogenologist (ACT)*, Copyright © 2000 – 2010. The Drost project, 1.

Mortimer RG, Ball L & Olson JD (1984). A modified method for complete bovine fetotomy.

such that it was later realized that the mandibular snare was not really necessary for the famous three-point traction. This may mean that the use of the mandibular snare which most often cuts off the mandibular bone at the point of application when under intense tension of traction due to the developing soft bones of the foetus may not be favoured during some foetotomy procedures, thereby providing space for further manipulations and more significantly resulting in a ‘two-point traction’ technique in similar situations. Furthermore, the application of the eye hook at the ear socket in foetotomy provides an alternative to the familiar eye socket and hence, for better traction especially when used with the obstetrical chain. These may be used for both neck extension and force extraction in foetotomy. This appears to have opened a small window for further exploration that requires more investigation, confirmation and establishment, as this is the first time the procedure is being described, particularly in the Bunaji.

It was concluded that the ear socket can be used as a new point of traction along with or in-place of the eye socket in partial foetotomy for relieving dystocia with non-viable foetus in Bunaji cows.

### Acknowledgement

We acknowledge the Directors, Veterinary Teaching Hospital (VTH) and National Animal Production Research Institute (NAPRI) Shika, Ahmadu Bello University Zaria and their staff for the facilities and assistance offered during handling of these cases.

*Journal of the American Veterinary Medical Association*, **185** (5): 524 -536.

Otto S (2011). Fetotomy in large animals – power point, <http://www.univet.hu/units/Szuleszet/Pdf%20anyagok/Fetotomy-EN.pdf>, retrieved 09-05-2014.

Schaftenaar W, Fernandes T, Fritsh G, Frey R, Szentiks CA, Wegner RD, Hildebrand TB & Hermes R (2010). Dystocia and fetotomy associated with cerebral aplasia in a greater one-horned rhinoceros (*Rhinoceros unicornis*). *Reproduction in Domestic Animals*, 01610 (10.1111): 1439 – 0531.

Wehrend A, Reinle T, Herfen K & Bostedt H (2002). Fetotomy in cattle with special reference to post-operative complications – an evaluation of 131 cases. *Deutsche tierärztliche Wochenschrift*, **109**(2): 56 – 61.