



## Blood transfusion due to haemonchosis induced anaemia in a 4-year-old Kano brown doe

BY Kaltungo<sup>1\*</sup>, II Onoja<sup>2</sup>, M Babashani<sup>1</sup> & SO Okaiyeto<sup>1</sup>

<sup>1.</sup> Veterinary Teaching Hospital, Ahmadu Bello University Zaria, Kaduna State

<sup>2.</sup> Department of Veterinary Medicine, Ahmadu Bello University Zaria, Kaduna State

\*Correspondence: Tel.: +2348038884381, E-mail: docbilki@yahoo.com

### Abstract

A 4-year-old Kano brown doe weighing 20kg from a flock of 5 does was presented to the Veterinary Teaching Hospital Ahmadu Bello University Zaria with complaints of unthriftiness, emaciation inappetence, weakness and pasty diarrhea of two weeks duration. Thorough physical examination revealed pale mucous membranes with submandibular edema and puffy face which were indications of hypoproteinemia. Hematological results indicated a packed cell volume (PCV) of 12% on the day of presentation and 9% on the third day. Fecal culture revealed *Haemonchus* larvae. Blood (400mls) from a donor buck in the goat pen of the faculty was transfused on the third day of presentation through the jugular vein. Two days later a blood sample was collected and a hemogram was performed, the result indicated an appreciable PCV value (15%) and a hemoglobin concentration of 5g/dl. It can therefore be concluded that blood transfusion can be a life-saving procedure in haemonchosis induced anaemia.

**Keywords:** Blood transfusion, Doe, Goat, *Haemonchus*, Hypoproteinemia, Kano-brown

Received: 09-02- 2015

Accepted: 05-02-2016

### Introduction

In veterinary medicine, red blood cell transfusion forms an integral part of life-saving procedures which are used in critically ill animals (Weingart *et al.*, 2004; Mamak & Aytekin, 2012). It is indicated in the treatment of anemia caused by hemorrhage, hemolysis, ineffective erythropoiesis, African trypanosomosis and gastrointestinal helminths (Mudge, 2010). Oxygen in blood is mostly carried by hemoglobin (Hb) because it is poorly soluble in plasma. However, in anemic patients, this function is highly compromised leading to inadequate tissue perfusion. Blood transfusions increase the oxygen-carrying capacity of blood, therefore, inadequate delivery of oxygen to tissues with consequent tissue hypoxia are prevented or treated (Callan, 2010). Where there are no specific "transfusion triggers," the choice of a veterinarian to do a transfusion, relies on the combination of physical examination and clinico-pathological parameters of the animal (Mudge, 2010).

In emergency management of severe anemia, the decision to transfuse blood should be based on the prognosis of the underlying condition and the availability of a suitable donor (Ermilio & Smith, 2011). Treatment of the underlining cause of anemia should be highly considered, as

transfusions are regarded as only temporary; with donor erythrocytes being cleared in an average of 8 days in goats (Smith & Sherman, 2009). Cross-matching small ruminant blood before an initial transfusion is not very necessary because of the minimal level of agglutinating antibody present in ruminant serum. However, it becomes necessary when multiple transfusions are to be performed (Divers, 2005; Mudge, 2010).

Haemonchosis in small ruminants is caused by *Haemonchus contortus* which is a predominant, highly pathogenic gastro-intestinal parasite of major economic importance in sheep and goats (Mortensen *et al.*, 2003). Estimated losses associated with *H. contortus* are higher than those due to peste des petits ruminants (PPR), a foremost disease of importance in goats (Akerajola *et al.*, 1979). It can lead to severe anemia, poor growth rates, and reduced milk yield (Okaiyeto *et al.*, 2010). Heavy infestation can lead to death (Allonby & Dargie, 1973; Thomas & Ali, 1983; Rowe *et al.*, 1988; Githigia *et al.*, 2001). Generally, gastrointestinal parasites substantially hinder the production and activation processes of the hemopoietic tissue leading to anemia, hypoproteinemia and thereby compromising the

immune system (Bastianetto *et al.*, 2011). This paper reports the management of haemonchosis-induced anemia in a Kano Brown doe by blood transfusion.

**Case Presentation and Management**

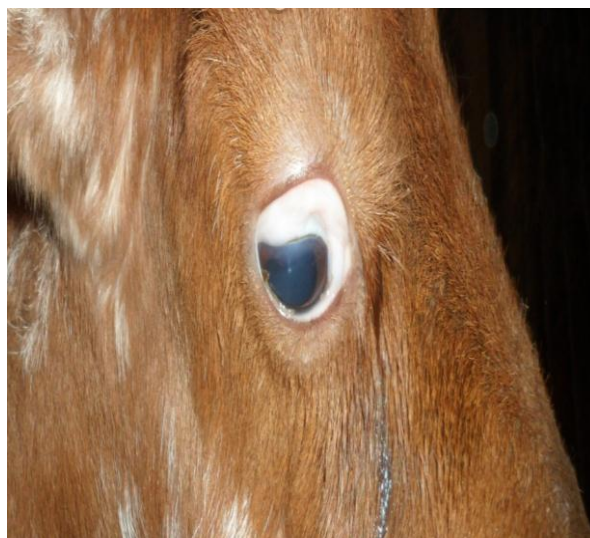
A 4-year-old Kano Brown doe weighing 20kg from a flock of 5 does was presented to the Large Animal Clinic of the Veterinary Teaching Hospital (VTH), Ahmadu Bello University Zaria with complaints of severe diarrhea of two weeks duration, lassitude and puffy face (Plate 1). The goats were managed on a semi-intensive system and had no history of deworming. Physical examination revealed depression, pale mucous membrane (Plate 2), bilateral serous ocular discharge, and severe weakness, while rumen motility, assessed by placing a stethoscope in the left paralumbar fossa, was very weak and the body condition score was 2 on a scale of 5 (Detweiler *et al.*, 2008). The rectal temperature was 38.8°C; pulse 108 beats per minute, and the respiratory rate 16 breaths per minute.

Blood and rectal fecal samples were collected and sent to clinical pathology and helminthology

laboratories of the VTH for haemogramme and parasite screening respectively. The fecal sample was cultured for two weeks using the Baermann’s technique to obtain third stage larvae; these larvae were collected for further identification. The animal was treated after one week of presentation using Albendazole suspension at 7.5mg/kg live body (once) and 400 ml of whole blood was collected from a healthy buck in the goat pen of the faculty and was transfused intravenously. The donor buck weighed 30kg and screened for haemoparasites and other infectious agents like brucellosis. Four hundred milliliters of blood were drawn from the donor in a blood bag containing citrate phosphate and immediately transfused very slowly for the first 30 minutes through a blood filter set and sterile jugular catheter, after which the rate was increased due to absence of any adverse reaction. The hematological parameters were re-evaluated 2 days after the transfusion; and it was observed that the packed cell volume and the hemoglobin concentration showed some improvements (Table 2).



**Plate I:** showing puffy face and Submandibular edema



**Plate II:** showing paper white ocular mucous membrane

**Table1:** Clinical pathology and helminthology results before blood transfusion

	Haematology			Biochemistry		Helminthology	
	Day 1	Day 3	Normal Range	Obtained values	Normal Range	Strongyle eggs	+++
PCV %	12	9	22-39	Total protein g/dl	4	6.4-7.9	
Hb g/dl	4	3	8-14	Albumin g/dl	1.6	2.4-4.4	
WBC ×10 <sup>9</sup> /l	7	13.9	4-13	Globulin g/dl	2.6	2.9-3.2	
Neutrophils %	23	38	10-50				
Lymphocytes %	67	70	40-75				
Monocytes %	1	-	0-6				
Eosinophils %	5	5	0-10				
Basophils %	1	-	0-2				

Key: WBC- White Blood Cell, Hb- Haemoglobin, PCV- Packed Cell Volume

**Table 2:** Clinical pathology result 2 days after blood transfusion

	Haematology	Reference range
PCV %	15	22-39
Hb g/dl	5	8-14
WBC $\times 10^9/l$	7	4-13
Neutrophils %	21	10-50
Lymphocytes %	65	40-75
Monocytes %	1	0-6
Eosinophils %	5	0-10
Basophils %	1	0-2

Key: WBC- White Blood Cell, Hb- Haemoglobin, PCV- Packed Cell Volume

### Results and Discussion

Clinical examination revealed a puffy face and submandibular edema; probably due to hypoproteinaemia particularly hypoalbuminaemia (Table 1) as a result of continuous sucking of blood and the hemorrhagic gastritis caused by the adult parasites. Furthermore, disruption in the integrity of the abomasal mucosa might have also caused been caused by an increase in the globulin level due to acute phase proteins produced as a result of injury to the abomasal mucosa. Increase in globulin level as reported by Murata (2004) causes a reduction in albumin production by the liver. Furthermore, Holmes (1987) reported that, reduced energy and protein metabolism, coupled with anemia in severe cases of haemonchosis are accompanied by hypoproteinemia and edema.

There was a continuous drop in PCV and Hb values through days 1- 3 (Table 1) of clinical investigation of this goat which is a typical sign of infestation by *Haemonchus* parasites. This may have resulted owing to continuous loss of blood along with iron and protein due to invasion of the abomasum with the fourth stage larvae and the adult worms resulting in a non-regenerative anemia (Bastianetto *et al.*, 2011). Furthermore, the parasite is capable of releasing hemolytic factors that may have resulted in erythrocyte lysis which promotes the anemia (Fetterer & Rhoads, 1998).

In this report, the white blood cell values were within the reference range; this concurs with the reports of Rahman & Collins (1990) where it was stated that infection with *H. contortus* did not lead to significant changes in total white cell counts. Cross matching of the donor and recipient blood

an increase in its permeability resulting in further loss of proteins due to leakage to the gastric lumen (Alba-Hurtado & Munoz-Guzman, 2013).

Another possible reason could be that, the effort by the host for a compensatory re-establishment of normovolemia may have resulted in haemo-dilution. Besides, hypoalbuminemia may also have was not done, this was not necessary because according to reports of Ermilio & Smith (2011), cross-matching of small ruminant blood before transfusion is not of significant clinical value because of the minimal level of agglutinating antibody present in ruminant serum.

The recovered larvae were identified and differentiated at generic level by standard methods as described by Anonymous (1971). Gastro-intestinal nematodes can be controlled by generally decreasing the stocking density of pastures, reducing the contamination of pastures by infective larvae (e.g. pasture rotation), systematic and regular removal of manure from stalls and pens will reduces the risk of infection of housed livestock, and also by using antihelminthics. However, the indiscriminate use of anthelmintics to animals especially by local farmers has led to the appearance of parasite isolates with resistance to the major antiparasitic drug groups (Jackson & Coop, 2000). Due to the marked improvement in the health status and general well-being of the goat, it was discharged 4 days post transfusion. The client was advised to improve the nutritional plane of his animals and deworm them at regular intervals.

### References

- Akerejola OO, Schillhorn Van Veen TW, Njoku CO (1979). Ovine and caprine diseases in Nigeria. A review of economic losses. *Bulletin of Animal Health and Production in Africa*. **27**(1): 65-70.
- Alba-Hurtado F & Munoz-Guzman MA (2013). Immune Responses Associated with Resistance to Haemonchosis in Sheep. *BioMed Research International*, vol. 2013, Article ID 162158, doi:10.1155/2013/162158.
- Allonby EW & Dargie JD (1973). *Helminth Diseases of Cattle, Sheep and Horses in Europe*, (Urquhart GM, Amour J, editors). Glasgow University Press: Robert Maclehose and Company limited. Pp 59-71.
- Anonymous (1971). Manual of Veterinary Parasitology Technique Technical Bulletin, No 18. Ministry of Agriculture and Fisheries and Food. London Pp. 129.
- Bastianetto E, Melo MM & Leite RC (2011). Hemogram of buffaloes (*Bubalus bubalis*)

- wormed and non-wormed by helminthes. *Revista Brasileira de Parasitologia Veterinária*, **18**(2/3): 102-110.
- Callan MB (2010). Red Blood Cell Transfusion in the Dog and Cat. In: *Schalm's Veterinary Hematology* (Weiss DJ, Wardrop KJ, editors). sixth edition. Blackwell Publishing limited USA. Pp 738-743.
- Detweiler G, Gipson T, Merkel RC, Goetsch A & Sahlu T (2008). *Body Condition Scores in Goats*. In: Proceedings, 23rd Annual Goat Field Day, Langston University, Langston, OK. Pages 127-133.
- Divers TJ (2005). Blood component transfusions. *Veterinary Clinics of North America-Food Animal Practice*, **21**(3):615-22.
- Ermilio EM & Smith MC (2011). Treatment of emergency conditions in sheep and goats. *Veterinary Clinics of North America-Food Animal Practice*, **27**(1): 33-45.
- Fetterer RH & Rhoads ML (1998). A haemolytic factor from *Haemonchus contortus* alters erythrocyte morphology. *Veterinary Parasitology*, **80**(1): 37-45.
- Githigia SM, Thamsborg SM, Munyua WK & Maingi N (2001). Impact of gastrointestinal helminths on production in goats in Kenya. *Small Ruminant Research*, **42**(1): 21-29.
- Holmes PH (1987). Pathophysiology of nematode infections. *International Journal of Parasitology*, **17**(2): 443-451.
- Jackson F & Coop RL (2000). The development of anthelmintic resistance in sheep nematodes. *Parasitology*, **120**: S95-S107 **120** (7): S95-S107.
- Mamak N & Aytakin I (2012). Blood Cell – An Overview of studies in haematology. doi.org/10.5772/48332. <http://www.intechopen.com/books/blood-cell-an-overview-of-studies-in-hematology/principles-of-blood-transfusion>, retrieved 27-01-2015
- Mortensen LL, Williamson LH, Terrill TH, Kircher R, Larsen M & Kaplan RM (2003). Evaluation of prevalence and clinical implications of anthelmintic resistance in gastrointestinal nematodes of goats. *Journal of America Veterinary Medical Association*, **23**(4): 495-500.
- Mudge MC (2010). Blood transfusion in large animals. In: *Schalm's Veterinary Hematology*, (Weiss DJ, Wardrop KJ, editors) Sixth edition. Blackwell Publishing limited USA. Pp. 757-761.
- Murata H, Shimada N, Yoshioka M (2004) Current research on acute phase protein in veterinary diagnosis: An overview. *Veterinary Journal*, **168**(1): 28-40.
- Okaiyeto SO, Ajanusi OJ, Sackey AK, Tekdek LB (2010). Changes in some hematological values associated with mixed *Trypanosoma congolense* and *Haemonchus contortus* infection in Yankasa, sheep. *Veterinary Research*, **3**(2): 9-13.
- Rahman WA & Collins GH (1990). Changes in live weight gain, blood constituents and worm egg output in goats artificially infected with a sheep derived strain of *Haemonchus contortus*. *British Veterinary Journal*, **146**(6): 543-550.
- Rowe JB, Nolan JV, De Chaneet' G, Teleni E & Holmes PH (1988). The effect of haemonchosis and blood loss into the abomasums on digestion in sheep. *British Journal of Nutrition*, **59**(1): 125-139.
- Smith MC & Sherman DM (2009). *Goat medicine*. Second edition. Ames (IA): Wiley-Blackwell. Pp. 871.
- Thomas RJ & Ali DA (1983). The effect of *Haemonchus contortus* infection on the pregnant and lactating ewes. *International Journal of Parasitology*, **13**(4): 393-398.
- Weingart C, Giger U & Kohn B (2004). Whole blood transfusions in 91 cats: a clinical evaluation. *Journal of Feline Medicine and Surgery*. **6**(3): 139-148.