



## Multiple spinal curvatures in a captive African dwarf crocodile *Osteolaemus tetraspis* (Cope, 1861)

A Olatunji-Akioye<sup>1\*</sup> & P Otuh<sup>2</sup>

1. Department of Veterinary Surgery and Reproduction, University of Ibadan, Nigeria
2. Veterinary Teaching Hospital, University of Ibadan, Nigeria

\*Correspondence: Tel.: +2348034091407, E-mail: bonik2001@yahoo.com

### Abstract

A 4 year old African dwarf crocodile that had been domiciled at the Zoological Gardens, University of Ibadan for 2 years was presented with a history of anorexia of two weeks' duration and reluctance to move for about a week prior to presentation. Physical examination revealed body curvatures and radiography was requested. Dorsoventral, ventrodorsal and left lateral views were done and these revealed multiple curvatures of the cervical, thoracic and caudal vertebrae. There appeared to be a generalized reduction in bone density although there were no visible fractures. There was a lateral compression of the right lung and a downward displacement of the cardiac silhouette. There were also several mineral opacities within the stomach which are suspected to be stones. Metabolic Bone Disease is a non-infectious disease common to reptiles in captivity. It is a consequence of improper diet and husbandry. A diet of flesh without bone or calcium supplements can cause an imbalance leading to the signs and symptoms seen. This can also be worsened by lack of, or insufficient, Vitamin D. It has severe effects in young animals as they require a higher nutritional plane to meet growth requirements. It is essential that reptiles in captivity receive calcium supplementation to maintain calcium: phosphorus balance and adequate exposure to sunlight or artificial ultraviolet light to encourage the synthesis of Vitamin D in the skin. These will prevent the production of parathyroid hormone which causes bone resorption and leads to swollen misshapen bones, fractures, twisting of the spine and kidney damage.

**Keywords:** African dwarf crocodile, Metabolic bone disease, Radiography, Spinal curvatures.

Received: 01-04- 2015

Accepted: 20-08-2015

### Introduction

Metabolic Bone Disease is one of the conditions which make up Nutritional Bone Disease in captive crocodiles underscoring the importance of nutrition in their healthcare. The other conditions which occur in this species include osteomalacia, rickets, secondary hyperparathyroidism, osteoporosis and fibrous osteodystrophy (Huchzermeyer, 2003).

The most common cause of MBD in young crocodiles is feeding red meat without bone or with an insufficient calcium supplement. This may be aggravated by a lack of Vitamin D if the crocodile is housed indoors (Tricia, 2015).

There are reports of weakness and sluggishness in hatchlings and an inability to walk on land although they can still swim. Contractions of the long back muscles cause distortions of the vertebral column leading to kyphoscoliosis (Cardeilhac, 1981). In older juveniles, with less pliant vertebrae, fractures occur due to seizures caused by hypocalcaemia leading to posterior paralysis (Foggin, 1987).

The ideal calcium: phosphorus in the diet is 1:5 or 2:1 whereas viscera and muscle meat without bone have calcium: phosphorus of about 1:12 (Jacobsen, 1982).

The African Dwarf crocodile *Osteolaemus tetraspis* has two subspecies; the *Osteolaemus\_tetraspis tetraspis* (the West African dwarf crocodile) and *Osteolaemus\_tetraspis osbornis* (the Congo dwarf crocodile). *Osteolaemus* means "bony throat", derived from *osteon* (Greek for "bone") + *laimos* (Greek for "throat"); referring to the extensive osteoderms (bony plates) found in the neck and belly scales" (Britton, 2015).

It is primarily found in permanent pools in swamps and areas of slow-moving freshwater in rain forests. The ecology of this species is similar to the New World *Paleosuchus* dwarf caimans. They can grow up to 1.9 meters in length and weigh as much as 40kg for females and 80kg for males (Wikipedia). They feed on fish, amphibians, crustaceans, and possibly other terrestrial prey (Britton, 2015).

#### Case report

The crocodile aged 4 years was acquired by the zoo at an estimated 2 years of age. There were 2 crocodiles of about the same age acquired at the same period. Upon acquisition, the crocodiles were healthy and certified normal. About two weeks before presentation to the small animal clinic of the

Veterinary Teaching Hospital, University of Ibadan, this crocodile developed anorexia and was observed to be immobile/ reluctant to move despite several attempts to coax it with food. Upon presentation, two curvatures of the spine were observed at the cervical, thoracic and lumbar regions of the spine (Plate I). Radiography was requested and revealed two areas of 'S' curvature of the spine at the level of the cervical and thoracic as well as the caudal vertebrae (Plate II). There appears to be a generalized reduction in bone density of the vertebrae but no fractures were seen. The curvatures appear to have resulted in a ventral deviation of the trachea, compression of the right lung and a downward depression of the cardiac silhouette. There are also several lytic lesions observed on a few of the lumbar vertebrae and the kidneys appear swollen (see Plate III). There appear to be several mineral opacities within the stomach which are likely to be stones which is normal in this specie (Plate IV). A generalized reduction in long bone density was also observed which suggests metabolic bone disease although there were no visible fractures.




Plate I: African dwarf crocodile being coaxed to move with food

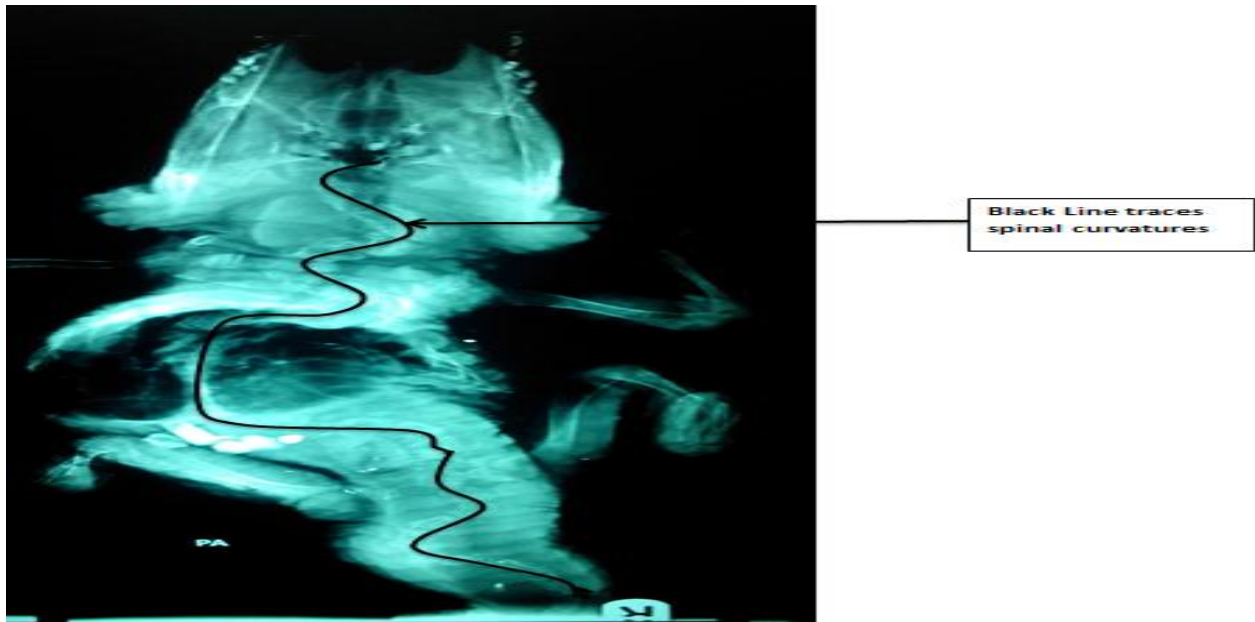


Plate II: Dorsoventral radiograph of African dwarf crocodile (black line traces multiple spine curvatures)

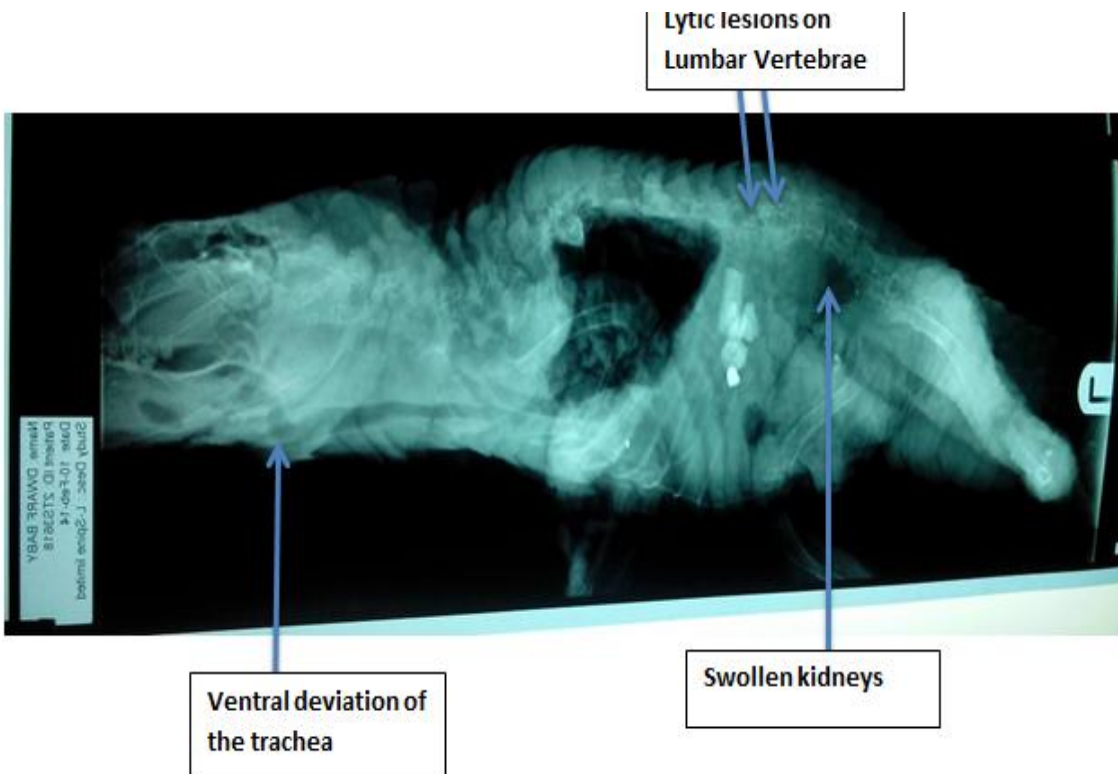
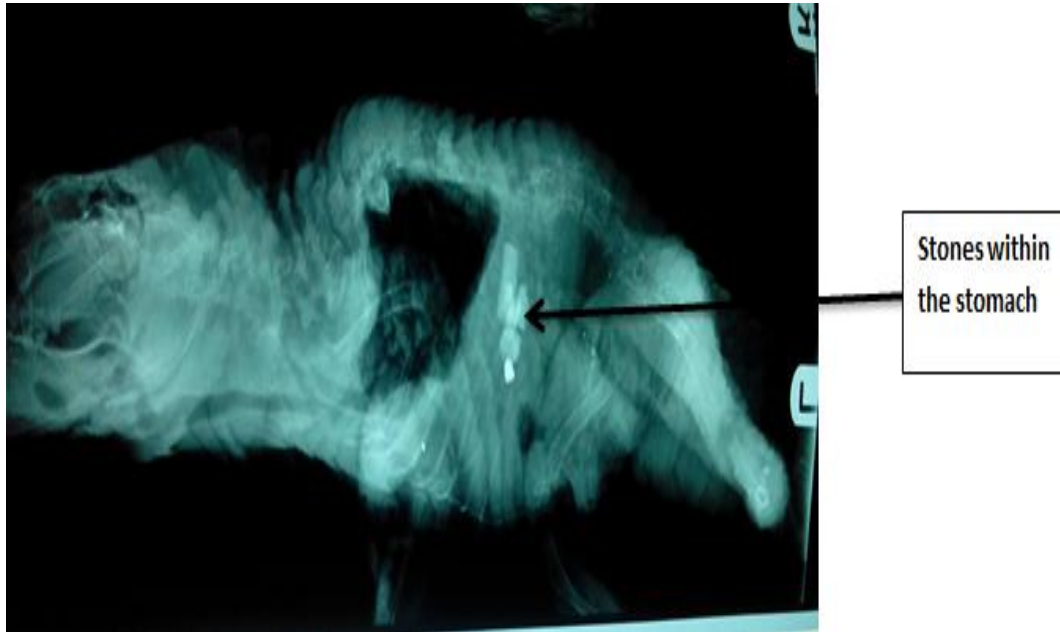


Plate III: Lateral radiograph of African dwarf crocodile

### Discussion

Metabolic bone disease is a group of bone diseases caused by abnormal calcium metabolism. Several possible causes have been listed by Cardeilhac (1981). Usually, MBD is caused by shortage of calcium in captive crocodiles. Calcium deficiency is to be expected if crocodiles are fed boneless meat and

not given access to sunlight. Crocodiles in captivity require supplementation of calcium to enable them meet their calcium requirements. There is also a need to regulate the Calcium: Phosphorus ratio to prevent the resorption of calcium from bones.



**Plate IV:** Lateral radiograph of African dwarf crocodile

Symptoms of MBD include visible abnormalities of the skeleton.

This crocodile was probably wrongly aged at the time of acquisition and may not have been up to two years old at the time. This may be the reason for the physical manifestation of inadequate calcium needs as younger crocodiles will usually require an increased supplementation of calcium for their growth requirements.

It is essential that zoo keepers and handlers are aware of the mechanism of bone loss which results when the calcium: phosphorus ratio is inadequate or when there is an insufficiency of Vitamin D. When gross imbalances in the calcium: phosphorus ratio exist, the relatively insoluble salt, calcium phosphate (which is minimally absorbed from the gut), is favoured within the intestine. Excess phosphate ion can be absorbed thus resulting in hyperphosphatemia. The parathyroid glands are stimulated to secrete parathormone, thus inducing the leaching of calcium from the hydroxyapatite crystals in the mature bone matrix. As reabsorption continues, the bone is weakened and, concomitantly, it is partially replaced by

fibrocollagenous connective tissue (Jacobsen, 1982; Tricia 2015). Affected bones tend to be larger in diameter with irregular outlines and a characteristically spongy consistency. Radiographs demonstrate normal medullary cavities surrounded by massively expanded cortical bone of greatly diminished radio-density. These bones are deformed easily, and pathological fractures of weight-bearing long bones and vertebrae are common sequelae to this disorder. Ingestion of excessive dietary calcium ion products (with respect to phosphorus) is possible, but very unusual. When it does occur, the parafollicular cells or "C" cells of the thyroid gland(s) and ultimobranchial bodies are stimulated to secrete a hormone like substance, calcitonin, which acts to inhibit calcium ion resorption from hydroxyapatite which is antagonistic to the action of parathormone and, thus, reduces plasma calcium levels (Tricia, 2015).

#### **Acknowledgement**

The authors would like to acknowledge the Zoological Garden, University of Ibadan and members of staff for invaluable assistance with handling of this case and record-keeping.

## References

- Britton A (2015) Health care. [http://crocodilian.com/cnhc/csp\\_otet.htm](http://crocodilian.com/cnhc/csp_otet.htm), retrieved on 2015-03-04.
- Cardeilhac P (1981) Nutritional Disorders of Alligators. *Paper Presented at the First Annual Alligator Production Conference*. University of Florida. Pp 58-63.
- Foggin CM (1987) Diseases and disease control on crocodile farms in Zimbabwe. In: *Wildlife Management (Webb GJW, Manolis SC & Whitehead PJ, editors) crocodiles and alligators*. Surrey Beatty and Sons, Chipping Norton, New South Wales, Australia. Pp 351–362.
- Huchzermeyer FW (2003). Non transmissible diseases. In: *Crocodiles: Biology, Husbandry and Diseases*. CABI Publishing, UK. Pp 211-216.
- Jacobsen ER (1982). Captive Health Problems. Prepared for Government of India Crocodile Breeding and Management Project. Field Document No. 11. FAO/IND/74/046. Pp 23.
- Tricia's Chinese Water dragon Reptile and Amphibian care page (2015) Calcium deficiency. <http://www.triciaswaterdragon.com/calciudemdeficiency.htm>, retrieved on 02-03-2015.
- Wikipedia (2015). Dwarf Crocodile. [http://en.wikipedia.org/wiki/Dwarf\\_crocodile](http://en.wikipedia.org/wiki/Dwarf_crocodile), retrieved on 02-03-2015.