

Sokoto Journal of Veterinary Sciences



(P-ISSN 1595-093X: E-ISSN 2315-6201)

<http://dx.doi.org/10.4314/sokjvs.v20i5.18>



Ahmadu *et al.*/Sokoto Journal of Veterinary Sciences, 20(Special): 164 – 171.

Prevalence of hydatid cyst in camels slaughtered at Katsina metropolitan abattoir, Katsina State, Nigeria

AM Ahmadu¹, MA Saulawa², AA Magaji³, AI Musawa³, K Ibrahim⁴ & KH Ahmad^{5*}

^{1.} Department of Livestock and Grazing Reserve, Ministry of Agriculture, Katsina State

^{2.} Veterinary Council of Nigeria VCN, Maitama, FCT Abuja, Nigeria

^{3.} Department of Veterinary Public Health and Preventive Medicine, Usmanu Danfodiyo University, Sokoto, Nigeria

^{4.} Department of Agriculture and Natural Resources, Katsina Local Government Area, Katsina State

^{5.} Department of Veterinary Microbiology, Ahmadu Bello University, Zaria, Nigeria

*Correspondence: Tel.: +2348036395435; E-mail: kabirbka@gmail.com

Copyright: © 2022

Ahmadu *et al.* This is an open-access article published under the terms of the Creative Commons Attribution License which permits unrestricted use, distribution, and reproduction in any medium, provided the original author and source are credited.

Publication History:

Received: 21-12-2021

Revised: 28-03-2022

Accepted: 29-04-2022

Keywords: Abattoir, Camels, Hydatid cysts, Katsina, Nigeria, Prevalence

Abstract

Cystic *Echinococcosis*, among other food animal zoonotic diseases, heralds a significant zoonotic threat to meat consumers due to the lack of stringent meat inspection policies and poor awareness of zoonoses by most livestock traders/butchers. Therefore, this study is aimed at determining the prevalence of *hydatid cysts* in camels slaughtered at katsina metropolitan abattoir, Katsina State, Nigeria. A total of 392 samples were collected over three months (November 2019 to January 2020), of which 129 samples were from males and 263 from females. Information about the age, sex and body condition of the slaughtered camels were recorded. The carcass of each camel was inspected carefully for the presence of *Hydatid cysts*, the organs infected, and the number of cysts present. The data were subjected to statistical analysis using the Chi-square test (χ^2), and significant levels were determined at $p < 0.05$ level for all the data, which revealed an overall prevalence of 14.0% (55/392). The prevalence rate of *Hydatid cysts* was 16.3% in females and 9.3% in males, while it is 16.8 and 5.3% in adult and young camels, respectively. We recommend a holistic epidemiological study on the prevalence of hydatid cysts in camels and more public enlightenment for effective control measures against the disease in Katsina State.

Introduction

Hydatidosis is a major parasitic disease affecting camels with great economic and public health significance (Lahmar *et al.*, 2004) and becoming more endemic in many developing countries, including Nigeria (Azlaf & Dakkak, 2006; Getaw *et al.*, 2010). The low level of education that is characteristic of most livestock owners in such countries makes them

ill-equipped to take appropriate actions to control livestock diseases and even annual herd health management programs, thus preventing these owners from successfully controlling diseases (Kaltungo *et al.*, 2013; Buhari, 2014). Lack of stringent meat inspection policies and poor knowledge on zoonoses, as it is the attitudes of the livestock

traders/butchers through the purchase of obviously sick or lower grade animals for human consumption portends a significant zoonotic threat to the consumers, and are probably partly responsible for the high incidences of tuberculosis, brucellosis, *cysticercosis*, *fascioliasis* and *taeniasis* reported in humans across Nigeria (Kaltungo *et al.*, 2013; Buhari, 2014; Yakubu, 2016).

Camel production in Nigeria is concentrated in the semi-arid northern part of the country (Mohammed, 2000). Pastoral groups from the Niger Republic own most of the camels in northern Nigeria (Waziri *et al.*, 1999). They are the main breeders of the camel (Mohammed & Hoffmann, 2006) and can be found in Borno, Yobe, Kano, Jigawa, Katsina, Sokoto, Kebbi and Zamfara States of Northern Nigeria. The farmers also keep dogs that help in the herding of their livestock and guard at night. During herding, livestock interacts with wild canids and herbivores, which in the process may lead to transmission of the disease (Layla & Wahab, 2015). These farmers obtain water for domestic use from the numerous streams originating from Fadama areas which are also grazing grounds for livestock. The water is usually contaminated especially during the rainy season when wild animals' faeces and livestock dung are washed into water bodies (Cabral, 2010). These faeces may contain infective eggs, which are transmitted into water bodies. The infective eggs in these water bodies may find their way into people's homes as they come to

fetch water for domestic use. The public health and economic significance of *hydatidosis* lie in the cost of hospitalization, medical and surgical treatment, loss of income and productivity due to permanent or temporary incapacitation to work. In food animals, *hydatidosis* has adverse effects on production, causing decreased production of meat, milk and wool, reduction in growth rate, and predisposition to other diseases (Kebede *et al.*, 2011). The presence of *Hydatid cysts* in commercial viscera is a main source of seizures during meat inspection, and it is responsible for great economic losses in animal husbandry (Regessa *et al.*, 2010).

Therefore, this study was undertaken to determine the status of *hydatidosis* in camels (*Camelus dromedaries*) slaughtered at Katsina Metropolitan Abattoir, Katsina State, Northwestern Nigeria.

Materials and Methods

Study design

The study was an active Abattoir survey to determine the prevalence of *Hydatid cysts* in camels slaughtered at Katsina Metropolitan Abattoir. An average of seven camels were slaughtered on daily basis at the abattoir. Therefore, all camels registered for slaughter during the study period were included in the study, because of the small number. The study was carried out within three (3) months (November, 2019 – February, 2020). Sample size was calculated using Thrusfield formula of 2005: $n = Z^2pq/d^2$ and

Prevalence of 8.97% was used to calculate the sample size as reported by Abdullahi *et al.* (2011).

Study area

Katsina State is one of the 36 states in the Federal Republic of Nigeria and it lies between latitude 11°49'N and 16°59'N and longitude 6° 30'W and 9° 40'E within the semi-arid Sudan savannah zone of West Africa (Figure 1). Katsina State is made up of 34 Local Government Areas (KTARDA, 2009). It shares boundaries with Niger Republic in the North, East with Kano and Jigawa States respectively, West with Zamfara State, and South with Kaduna State. The total land area of Katsina State is 23,938 sq kilometers (KTARDA, 2009).

The human population of Katsina State is 5,792,578 (NPC, 2006). The main occupation of the people in the state is

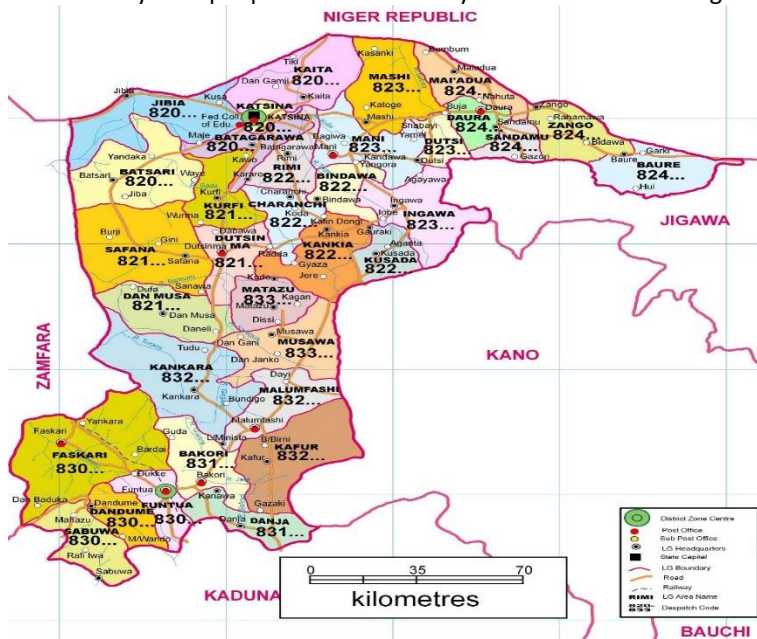


Figure 1: Map of Katsina State with its Local Governments, Katsina Metropolitan shaded.

Source: KTARDA (2009)

predominantly agriculture, producing subsistence crops like sorghum, millet, maize, cow pea and groundnuts, while the State drives hides and skin among other livestock products and by-products (KSIH, 2016). The main ethnic groups are Hausa and Fulani.

There are estimated figures of 3.6 million goats and 2.4 million sheep. It is common to find all livestock species in every Local Government of the State (KSIH, 2016). Katsina State has two seasons, with the dry season being from September to April or May, while the rainy season comes between May and August each year. The average annual rainfall varies between 400mm and 800mm (North-South), and a mean annual temperature is 31.75°C (KTARDA, 2009).

Target population

The study was carried out considering male and female camels; adult and young of greater than 3 years and less than a year, respectively. Prior to sample collection, approval was sought from the Metropolitan Abattoir management.

Inclusion criteria: All camels presented for slaughter during the study period were recruited in the study because of the small number, an average of seven camels were slaughtered daily at the Abattoir.

Sample collection

The Katsina Metropolitan Abattoir that serves Katsina town and neighbouring villages with meat is a key facility for the slaughter of animals and was visited on slaughter days. The antemortem and post-mortem inspections were carried out following the procedures of Mitchell (1980). The information concerning the slaughtered camels' age, sex and body condition was recorded. The age of the sampled animals was also determined by the dental eruption technique (Kohler-Rollefson *et al.*, 2001; Khan *et al.*, 2003). During post-mortem examination, the visceral organs (liver, lung, heart, spleen, kidney, other viscera and tissues) were inspected by palpation and incision of each slaughtered animal (Mitchell, 1980). The number of cysts and the organ from which the cysts were recovered were also recorded systematically, while the cysts for each camel were collected in a clean plastic bag for close examination in the Katsina Veterinary Clinic and Diagnostic Laboratory located at Katsina Zonal Veterinary Clinic Kofar Kwaya, Katsina State to confirm the doubtful cases immediately. The polythene bags were labeled according to date and number of samples for the camel, while details as to sex, age, body condition and other data on the camels were recorded in a log book used during data collation and presentation.

Laboratory investigations

Individual cysts were carefully incised and one drop of each hydatid fluid was placed on a glass slide and covered with a cover slip. The slide was examined under the light microscope using the objective lens X40 for protoscoleces and was characterized. Fertile cysts had whitish dots on the germinal epithelium, while infertile cysts were further classified as sterile or calcified. Sterile *Hydatid cysts* were further characterized by the presence of a smooth inner lining, usually with slightly turbid fluid in its content, while calcified cysts produce a gritty sound feeling up on incision (Soulsby, 1982; Kebede *et al.*, 2009a).

Statistical analysis

The data obtained from the study were presented in Tables. Differences between independent variables (breed, sex and age group) were subjected to descriptive statistics using Microsoft Excel spreadsheet. Test for significance between categorical variables was obtained by employing Chi-square using SPSS 20.0 software (IBM, 2011) statistical package. A *p*-value <0.05 was considered statistical significance for all data. Overall infection rate of cystic *Echinococcosis* in the area was calculated using the following formula:

$$\text{Prevalence (\%)} = \frac{\text{Number of infected camels}}{\text{Total number of sampled camels}} \times 100$$

Results

A total of 392 camels were sampled during this study. Among them were 129 (32.9%) males and 263 (69.1%) females. Also, adult and young ones were 297 (75.8%) and 95 (24.2%) respectively. The findings of this study indicated camels sampled were found to be harboring *Hydatid cysts* in their different visceral organs. This study has established the overall prevalence of infected camels with hydatid cysts to be 14.0% (55/392). Sex-specific prevalence of *Hydatid cysts* in slaughtered camels in Katsina Metropolitan abattoir shows that 12 (9.3%) of the 129 male camels were found to be harbouring *Hydatid cysts*. Similarly, of the 263 female camels sampled, 43 (16.3%) also had *Hydatid cysts* (Table 1).

Similarly, the age-specific prevalence of *Hydatid cysts* in slaughtered camels in Katsina Metropolitan Abattoir revealed that out of the 297 adults sampled, 50 (16.8%) were found to harbour *Hydatid cysts*, while of the 95 young camels, 5 (5.3%) were infected with *Hydatid cysts* (Table 2).

The distribution of *Hydatid cysts* in the organs of infected camels slaughtered at Katsina Metropolitan

Abattoir indicated that 55 camels were harboring the *Hydatid cysts*, 40 (72.7%) were found to have the cysts in their lungs, 4 (7.3%) was involved with the liver, while 11 (20%) had cysts in two organs (lungs and liver) respectively (Table 3). The total cyst counts with respect to organs involvement were 164 (71.9%) in the lungs, 13 (5.7%) in the liver and 51 (22.4%) in both lungs and liver respectively (Table 3). No cysts were found in the kidney, spleen, and mesentery.

The distribution of fertile, sterile, and calcified *Hydatid cysts* in different organs of camels slaughtered at Katsina metropolitan abattoir revealed infection of organs, fertility, and calcification of the cysts, with 64 cysts in a single encounter and 35 cysts involved in double organ infection of some of the camels. This made the total number of lungs with cysts to be 199. The number of livers with single infection was 13, while 16 others were found with double infections with cysts making the total number of livers with cysts to be 29. Thus, the total number of organs (lungs and livers) with cysts was 228. Of the 199 cysts recovered from lungs, 180 (90.5%) were fertile, while 13 (6.5%) were sterile and 6 (3.0%) were calcified. Moreover, of the 29 liver samples with cysts, 19 (65.5%) had fertile cysts while 6 (20.7%) and 4

(13.8%) had sterile and calcified cysts respectively (Table 4). This gives a total of fertile cysts as 199 (87.3%), sterile cysts as 19 (8.4%) and calcified cysts as 10 (4.4%).

Discussion

The one-humped camel (*Camelus dromedarius*) was found in the study area as reported by Abullahi *et al.* (2011). The camels seen in the study area are mostly from Niger Republic (Waziri *et al.*, 1999). The study has shown that some of the camels (14.0%) being slaughtered at the Katsina metropolitan abattoir were infected with cystic *Echinococcus*. This is possible as these animals are known to be versatile and opportunistic feeders on course and bulky perennial grasses (Ajogi *et al.*, 1995). This prevalence rate poses a worrisome situation as there is the risk of infecting camel meat consumers with the disease, and there is also the high possibility of other animals in the neighbourhood of the abattoir becoming infected as a result of the poor management practices in our abattoirs leading to flow of abattoir waste into streams that supply livestock grazing areas, as reported by Lawan *et al.* (2010).

Table 1: Sex specific prevalence of *Hydatid cysts* in slaughtered camels at Katsina Metropolitan Abattoir, Katsina State

| Sex of Camel | No. of Camels Examined | No. of Camel Infected | Specific Prevalence (%) |
|--------------|------------------------|-----------------------|-------------------------|
| Male | 129 | 12 | 9.3 |
| Female | 263 | 43 | 16.3 |
| Total | 392 | 55 | 14.0 |

$$\chi^2 = 3.564, df = 1, p = 0.0590$$

Table 2: Prevalence of *hydatid cysts* based on age in slaughtered camel at Katsina Metropolitan Abattoir, Katsina State

| Age | No. of Camels Examined | No. of positive | Specific prevalence |
|-------------------|------------------------|-----------------|---------------------|
| Adult (> 3 years) | 297 | 50 | 16.8% |
| Young (< 3 years) | 95 | 5 | 5.3% |
| Total | 392 | 55 | 14.0% |

$$\chi^2 = 5.824, df = 1, p = 0.0180$$

Table 3: Distribution of *Hydatid cysts* in the organs of infected camels slaughtered at Katsina metropolitan Abattoir, Katsina State

| Organs | N. infected organs | No. of cysts count |
|-----------------|--------------------|--------------------|
| Lungs | 40 (72.7%) | 164 (71.9%) |
| Liver | 4 (7.3%) | 13 (5.7%) |
| Lungs and Liver | 11 (20.0%) | 51 (22.4%) |
| Spleen | 0 (0.0%) | 0 (0.0%) |
| Kidneys | 0 (0.0%) | 0 (0.0%) |
| Mesentery | 0 (0.0%) | 0 (0.0%) |
| Total | 55 | 228 |

$$\chi^2 = 35.745, df = 2, p = 0.000$$

Table 4: Distribution of fertile, sterile and calcified *hydatid cysts* in different organs of infected camels slaughtered at Katsina metropolitan Abattoir, Katsina State

| Organ involved | No. of cysts examined | Cyst condition | | |
|----------------|-----------------------|----------------|-----------|-----------|
| | | Fertile | Sterile | Calcified |
| Lungs | 199 | 180 (90.5%) | 13 (6.5%) | 6 (3.0%) |
| Liver | 29 | 19 (65.5%) | 6 (20.7%) | 4 (13.8%) |
| Spleen | 0 | 0 (0.0%) | 0 (0.0%) | 0 (0.0%) |
| Kidneys | 0 | 0 (0.0%) | 0 (0.0%) | 0 (0.0%) |
| Mesentery | 0 | 0 (0.0%) | 0 (0.0%) | 0 (0.0%) |
| Total | 228 | 199 (87.3%) | 19 (8.4%) | 10 (4.4%) |

$$\chi^2 = 14.595, df = 2, p = 0.0001$$

Many reports all over the world have indicated different prevalence rates of *hydatidosis* in camels. In this study, the prevalence was 14.0% which is higher than the 1.73% reported by Igwenagu *et al.* (2018) at the Maiduguri abattoir. Similarly, Abdullahi *et al.* (2011), in a retrospective study also reported a prevalence of 8.97% (n = 3545) in camels slaughtered at Sokoto central abattoir, which is also lower than that obtained in this study. In another study, Ogunsan *et al.* (2000) reported a prevalence of 26.2% at the Sokoto abattoir while Rabi'u & Jegede (2010) reported a prevalence of 20.5% in camels slaughtered in the Kano abattoir. These variations in prevalence could be due to variations in temperature, environmental conditions and the number of stray dogs as well as other in-contact animals in the respective areas. As an area becomes dry and hot, the survival of *Echinococcus* will be less likely. Hence the prevalence of *hydatidosis* could increase in areas where the intermediate hosts such as camels exist. In addition, slaughterhouses dispose of offal in shallow pits giving dogs easy access to them. Lawan *et al.* (2010), and Yakubu (2016), among others, have independently reported dogs frequenting slaughterhouses in their study areas.

The prevalence of *hydatid cysts* in the study camels by sex is higher in females than in males. This is believed to be a result of the preference of camel owners to sell more females, particularly old ones. Similar high prevalence rates in females have been reported by Tashani *et al.* (2002) and Ibrahim (2010). Another reason could be that female camel were more retained in a herd than males, thus getting them exposed to infections many times. The fact that female animals are under severe stress due to pregnancy, which can make them immunologically compromised, could also account for the higher prevalence in females than males.

From the study, there was a statistically significant difference in the prevalence of *hydatid cysts* among adults and young camels in the study area. It is

believed that older animals were exposed to the disease (parasitic ova) over a long period with an increasing possibility of acquiring and sustaining infections. This age-related difference in prevalence is also associated with older animals having a greater chance of ingesting larger numbers of *E. granulosus* eggs and the cyst being likely to increase in size and become matured in this long-lived host (Ahmed, 1991; Ibrahem & Craig, 1998; Larriue *et al.*, 2001). This could also be the reason, higher age reflects a much longer period of risk of infection, it is also easy to detect cysts at meat inspection in older animals due to their bigger sizes and also because older animal cysts have more time to enlarge and pass on cysts to other organs.

This study found that the presence of *Hydatid cysts* in the sampled camels was predominant in the lungs and liver. This is in fundamental agreement with the literature, which states that *hydatid cysts* are most commonly found in the lungs and liver of ungulates (Soulsby, 1982; Urguhart *et al.*, 1988; Getaw *et al.*, 2010; Ibrahim, 2010). This is explained in the light of the fact that lungs and liver possess great capillaries in which the migrating *Echinococcus* oncospheres (hexacanth embryo) adopt the portal vein route and primarily negotiate hepatic and pulmonary filtering system sequentially before any other peripheral involvement (Kebede *et al.* 2009b). Previous studies have reported that 68 – 98% *E. granulosus* cyst occurs in the lungs in camels, whereas cysts in the liver were much less frequent, with 20 – 32% prevalence (Hamdy *et al.*, 1980). This could be that the tissues of the camel's liver are tough and solid, making it difficult for the oncosphere to grow normally, whereas the lung tissue is smoother and softer, making it easier for the oncosphere to grow faster.

The present study has shown that as many as 20 cysts were recovered from a single lung. This number is fewer than those reported by Ibrahem & Craig (1998) where 25 cysts were recovered from a single lung of camel and higher than those reported by Layla &

Wahab (2015). These variations in cyst abundance could be due to the spatial distribution and the infectivity (biotic potential) of *E. granulosus* eggs, susceptibility and defensive capabilities of the host (Macpherson *et al.*, 1985). It could also have something to do with the longevity of infection with the organisms as well as the amount of exposure of the camels by the parasites in given areas.

In this study, a total of 228 cysts were recovered from the camels, out of which 199 cysts were found to be fertile which means they can cause infection in other susceptible animals and humans. This indicates a potential risk of infection for other animals should they graze in the same vicinity as these camels. Kaltungo (2018) and Kaltungo *et al.* (2019) in a study on brucellosis in camels in Sokoto and Katsina States reported camels grazing and taking water in the same locations as cattle. The finding of sterile and calcified cysts could indicate long-standing of these cysts in the camels. It could also indicate a possible effect of drugs that the camels might have been treated within the efforts of the owners to deworm them against helminth parasites. Kaltungo (2018), Baba (2019) and Buhari *et al.* (2020) all reported livestock owners treating their animals against various diseases, especially through the use of plants.

In the present study, it was observed that the lung cysts in camels were more fertile (90.5%) than those in the liver (65.5%). This may be due to the relatively softer consistency of lung tissue which could allow easier development of the cyst, and the fertility rate of *hydatid cysts* may show a tendency to increase with the advancing age of the host (Himonas *et al.*, 1987). The result of this study was also in agreement with the report of Ahmadi (2005), who demonstrated that the fertility of the cyst from lungs was 69.7% as compared to 58.7% from liver in slaughtered camel in five different abattoirs in Iran. Sterile *hydatid cysts* were noticed as early as 1928 by Dew. He stated that the sterility of the acephalo-cyst might be due to the inherent inability to reproduce, but in the majority of cases, it was due to some abnormal local conditions. He added that the availability of nourishment was probably the most important factor and was influenced by the location of the parasite and the condition of the adventitious coat. Sterile *hydatid cysts* may also be due to infection by an unspecific strain.

In conclusion, camels in the study area were infected with *hydatid cysts* with an overall prevalence of 14.0%. The prevalence rate of *hydatid cysts* in female camels was 16.3% and 9.3% in male camels, while the prevalence rate of *hydatid cysts* in adult camels was

16.8% and 5.3% in young camels. Organ involvement with *hydatid cysts* includes 71.9% in the lungs, 5.7% in the liver and 22.4% found in both the lungs and the liver at the same time, with the kidneys, spleen and mesentery not being involved.

There is a need to conduct more holistic epidemiological studies on the prevalence of *hydatid cysts* of camels in Katsina State to understand the true situation of *hydatidosis* in the State, as well as efficient meat inspection services in Katsina State to effectively control the disease in the State. More public enlightenment on *hydatidosis* in Katsina State to encourage livestock owners to actively participate in diseases control programmes is advocated, as well as treatment of infected dogs with anti-helminthic drugs such as albendazole, mebendazole and praziquantel.

Conflict of interest

The authors declare that there is no conflict of interest.

References

- Abdullahi AM, Oboegbulem SL, Daneji AL, Garba HS, Salihu MD, Junaidu AU, Mohammed AA, Lawal M, Aminu S, Yakubu Y & Mamuda A (2011). Incidence of hydatid cyst disease in food animals slaughtered at Sokoto central abattoir, Sokoto state, Nigeria. *Veterinary World*, **4**(5): 197-200.
- Ahmadi NA (2005). *Hydatidosis* in camel (*Camelus dromedarius*) and their potential role in the epidemiology of *Echinococcus granulosus*. *Iran Journal of Helminthology*, **79**(2): 119-125.
- Ahmed L (1991). Incidence of hydatid disease in camel slaughtered at Assiut abattoir. *Assiut Veterinary Medical Journal*, **24**: 274 – 278.
- Ajogi I, Uko UE & Tahir FA (1995). A retrospective (1990-1992) study of tuberculosis, cysticercosis and *hydatidosis* in food animals slaughtered in Sokoto abattoir Nigeria. *Tropical Veterinarian*, **13** (3 & 4): 81 – 85.
- Azlaf R & Dakkak A (2006) Epidemiological study of the cystic *echinococcosis* in Morocco. *Veterinary Parasitology*, **137**(1-2): 83-93.
- Baba AY (2019). Clinico-epidemiological Studies of Brucellosis in Horses in Kano Metropolis, Kano State, Nigeria. PhD Thesis, Department of Veterinary Medicine, Faculty of Veterinary Medicine, Ahmadu Bello University, Zaria, Nigeria. Pp 17-42.

- Buhari HU (2014). Survey of Bovine Brucellosis in the North Senatorial District of Kaduna State, Nigeria. MSc Dissertation, Ahmadu Bello University, Zaria. Pp 1-111.
- Buhari HU, Saidu SNA, Kudi CA, Okolocha EC & Kaltungo BY (2020). Seroprevalence of Brucella infection in Small Ruminants from two Institutional Farms and a Slaughter Slab in Zaria, Nigeria. *Sokoto Journal of Veterinary Sciences*, **18**(2): 91-99.
- Cabral JPS (2010). Water Microbiology. Bacterial Pathogens and Water. *International Journal of Environmental Research and Public Health*, **7**(10): 3657-3703.
- Dakkak A (2010). *Echinococcosis/Hydatidosis*: A serve threat in mediterranean countries. *Veterinary Parasitology*, **174**(1-2): 2-11.
- Getaw A, Beyene D, Ayana D, Megersa B & Abunna F (2010). *Hydatidosis*: Prevalence and economic importance in ruminants slaughtered at Adama Municipal abattoir, central Oromia, Ethiopia. *Acta Tropica*, **113**(3): 221-225.
- Hamdy I, Mikhail E, Soliman A & Hamed H (1980). A study of hydatidosis in some animals in Egypt. *Journal of Egypt Society of Parasitology*, **10**(1): 43-51.
- Himonas C Frydas S & Antoniadou-Sotiriadou K (1987). The Fertility of Hydatid cysts in Food Animals in Greece. In: Helminth Zoonoses. Current Tropics in Veterinary Medicine and Animal Sciences (S Geert, V Kumar, J Brandt, editors) Martinus Nijhoff Publishers, Dordrecht Netherlands. Pp 12-21.
- IBM SPSS Statistics. 20 (2011). IBM Corporation, 1 New Orchard Road Armonk, New York City, USA.
- Ibrahim M & Craig P (1998). Prevalence of cystic *Echinococcosis* in Libya. *Journal of Helminthology*, **72**(1): 27 – 31.
- Ibrahim MM (2010). Study of cystic *Echinococcosis* in slaughtered animals in Al Baha region, Saudi Arabia: Interaction between some biotic and abiotic factors. *Acta Tropica*, **113** (1): 26-33.
- Igwenagu E, Onyiche E, Sa'idu AM, Chachari AM, Waziri A & Kayeri BK (2018). Prevalence of *hydatidosis* and fertility of *hydatid cysts* in slaughtered Camels in Maiduguri, Nigeria. *Ife Journal of Science*, **20** (2): 299-302.
- Kaltungo BY, Saidu SNA, Sackey AKB & Kazeem HM (2013). Serological Evidence of Brucellosis in Goats in Kaduna North Senatorial district of Kaduna State, Nigeria. *ISRN Veterinary Science*, doi.10.1155/2013/963673.ss.
- Kaltungo BY (2018). Serological and Participatory Studies of *Brucella* Infections in Small Ruminants in Katsina and Sokoto States, Nigeria. PhD Thesis, Department of Veterinary Medicine, Faculty of Veterinary Medicine, Ahmadu Bello University, Zaria, Nigeria. Pp 3-63.
- Kaltungo BY, Saidu SNA, Kudi CA, Isma'ila M, Jacob RJ, Salisu U, Baba YA & Buhari HU (2019). Geo-Spatial distribution of *Brucella melitensis* infection in selected local government areas of Katsina and Sokoto States, Nigeria. *Nigerian Veterinary Journal*, **40**(2): 95-103.
- KSIH (Katsina State Investor's Handbook) (2016). Agricultural Sector. In: Investment in Katsina State. Pp 13-17.
- KTARDA (Katsina State Agricultural and Rural Development Authority) (2009). Assessment of waste management and control strategies in Katsina metropolis, Katsina State, Nigeria meteorological data from weather station. *Journal of Research in National Development*, **11** (1): 189-195.
- Kebede M, Mitiku A & Tilahun G (2009a). *Hydatidosis* of slaughtered animals in Bahir Dar Abattoir, North-western Ethiopia. *Tropical Animal Health and Production*, **41**(1): 43-50.
- Kebede N, Gebre-Egziabher Z, Tilahun G & Wossene A (2011). Prevalence and Financial Effects of *Hydatidosis* in Cattle slaughtered in Birre-Sheleko and Dangila Abattoir, North western Ethiopia. *Zoonoses and Public Health*, **58**(1): 4146.
- Kebede N, Mekonnen H, Wossene A & Tilahun G (2009b). *Hydatidosis* of Slaughtered Cattle in Wolaita Sodo Abattoir, Southern Ethiopia. doi.10.1007/s11250-008-9234-2.
- Khan BB, Iqbal A & Riaz M (2003). *Production and Management of Camels*. Department of livestock Management, University of Agriculture, Faisalabad, Pakistan. Pp 152 - 156.
- Kohler-Rollefson I, Mundy P & Mathias E (2001). *A Field Manual of Camel Diseases* (Traditional and Modern Health care for the Dromedary). TDG Publishing, London, United Kingdom. Pp 22 – 25.
- Lahmar S, Debbek H, Zhang LH, MacManus DP, Soussi A, Chelly S & Torgerson PR (2004). Transmission dynamics of the Echinococcus

- granulosus sheep-dog strain (G1 genotype) in camels in Tunisia. *Veterinary Parasitology*, **121**(1-2): 151-156.
- Larrieu E, Costa M, Cantoni G, Alvarez R, Cavagion L, Labanchi J, Bigatti R, Araya D, Herrero E, Alvarez E, Mancini S & Cabrena P (2001). Ovine echynococcus granulosus transmission dynamic in the province of Rio Negro, Argentina. *Veterinary Parasitology*, **98**(4): 263 – 272.
- Lawan MK, Bello M & Raji MA (2010). The Public Health Implications of the Operational Activities of Butchers in Abattoirs. Proceedings of the forty seventh Annual Congress of the Nigerian Veterinary Medical Association Annual Congress held at the College of Health Sciences, Benue State University, Benue State, Nigeria between 4th to 8th October, 2010. Pp 127-129.
- Layla OE & Wahab AR (2015). Prevalence of *Hydatid* cysts in slaughtered Animals from different areas of Libiya. *Open Journal of Veterinary Medicine*, **5**(1): 1-10.
- Macpherson CNL (1985). An active intermediate host role for man in the life cycle of *Echinococcus granulosus* in Turkana, Kenya. *American Journal of Tropical Medicine and Hygiene*, **32** (2): 397-404.
- Mitchell JR (1980). *Guide to meat inspection in the tropics*. Commonwealth Agricultural Bureaux, Farnham Royal Bucks, England. Pp 36-40.
- Mohammed I & Hoffmann I (2006). Management of draught camels (*Camelus dromedarius*) in crop-livestock production systems in Northwest Nigeria. *Livestock Research for Rural Development*, <http://www.lrrd.org/lrrd18/1/moha18016.htm>, retrieved on 24-06-2019.
- Mohammed I (2000). Study of the Integration of the Dromedary in the Smallholder Croplivestock Production System in Northwestern Nigeria. Goettingen: Cuvillier Verlag. Germany Pp 249.
- National Population Commission (2006): Population Census arranged by state. List of Nigerian states by population. Available at: https://en.wikipedia.org/wiki/List_of_Nigerian_states_by_population, retrieved on 07-06-2019.
- Ogunsan EA, Umar IO, Bannor TT & Majiyagbe KA (2000). *Hydatidosis* in slaughtered camels in Sokoto State, Nigeria. *Nigerian Veterinary Journal*, **21**: 1- 9.
- Rabi’u B & Jegede O (2010). Incidence study of *hydatidosis* among slaughtered animals at Kano Abattoir, Nigeria. *Biological and Environmental Science Journal for the Tropic*, **7** (2): 29-34.
- Regessa R, Alemante M & Jemere B (2010): Study on the prevalence of cystic *hydatidosis* and its economic significance in cattle slaughtered at Hawassa municipal abattoir, Ethiopia. *Tropical Animal Health and Production*, **42**(5): 977– 984.
- Soulsby EJJ (1982). *Helminths, Arthropods and Protozoa of Domesticated Animals*. Seventh edition, Bailliere Tindall, London. Pp 119-122.
- Tashani OA, Zhang LH, Boufana B, Jegi A & McManus DP (2002). Epidemiology and strain characterization of *Echinococcus granulosus* in the Benghazi area of eastern Libya. *Annals of Tropical Medicine and Parasitology*. **96**(4): 369-381.
- Thrusfield M (2005). *Veterinary Epidemiology*. Third edition, Blackwell Science, Oxford, UK. Pp 233-234.
- Urguhart GM, Armour J, Duncan JL, Dunn AM & Jennings FW (1988). *Veterinary Parasitology*, Longman, UK. Pp 1-228.
- Waziri MA, Shehu AA & Kwari HD (1999). Morphological changes of spermatozoa in sperm reserve during epididymal transit in the camel (*Camelus dromedarius*). *Tropical Veterinarian*, **17**: 135-141.
- Yakubu YB (2016). Seroprevalences of *Brucella* in Small Ruminants, Knowledge, and Attitude and Practices of Small Ruminants’ Owners in Kaduna metropolis, Kaduna State, Nigeria. MSc Dissertation, Department of Veterinary Medicine, Faculty of Veterinary Medicine, Ahmadu Bello University, Zaria, Nigeria. Pp 1-119.