
CASE REPORT: A GIANT URINARY BLADDER STONE IN A FEMALE PATIENT.

Nabieu PF,¹ Gevao PP,¹ Songu-M'brewa K,¹ Gegbai IB,¹ Musa M,¹ Swarray AB, ¹ Kamara CDS¹, Sahr F², Kamara TB³

¹Department of Surgery, ²Department of Internal Medicine, Joint Medical Unit, 34 Military Hospital, Wilberforce Barracks, Freetown.
³Consultant Urologist, Connaught Hospital, Freetown

<http://dx.doi.org/10.4314/sjbr.v7i2.6>

Abstract

A vesical calculus weighing more than 100g is categorized as a giant urinary bladder stone. Male preponderance for urinary bladder calculi is well known. A rare case of a giant urinary bladder calculus weighing 1200g and occurring in a female patient is reported. The stone was removed by open vesicolithotomy.

KEYWORDS: Urinary bladder; Urinary Tract Infection; Calculi; vesicolithotomy

*Correspondence: Nabieu, P F E-mail: fwwnabieu@yahoo.com, Tel: +232-33-317788/+232-78-912479.

INTRODUCTION

Primary urinary bladder stones are not common. They are associated with malnutrition.

A giant vesical calculus is defined as a stone in the urinary bladder weighing more than 100g. Giant vesical stones are universally not common and even less common in females. Fewer than 30 reports are available in the English literature.

In Nigerians, 44% bladder calculi have been reported, while, in North America, 5% urinary calculi have been reported. There have been no such case reports for Sierra Leone. Infections seem to be a predisposing factor.

We report a case of a Giant vesical calculus seen in a Sierra Leonean female with an unusual presentation.

CASE REPORT

A 36-year-old female soldier presented at the gynaecological department of Joint Medical Unit, 34 military hospitals, Freetown, with a history of intermittent haematuria, the frequency of micturition, dyspareunia, bilateral loin pains, urgency, pain and heaviness in the vagina and dysmenorrhoea. Symptoms started nine years ago and got worse in the past six months. Past medical history reveals that patient was treated for similar symptoms but never consulted a medical doctor.

On examination, she was not pale. On vaginal examination, there was a heavy, tender mass bulging into the anterior vaginal wall. All other systemic examinations were normal. A provisional diagnosis of uterine myoma, uterine prolapse or ovarian mass and urinary bladder stone was made. Laboratory investigations including Hb, PCV, WBC & differential, serum calcium, urea, and creatinine were within normal range. Uric acid was 434.4 mmol/L. Significant urine analysis results were as follows: appearance=turbid, blood (+), protein (+) and leukocytes (++) . There were no worm infestations in the stool and no signs of schistosomiasis. This was followed by pelvic ultrasound including KUB, which revealed huge bladder calculi measuring 14.7 centimetres, but the ureters and kidneys were normal (Fig.1).

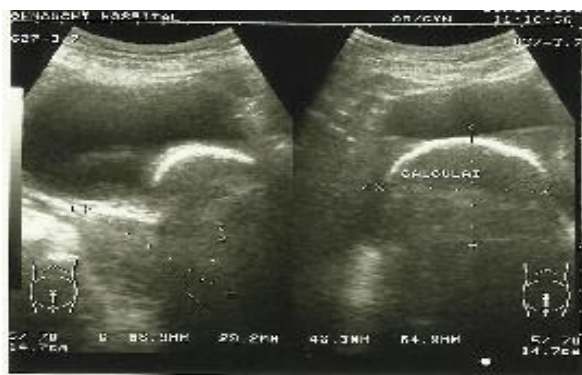


Fig. 1: UltraSound Result

Also pelvic X-ray (Fig 2) revealed a calculus. She was then referred to the surgical department for further management.

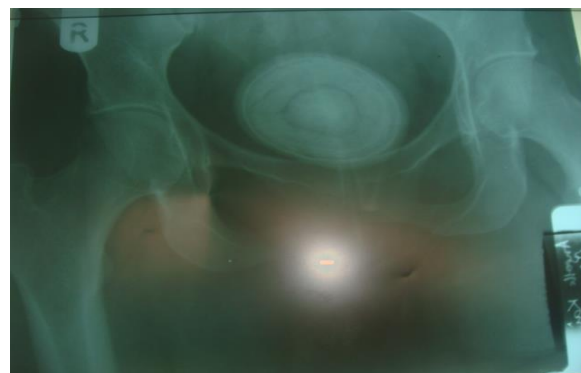


Fig. 2: Pelvic X-ray Result

In the surgical department, the patient was prepared, and surgery (Vesicolithotomy) was done two weeks later. At operation, a huge off white stone weighing 1200g and measuring 14 cm X 9 cm was removed from the bladder with minimal bleeding occupying the entire bladder (Fig.3 & 4). There was no diverticulum or ulceration seen, but the bladder wall was very thick. About 100 ml of offensive concentrated urine was drained in the urine bag during the operation. Postoperative recovery was uneventful, and she was discharged ten days later. Follow-up abdominal and pelvic ultrasound showed essentially normal upper urinary tracts.

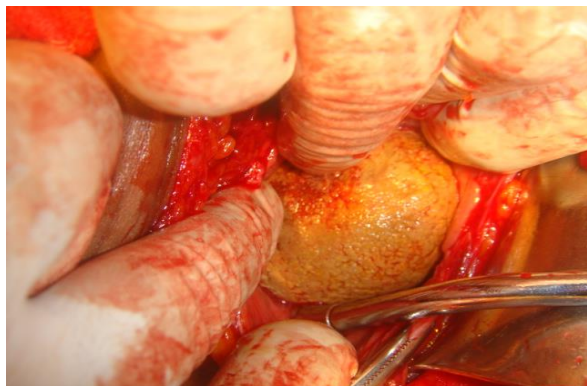


Fig 3: Huge Bladder Stone Being Removed



Fig. 4: Image of Removed Stone

The patient was followed-up for six months with no incidence.

DISCUSSION

A bladder stone, also called a vesical calculus or vesicolith, is a stone found in the urinary bladder. According to McNutt, WF 1893:185-6. , Calculus disease of the urinary system is known since historic times, Giant vesical calculi are rare in the modern era. [Becher RM *et al*, 1978a: 2272-2273]. Jan de Doot removed a bladder stone from himself according to a 1652 account in the book Observations Medicae by Nicolaes Tulp.

Primary bladder stones may occur whenever the kidneys, bladder, or ureters become inflamed. The use of urinary catheters may cause a bladder stone. Individuals who are paralyzed or are unable to pass urine adequately, may require the use of catheters. The use of these catheters may lead to an infection, which irritates the bladder, resulting in primary stone formation. A secondary kidney stone may travel down the ureter into the bladder and become a bladder stone. Frang *et al*. (1989) and Barsoum (2013) implicated digenean trematode,

Schistosoma haematobium, in the development of vesical calculi. However, our patient was negative for worm infestations including *Schistosoma*. Although the stool examination was negative for schistosomiasis, the patient's original home is from Kono district which is known for high prevalence of this parasitic infection. This may be one of the possible causes or urinary tract infection as indicated from the urinalysis.

Primary urinary bladder stones account for about 5% of urinary calculi. They are usually commoner in males than in females due to obstructive uropathy [WY *et al*. 2006: 674-675:].

Urolithiasis is a disease that varies from one part of the world to the other. Some areas are grouped as high incidence areas while others are grouped as low incidence areas. Factors that determine incidence include, race, diet climatic and socio-economic status (Trinchieri ,2008). A general decrease in incidence has been attributed to dietary and nutritional factors. Nigeria and many other sub-Saharan African countries belong to the low incidence area. (SOA *et al*. 1989: 148-61). They are more common in adults than in children. In children, primary vesical stones occur commonly in northwest India, Indonesia and the Middle East and part of China. Donald R. Smith 1981 suggest that the affected children have diets low in protein and phosphate. According to Thompson, J.C. 1921:44, secondary vesical stones develop as a complication of other urologic diseases, and 95% occur in adult men. In his report, Samison *et al*. 2002: 241-3 found that only 2 percent of primary vesical stones occurred in women

Urinary bladder stones are usually composed of calcium oxalate or magnesium ammonium phosphate (Schwart *et al*. 2000: 333-346). Majority compositions of the vesical calculi include triple phosphate, calcium carbonate, and calcium oxalate. Due to lack of analytical facilities, we were unable to do the chemical analysis of the stone of our patient

The risk factors for urinary stone formation include urinary stasis (benign prostate hyperplasia, urethral stricture, bladder neck contracture, and neurogenic bladder), urinary tract infection and foreign bodies (Mbonu O *et al*. 1984: 291-296) urine flow by lying on one side while voiding, haematuria, and even urinary outlet obstruction which lead to urinary retention, hydronephrosis, and oliguria. Our patient presented with dyspareuria, haematuria and pelvic pain. Physical examination is rarely of value in establishing a diagnosis, but instances have been cited in which a large stone was palpable on rectal, vaginal or

abdominal examination. In our patient, the stone was palpable on vaginal examination, and this was one of our provisional diagnoses which were also confirmed by IVU. Becher RM *et al* 1978b: 2272 suggests that sensing the bladder stone by feeling it "clink" on a urethral sound is an age-old technique of detecting bladder stone. Roentgenographic and sonographic studies can be helpful but the most accurate and certain means of diagnosis is cystoscopic examination, The techniques for treatment of vesical calculi has evolved over years from 'blind' insertion of crushing forceps into the bladder to open surgical removal or extracorporeal fragmentation, cystolitholapaxy, percutaneous cystolitholapaxy and open suprapubic vesicolithotomy. However, open surgery has been the best-recommended modality for large stones (Nichols BH *et al*, 1933). Complications of this treatment include infection and damage to the bladder. Relieving urinary stasis and eliminating infection are vital for the prevention of stone formation.

References:

- Becher RM Tolia BM, Newman HR (1978a): Giant vesical calculus. JAMA 2272-2273
- Becher RM Tolia BM, Newman HR (1978b). Giant vesical calculus. JAMA, 239:2272.
- Donald R. Smith. Urinary stones in General Urology by DR. Smith. 10th Edition 1981 Lange Medical Publications Los Atlos, California.
- Duvie SOA, Endeley EMI, Sahniya MH. (1989). The Nigerian Savanna Belt experience. West Afr.J. Med.; 7:148.
- Frang D (1989). "Multiple urolithiasis in bilharziasis patients". International Urology and Nephrology 21 (3): 269-73.
- Ibrahim, A (1978). "The relationship between urinary bilharziasis and urolithiasis in the Sudan". British Journal of Urology 50 (5): 294-7.
- Joly JS (1931). Stone and Calculus Disease of the urinary organs. St. Louis, C.V.
- Lin WY, Wu CF, Shee JJ. A decade of recurrent cystitis in a woman due to a giant vesical calculus. Int Urogynecol J Pelvic Floor Dysfunct 2006; 17: 674-675
- McNutt, WF (1893). "Chapter VII: Vesical Calculi (Cysto-lithiasis)". Diseases of the kidneys and bladder: a text-book for students of medicine. IV: 185-6.
- Mbonu O, Attah Ch, Ikeakor I. (1984). Urolithiasis in an African population. International Urology and Nephrology; 16:291-296
- Nichols BH Lower W E (1933), Roentgenographic studies of the urinary system. St. Louis, CV
- Samison L H, Razafimahandry HJ, Rakotosamimanana J, Andrianabelina R, Ranaivozanany (2002). A Giant bladder calculus in two farmers in Madagascar. Bull. Soc. Path.; 95 241-3.
- Schwartz BF, Stoller ML, (2000). The vesical calculus. Urol Clin N Am; 27: 333-346
- Thompson, J.C. (1921): Urinary Calculi at the Canton Hospital.Surg. Gynaecol. Obstet., 32:44.
- Shergill SS, Cameron LA, Brammer MJ, William SC,
- Trinchieri A, (2008). Epidemiology of urolithiasis: an update. Clin Cases Miner Bone Metab 5(2): 101-106.
- Murray RM, McGuire PK (2001). Modality specific neural correlates of auditory and somatic hallucination. Journal of Neurology. 71:688-90
- Stephens D (2000). A history of tinnitus. In: Tyler R (ed.) Tinnitus handbook. San diego: Singula publishing group. 437-48
- Unterrainer J., Greimel K.V., Leibetseder M. (2001). Are Demographic and Socioeconomic Factors Predictive for Perceived Tinnitus Impairment? *International Tinnitus Journal*, 7(2): 109-111