

The Macro-anatomy of the Stomach of Wild African Giant Pouched Rat (*Cricetomys gambianus*)

O. Byanet^{*1}, S. O. Salami², M. N. Ali², J. Imam², S. M. Maidawa², A. D. Umosen²,
C. Alphonsus³ and J. O. Nzalak²

¹Department of Veterinary Anatomy, College of Veterinary Medicine, University of Agriculture,
Makurdi, Nigeria; ²Department of Veterinary Anatomy, Faculty of Veterinary Medicine;
and ³Department of Animal Science, Faculty of Agriculture, Ahmadu Bello University,
Zaria, Nigeria

ABSTRACT

The segments of the vertebrate digestive system demonstrate a wide range of structural and functional variations which is adapted to suit the dietary requirements of the particular species. African giant pouched rat (AGPR) is an omnivorous rodent. The animals were anaesthetized using gaseous chloroform and the stomach harvested through the ventral midline incision after the animals had been sacrificed. The morphometric analysis and gross anatomical observations revealed that the mean body and stomach weights of the AGPR were 1045.5 ± 110.6 g and 28.81 ± 0.93 g respectively. The stomach of the AGPR accounted for 3 % of the body weight. Grossly; the stomach of the AGPR was divided into two parts: the non-glandular and the glandular parts. The stomach mean length was 20.51 ± 0.81 cm, while the glandular and non- glandular regions were 6.21 ± 0.73 cm and 13.26 ± 0.59 cm respectively. The glandular stomach constituted of the following regions: cardiac, fundic, pyloric and a gastric pouch-like diverticulum. The non-glandular part was in a form of coma- shape, with blind sac-like end. The non-glandular mucosa was observed to be brownish in color and presented with numerous soft towel-like papillae or projections. A groove that covered few millimeters (5mm) besides the opening of the esophagus on the right was demarcated by a raised fold of limiting ridge or membrane. The proventricular mucosa was brownish in color. Based on the internal and external structural arrangement, we are classifying the stomach of the AGPR as a simple monogastric.

Key words: African giant pouched rat (AGPR), anatomy, stomach.

INTRODUCTION

African giant pouched rat (AGPR)(*Cricetomys gambianus*), also known as the Gambian pouched rat is a giant pouched rat of the genus, *Cricetomys* and of the order, Rodentia (Wikipedia, 2008). Its name comes from the large, hamster-like pouches on its cheeks. It was considered a unique African branch of muroid rodents and not a true rat. The AGPR is an omnivorous animal, feeding on vegetables, insects, crabs, snails and other items, but apparently in West Africa, preferring palm fruits and palm kernels (Wikipedia, 2008).

Attempts are being made in Nigeria and some other African countries to domesticate these animals in captivity for food and as laboratory animals (Ajayi, 1971). With their excellent sense of smell, they are used to detect trace amount of explosives that leak from landmines (Lindow, 2008). The AGPR are often eaten and are considered a delicacy in Nigeria and other West African countries. Indeed, the smoked carcasses of these rodents are often sold in the villages and towns as bush meat in Nigeria (Ajayi, 1971). In spite of their usage, very little is documented regarding their anatomical structures.

The stomach is the large dilatation of the alimentary canal behind the diaphragm which intervenes between the esophagus and the small intestine (Sission and Grossman, 1953). It is an organ used for storage and digestion of food (Saladin and Kenneth, 2004). In animals, the main function of the stomach is to break large molecules of food substances into smaller ones, so that they can easily be absorbed in the intestine (Sherwood, 2002). Three regions have been described in the monogastric animals like the dog, cat, pig, rabbit and man. These are: cardiac, fundic and pyloric regions (Ojo *et al.*, 1987). These regions are usually specialized to suit the dietary requirements of the animal species (Hildebrand and Goslow, 2001).

*Author for correspondence

Among rodents, the stomach of the rat has been described to be a monogastric compound stomach, which is divided into two parts; proventriculus (non-glandular) and glandular (Rudolf and Stromberg, 1976). The anatomy of the stomach of the conventional animals and some rodents has been documented in the literature, but such information is deficient for AGPR. Therefore, this study was carried out to provide the gross and morphometric baseline data on the AGPR. These results will provide data for the breeders, researchers and nutritional scientists, which will support the manufacture of feed for AGPR bred in captivity.

MATERIALS AND METHODS

Source of animals

In this research, ten mature African giant pouched rats of both sexes were used. The animals were captured alive in the wild around Samaru and Bomo villages in Zaria, Kaduna State, Nigeria. Local metal traps were used to capture and transport them to the laboratory. They were kept in laboratory rat cages with grasses as bedding for two weeks and fed with locally prepared groundnut pellet. Water was given *ad libitum*.

Experimental design

Physical examination revealed that the animals were clinically healthy and in good nutritional status prior to the study. The animals were anaesthetized using gaseous chloroform in a confined container measuring 35 cm in length and 15 cm in width. They were weighed using Mettler balance (Model P 121) and their weights were recorded in grams (g).

An incision was made on the ventral midline, beginning from the cervical region up to the level of the pelvic region. The abdominal cavity was opened and the regular fat stores around the kidneys, the omentum and the mesenteric were observed in all animals. The stomach was excised away from the thoracic part of the esophagus and from the first segment of the duodenum close to the pyloric sphincter. The weight of each stomach was taken and recorded in grams (g).

Photographs of the external and the internal surfaces were taken. The gross anatomic features of the external and internal surfaces were noted. Transverse and longitudinal diameters of the stomach were measured using meter ruler, flexible thread and venier caliper, and recorded centimeters (cm) and expressed as mean \pm SEM

RESULTS

Morphometric observations

The mean body and stomach weights of the AGPR were 1045.5 ± 110.6 g and 28.81 ± 0.93 g, respectively. The stomach of the AGPR accounted for 3 % of the body weight. The stomach mean length was 20.51 ± 0.81 cm, while the glandular and non- glandular regions were 6.21 ± 0.73 cm and 13.26 ± 0.59 cm, respectively. Thus, the non-glandular was longer than the glandular part but the latter was wider. The glandular and non-glandular parts accounted for 30 % and 66 % of the total stomach length, respectively.

Gross structure

The body weight, stomach weight and dimensions are recorded in Table 1. The macro anatomic aspect of the external surface of the stomach is presented in Fig. 1, while that of the internal surface is in Fig. 2.

Table 1. The body weight, stomach weight and dimension of African giant rat (n = 10)

Parameter	Min - Max	Mean	Mean \pm SEM
Body weight (g)	500 - 1400	1045.5	1045.5 ± 110.6
Stomach weight (g)	26 - 35	28.81	28.81 ± 0.93
Stomach length (cm)	14 - 23	20.51	20.51 ± 0.81
Glandular length (cm)	5.4 - 10	6.21	6.21 ± 0.73
Glandular width (cm)	2.8 - 5	3.75	3.75 ± 0.28
Proventriculus length (cm)	8.6 -14.5	13.26	13.26 ± 0.59
Proventriculus width (cm)	1.8 - 4.78	3.13	3.13 ± 0.31

Min = minimum; max = maximum; SEM = standard error of the mean, n = sample size

External surface

Grossly, the stomach of the AGPR was divided into two parts: the non-glandular and the glandular portions. The glandular stomach constituted of the following regions: cardiac, fundic, pyloric and a gastric pouch-like diverticulum. It presented two curvatures, a greater and a lesser, two surfaces (the parietal and viscera) and two

orifices (cardiac and pyloric). The esophagus entered the greater curvature at the constricted area. The constricted area separated the glandular from the non-glandular part. The fundus formed the greater curvature (Fig. 1).

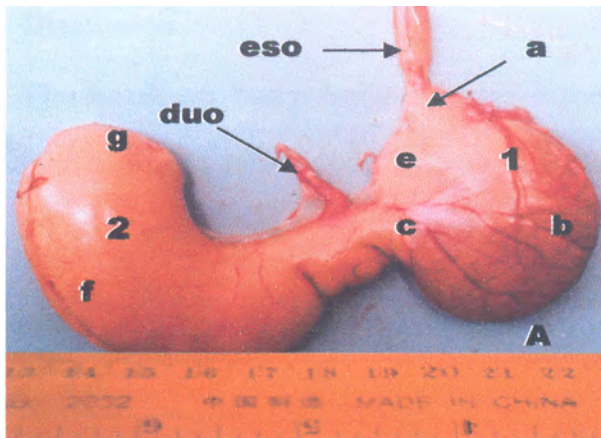


Fig. 1. External surface of the stomach of the African giant pouched rat showing the two divisions of the stomach: glandular (1) and non-glandular (2). The four regions of the glandular stomach: cardiac (c), fundus (b), pylorus (a) and gastric diverticulum (e). The non-glandular stomach consists of comma-shaped fundus (f) and a blind sack-like end, called saccus cecum (g). Other structures include the stumps of the esophagus (eso) and duodenum (duo)

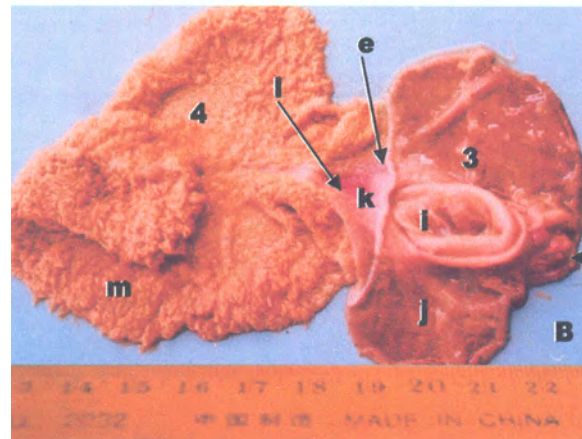


Fig. 2. Internal structure of the stomach showing the glandular mucosa (3) and the non-glandular mucosa (4). Structures in the glandular part include the pyloric sphincter (b), gastric diverticular folds (i) and the smooth mucosa of the fundic region (j). The groove (k) and esophageal orifice (1) were on the constricted area. The soft-like towel papillae, velvety and thick wall (m) were observed in the non-glandular mucosa

Internal surface

The mucous membrane of the esophagus was continuous with the gastric wall of the cardiac region of the glandular part of the stomach. The non-glandular mucosa was observed to be thick, soft and velvety, while, the glandular was smooth. A groove (5 mm) besides the opening of the esophagus, on the right was observed to be interrupted by a raised fold of limiting ridge or membrane. The internal limiting ridge separated the glandular part from the non glandular part of the stomach internally. The gastric wall of the diverticulum region had two distinct thick mucosal folds. The proventricular mucosa was brownish and presented with numerous soft towel-like papillae or projections (Fig. 2).

DISCUSSION

The result on body weight is above the 0.5% reported for laboratory rat (*Rattus norvegicus*) (Caster *et al.*, 1956) and the 14.06 ± 0.09 cm stomach length for African pangolin (Ofusori *et al.* 2008). Grossly, the stomach compartments in this study were similar to those for the stomach of the rat (*Rattus norvegicus*) which has two compartments, although without distinct constricted area externally, but an internal limiting membrane that separated the two compartments (Rudolf and Stromberg, 1976). Robert (1971) described this fold or membrane in rat as limiting ridge.

Guieysse-Pellissier (1937) described the transition from proventriculus to glandular mucosa in rat to take place at the bottom of a groove within the mucosa fold. Ojo *et al* (1987) reported that pig and horse stomachs have composite lining, consisting of glandular and non-glandular areas. The proventricular part is small in the pig, but extensive in the horse. Like in the horse (Ojo *et al.*, 1987), the junction between the two compartments in the AGPR is marked by irregular, raised ridge, called *Margo plicatus*.

The *Margo plicatus* according to Smallwood (1992) is a structure which acts as a valve to prevent the gastro-esophageal reflux. Ojo *et al* (1987) reported that the proventricular part of the stomach of animals is a dilation of the embryonic esophagus that has become part of the stomach.

The mucosa of non-glandular stomach in this study was brownish in coloration and presented with soft-towel, short numerous papillae similar to that seen in the rumen of the ruminants. However, the rumen, particularly in the ventral sac, is thrown into long, finger-like ruminal papillae (Olusanya and Olowo, 1988) which are relatively longer than those in this study. The rumen has been described as a fermentation vat (Ojo *et al.*, 1987; Sisson and Grossman, 1953) and herbivores depend on micro-organisms which have enzymes, the cellulases present in the rumen that can digest or ferment cellulose. The internal structure of the non-glandular stomach of the AGPR, suggests that a similar process of fermentation can take place in it.

The two stomach compartments in AGPR had thick walls, particularly at the pyloric sphincter. According to Devyn *et al.* (2000), the thickened muscles allow for elastic distension of the stomach when large quantity of food

is ingested and for subsequent peristaltic movements required for the mechanical mixing of food and secreted products. The controlled passage of food from the stomach into the small intestine is regulated by the pyloric sphincter, an organ derived from the foregut (Smith and Tabin, 1991). The pyloric sphincter is distinguished according to Devyn *et al* (2000) by its thickness and mesodermal layer, where as the epithelial layer has the same morphology as the pyloric region of the stomach.

Differences exist in terms of stomach morphology among rodents. For example, Smallwood (1992) showed that the stomachs of mouse and rat were divided into two parts: a cranial aglandular and a distal glandular. These two parts were separated by a folded margin called Margo plicatus. The stomach of the capybara (*Hydrochaeris hydrochaeris*), has been classified as a simple stomach, in the form of a curved sac, similar to an inverted letter 'J' (De Barros *et al.* 2002). The stomach of the grasscutter (*Thryonomys swinderinus*) has also been observed to be simple stomach (Byanet *et al.*, 2008).

In conclusion, our study has described the morphometric and morphologic observations of the stomach of the African giant pouched rat. Based on the internal and external morphology, we are classifying the stomach of the African giant pouched rat as a monogastric stomach.

ACKNOWLEDGMENT

We acknowledge the technical assistance of the gross and histology laboratory staff, Department of Veterinary Anatomy, Faculty of Veterinary Medicine, Ahmadu Bello University, Zaria, Nigeria.

REFERENCES

- Ajayi, S.S. (1971). Wildlife as a source of protein in Nigeria: Some priorities for development. *The Nig. Field* 36, 115.
- Byanet, O., Nzalak, J.O., Salami, S.O., Nwogu, I.C., Boshu, J.A., Umosen, A.D., Ojo, S.A. and Obadijah, H.I. (2008). Macroscopic studies of the gastrointestinal tract of the African grasscutter (*Thryonomys swinderianus*). *Vet. Res.* 2(2), 17-21.
- Caster, W.O., Poncelet, J., Simon, H.B. and Armstrong, W.A. (1956). Tissue weights of the rat: Normal values determined by dissection and chemical methods. *Proc. Soc. Exp. Biol. Med.* 91, 122-126
- De Barros, P.T., Pacheco, M.R., De Souza, W.M., Da Silva, R.A., Neto, P.B.S., De Figueiredo, Barreto, C.S. and Ribeiro, A.A.C. (2002). Morphological aspect of the Capybara stomach (*Hydrochaeris hdrochaeris*): Gross and Microscopic structure. *Anat. Histol. Embryol.* 31, 362-366.
- Devyn, M.S., Rayetta, C., Grast, N., Theodosio, C.J., Clifford, J.T. and Nanette, M.N. (2000). Evolution relationships between the amphibian, avian and mammalian stomachs. *Evol. Dev.* 2, 348-359.
- Guieysse-Pellisseir, A (1937). Note surlakeratinisation de le' estomac du rat et de la souri. *C.R. Assoc. Anat.* 32, 206-211.
- Hildebrand, M. and Goslow, G.E. (2001). *Analysis of the Vertebrate Structure*, 5th ed. John Wiley and Sons Inc., New York. pp.201-217.
- Lindow, M. (2008). The land mines - sniffing rats of the Mozambique. *Time Magazine*. Retrieve on 2008-06-23
- Ofusori, D.A., Enaibe, B.U., Falana, B.A., Adeeyo, A.O., Yusuf, U.A. and Ajayi, S.A. (2008). A comparative analysis of the stomach in the rat (*Rattus norvegicus*), bat (*Eidolon helvum*) and pangolin (*Manis tricuspis*). *J. Cell Anim. Biol.* 2, 079- 083
- Ojo, S.A., Adogwa, A.O. and Hambolu, J.O. (1987). The digestive system. In: *Essentials of Veterinary Gross Anatomy* Ahmadu Bello University Press, Zaria, Nigeria. pp. 138-183.
- Olusanya, H. and Olowo, O. (1988). The digestive system. In: *Anatomy and physiology of Tropical Livestock*. Loggman Publishers, Singapore. pp. 53-63.
- Robert, A. (1971). Proposed terminology for the anatomy of the rat stomach. *Gastroenterol.* 60, 344-345.
- Rudolf, H. and Stromberg, M.W. (1976). Digestive system. In: *Anatomy of the Laboratory Rat*. Williams and Milkins, Baltimore, USA. pp.43-51.
- Saladin and Kenneth, S. (2004). *Anatomy and Physiology- the Unit of Form and Function*, 3rd ed. McGraw-Hill Co., New York. pp. 950.
- Sherwood, L. H. (2002). *Human Physiology: From Cells to System*, 5th ed. Books. Colo-Thomson Learning. pp. 604.
- Sisson, S. and Grossman, J. D. (1953). The digestive system of horse and ruminant. In: *The Anatomy of the Domestic Animals*, 4th ed. W. B. Saunders Co., Philadelphia, USA. pp. 387- 516.
- Smallwood, J.E. (1992). *A Guide Tower of Veterinary Anatomy: Domestic Ungulates and Laboratory Mammals*. Saunders Co., New York. pp. 338-363.
- Smith, D.M. and Tabin, C.J. (1991). BMP signaling specifies the pyloric sphincter. *Nature* 402, 748-749.
- Wikipedia® (2008) is a registered trademark of the Wikimedia Foundation, Inc., a U.S. Website on African Rodentia: <http://projects.biodiversity.be/africanrodentia>.