

**Article History**

Received: 26-01-2023

Revised: 10-07-2023

Accepted: 22-08-2023

Published: 29-09-2023

## Histological Features of Olfactory Bulb Layers in the African Striped Ground Squirrel (*Xerus erythropus*)

\*<sup>1</sup>Abiyere, E., <sup>1</sup>Umosen, A. D. <sup>1</sup>Ali, M. N., <sup>1</sup>Umar, M. B., <sup>1</sup>Zubairu, M., <sup>2</sup>Muazu, T. A.,  
<sup>3</sup>Omar, H.A. and <sup>4</sup>Usende, I. L

<sup>1</sup>Department of Veterinary Anatomy, Faculty of Veterinary Medicine, Ahmadu Bello University Zaria

<sup>2</sup>Department of Veterinary Anatomy, Faculty of Veterinary Medicine, Bayero University Kano

<sup>3</sup>Department of Veterinary Anatomy, Faculty of Veterinary Medicine, Joseph Sarwuan Tarka University Makurdi

<sup>4</sup>Department of Veterinary Anatomy, Faculty of Veterinary Medicine, University of Abuja

\* Author for Correspondence: [maxwellabiyere@gmail.com](mailto:maxwellabiyere@gmail.com)

**ABSTRACT**

The diurnal African Striped Ground Squirrel (ASGS) (*Xerus erythropus*), is a member of the rodent order *Rodentia* and family *Sciuridae*. Similar to most other vertebrates, the olfactory bulbs (OB) are located most rostrally in the brain and are an integral component of the brain circuitry system responsible for the sense of smell. In this work, the layers and anatomical characteristics of OB in the ASGS were examined. Six (6) adult ASGS were sourced from villages within Zaria Local Government. They were housed in standard laboratory cages and fed with corn and carrot. Water was given *ad libitum*. The squirrels were euthanized via the abdomen with an injection of ketamine HCL (80mg/kg BW), followed by transcardial perfusion with 10% buffered formalin. Craniotomy was carried out to expose the entire brain and the OB was carefully harvested for histological evaluation. Six layers were visible in the olfactory bulb cortex, working their way inward from the outside in. The cells observed were mitral cells, peri-glomerular, granular, and tufted cells. Interestingly, the glomerular layer was observed to be a single layer cell type which is indicative of a good olfactory acuity. It was concluded that African Striped ground squirrel's one-layered cell thick glomerular layer is indicative of good olfaction and sense of smell giving the ASGS an advantage for navigation in search for food and protection from predation.

**Keywords:** African Striped Ground Squirrel; Cytoarchitecture; Olfactory bulb

**INTRODUCTION**

An important component of the central nervous system responsible for the sense of smell is the olfactory bulb, a region of the vertebrate forebrain involved in the perception and processing of information regarding odors (Moore and Persaud, 2003; Hamilton et al., 2005; Nolte, 2007).

A diurnal rodent, the African Striped Ground Squirrel (ASGS) is a member of the family *Sciuridae*, genus *Xerus*, and species *Xerus erythropus* (Thorington and Hoffmann, 2005). Two of the six identified subspecies, *Xerus erythropus erythropus* and *Xerus erythropus chadensis*, are found in Nigeria (Herron and Waterman, 2004). Adult ASGS has an average weight of 750g with whitish underparts, a lateral stripe of completely white fur that extends from the shoulders to the hips on both sides (Herron and Waterman, 2004; Thorington and Hoffmann,

2005). It was suggested that the ASGS aids in seed dispersal and uses the scatter hoarding method to bury caches in the winter. The squirrel can locate these caches using both memory and smell (Joanna et al., 2005; Legg and Clayton, 2014). Squirrels are one of the small mammal species that are most frequently eaten in Southern Nigeria as an additional source of protein (Ajayi, 1979; Adeola and Decker, 1987).

To identify and comprehend the comparative anatomical features in relation to other rodent species, information on a detailed descriptive investigation of the OB of the ASGS is essential. It might also shed light on some of the behavioral characteristics of this rodent in order to improve breeding. Previous, neuro-anatomical studies on the brain of the African striped ground squirrel were limited to aspect of the brainstem and gross study of the telencephalon (Ajeigbe et al., 2021; Abiyere et al., 2022).

There is dearth of information on the cytoarchitecture of the Olfactory bulb of the African striped ground squirrel. This study was designed to describe the layers and special anatomic features of the Olfactory bulb of ASGS, thereby, generating very fascinating data on the olfactory bulb of this species.

## MATERIALS AND METHODS

In this study, six (6) adult African Striped Ground Squirrel (*Xerus erythropus*), were sourced from surrounding villages of Zaria Local Government. They were kept in standard laboratory cages and fed with corn, sweet potatoes and vegetables. Water was given *ad libitum*.

The rodents were euthanized by injecting 80 mg/kg BW of ketamine HCL intraperitoneally, lateral to the midline next to the umbilicus (Molina *et al.*, 2015). The thorax of each animal was opened by making an incision from the base of the neck down to the xyphoid. For proper fixation of the brain, blood was drained via the right atrium and a needle was inserted into the left ventricle for passage of normal saline to flush and drain blood from the head via the jugular vein to the cranial venae cavae into the right atrium. This was instantly followed by 10% buffered formalin fixative solution to fix the brain. Decapitation of the ASGS was done at the atlanto-occipital joint.

The skulls were exposed by removing the skin and musculature over it. A slit through the calvaria using a handsaw was made to enhance the fixation. The exposed skulls were placed in containers and allowed to fix in 10% buffered formalin solution for 72hours. The brains were extracted according to the procedure described by Ramaswamy (1978). The cerebrum was detached from the brainstem as described by Fletcher (2006). The olfactory bulbs were detached from the cerebral halves by making a cut on the olfactory peduncles on the ventral aspect of the brain.

The fixatives from the tissues were washed off with distilled water. Dehydration of the tissues were done by immersion in series of ascending concentration of ethanol (70%, 80%, 90% and 100%) with a time interval of 1 hour for each stage of dehydration. The tissues were cleared in xylene, infiltrated with molten paraffin wax, according to standard procedure (Kiernan, 2007). Coronal sections of 10µm were made using a microtome (Model 42339, Berlin, Germany) after which the sections were floated on lukewarm water in a floatation bath for stretching. The sections were mounted on glass slides, and then dried, de-paraffinized, stained and cover-slipped using dibutyl phthalate and xylene (DPX) as the mountant. Haematoxylin and Eosin was used as routine stain, while, cresyl fast violet stain as special stain for Nissl substance of neuronal cell bodies (Drury, 1980). Digital eyepieces (SCOPETEK® DCM500, Resolution 16M pixels) installed on a light microscope (OLYMPUS® CH23, Germany) were used to take photomicrographs. As a reference, the Atlas of Brain Anatomy by Paxinos and Watson (1998) was used.

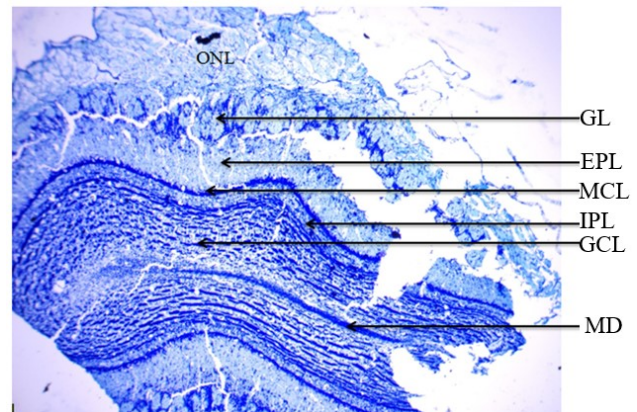
## Ethical Statement

The experimental procedure was given clearance by the Ahmadu Bello University Committee on Animal Use and Care (ABUCAUC) of experimental animals, with approval number ABUCAUC/2021/070.

## RESULTS

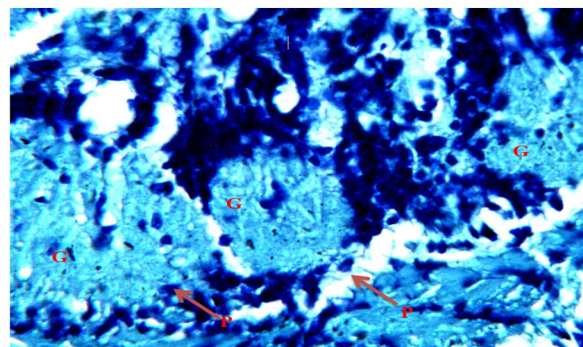
The result of this present study showed that there were six olfactory bulb layers in the olfactory bulb of African striped ground squirrel (ASGS); they include: the olfactory nerve layer, the glomerular layer, the external plexiform layer, the mitral cell layer, the internal plexiform layer and the granule cell layer with a central core of white matter called the medulla. The mitral cells, the periglomerular cells, the granular cells and tufted cells were the various cells identified in this study.

*The olfactory nerve layer:* This was the first and most superficial layer of the main olfactory bulb with very limited cell bodies stained with Cresyl fast violet. (Figure.1)



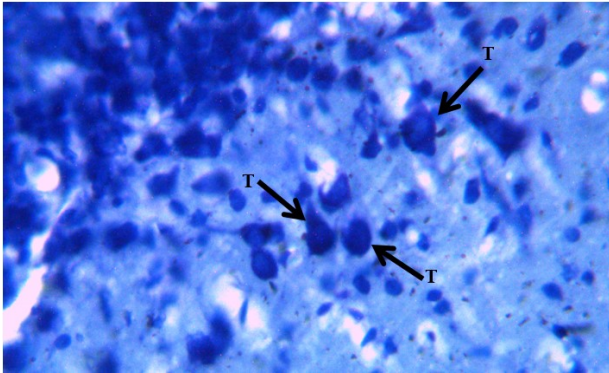
**Figure 1:** Coronal section of the olfactory bulb of adult African striped ground squirrel showing Olfactory nerve layer (ONL); Glomerular layer (GL); External plexiform layer (EPL); Mitral cell layer (MCL); Internal plexiform layer (IPL); Granule cell layer (GCL) and Medulla (MD). Cresyl violet stain. X40

*Glomerular layer:* this is the second layer which was composed of numerous periglomerular cells surrounded by bundles of nerve fibers. (Figure 2)



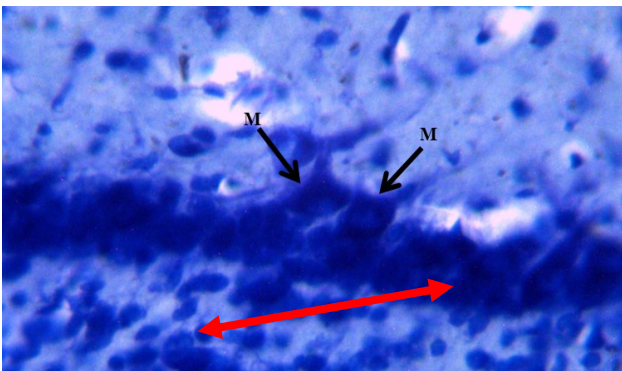
**Figure 2:** Glomerular layer of the olfactory bulb in the adult African striped ground squirrel showing Periglomerular cells (P) and Glomerulus of the glomerular layer (G). Cresyl violet stain. X400

*The external plexiform layer:* this form the third layer and consist of abundant periglomerular cells that were similar in shape to mitral cells but smaller in size to the mitral cells. (Figure 3)



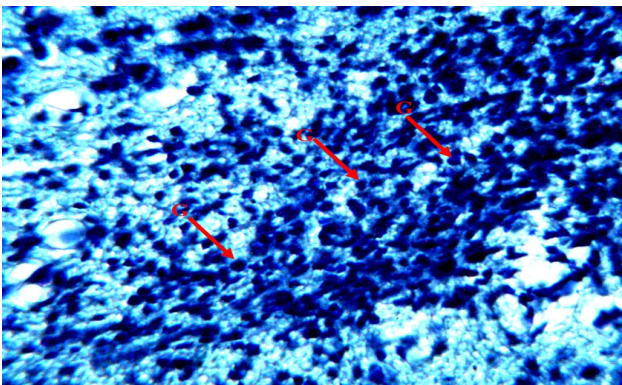
**Figure 3:** External plexiform layer of the olfactory bulb in the adult African striped ground squirrel, showing Tuft cells of the external plexiform layer (T). Cresyl violet stain. X400

*The mitral cell layer and Internal plexiform layer:* this forms the fourth and fifth layer of the olfactory bulb. This layer was observed to consist of large pyramidal mitral cells and few periglomerular cells. (Figure 4)



**Figure 4:** Mitral cell layer of the olfactory bulb in the adult African striped ground squirrel. Showing Mitral cells of the mitral cell layer (M) and Internal plexiform layer with ranule cells (red double head arrow). Cresyl violet stain. X400

*The Granular layer:* This forms the deepest layer of the olfactory bulb. This layer consists of numerous and densely packed granular cells. In the center was an area composed of white matter called the medulla (Figure. 5)



**Figure 5:** Granular layer of the olfactory bulb in the adult African striped ground squirrel. Showing Granule cells of the granular cell layer (G). Cresyl violet stain. X400

## DISCUSSION

The olfactory system has been reported to have influence on social life, survival, sexuality and breeding of animals (Shipley *et al.*, 2004; Amir and John, 2006). The organization of the olfactory bulb (OB) in Adult African striped ground squirrel (ASGS) is largely typical as described for other mammals even as some variations exist. In the present study, the six layers Cytoarchitecture of the OB in the adult ASGS is in line with the findings of Olude *et al.* (2014) in Africa giant rat (AGR). Conversely, 5 layers were reported in African grass cutter (Ibe *et al.*, 2018) and four (4) layers in African giant rat (Nzalak *et al.*, 2005). Comparatively, previous studies have also revealed up to eight (8) layers in Elephant and other vertebrates (Shoshani *et al.*, 2006; Smitka *et al.*, 2009) to include the ependymal layer and external granular layer.

In this study, the periglomerular cells were closely connected and distributed around the glomeruli. The glomerular layer was one (1) layer cell thick. Two (2) layer cell thick was reported in AGR (Olude *et al.*, 2014), a 3-layer thick glomerular layer was reported in wistar rat (Bukar, 2015) while four (4) layers cell deep was reported in the African elephant (Ngwenya *et al.*, 2011). This may likely suggest that the ASGS may have a better olfaction than the wistar rat, African giant rat and African elephant because impulses can easily be conducted faster through 1 layered thick surface than a surface that is 2 or 3 layer thick. The site for synaptic contact between the olfactory receptor axons and the olfactory principal cell is the glomerular layer which then act as the functional units of the olfactory bulb (Chao *et al.*, 1997).

Furthermore, the result of this study also revealed three cell types in the OB; the granule cells, the mitral cells and the tufted cells. The mitral cells appeared as the largest and were pyramidal in shape similar to previous findings in dogs by Wei *et al.* (2008). The internal plexiform layer observed in the current study was a very thin layer and one cell thick; it has a low cell density and few periglomerular cells. The periglomerular and granular cells are interneurons in the olfactory bulb. The granule cell layer is typically described as the largest layer of the OB. In the ASGS, the granule cell layer was the most extensive and most of the neurons are granule cells like in the African elephant (Ngwenya *et al.*, 2011). The granule cells were corpulent in shape and lied in the deepest part of the olfactory bulb. Wei *et al.* (2008) also reported similar findings in the olfactory bulb of dogs. These features of the structure of the olfactory bulb make it easier for information processing, and they also provide a structural foundation for the spatial encoding of olfactory information (Hamilton *et al.*, 2005; Mori *et al.*, 2006).

## CONCLUSION

The African striped ground squirrel's olfactory bulb included six layers and many cell types, including mitral cells, periglomerular cells, granular cells, and tufted cells. However, the olfactory bulb's glomerular layer had a single-layer cell type, suggestive of strong olfactory acuity. Thus, it is possible that African striped ground

squirrels have a keen sense of smell which could be used for navigation and protection from predators.

### Acknowledgment

The authors express their gratitude to International Brain Research Organization (IBRO) for the grant to present a segment of the research at a conference organized by IBRO.

### Conflict of Interest

The authors declare that there is no conflict of interest

### Author's Contributions

AOE, UAD and AMN were involved in the conception and design of the experiment. AOE and ZM did the laboratory work. AOE, UFL and AUD analysed the experimental results. AOE, MTA and OHA wrote the manuscript. AMN and UMB proof read the manuscript. All authors have read and approved the final manuscript.

### REFERENCES

- Abiyere, E., Umosen, D. A., Umar, M.B., Oyelowo, F.A., Ali, M.N., Zubairu, M. and Usende, I.F. (2022). Insight into the Functional Gross Morphology and Morphometry of the Cerebral Hemispheres and Olfactory Brain, and Sexual Dimorphism of the African Striped Ground Squirrel (*Xerus erythropus*). *Journal of Veterinary Anatomy* 15(1):17-33  
<https://doi.org/10.21608/jva.2022.226449>
- Adeola, M. O. and Decker, E. (1986). Wildlife utilization in rural Nigeria. In Clers, B.D. (edition) Proceedings of the International symposium and conference on wildlife management inn Sub-Sahara Africa, Harare, Zimbabwe, pp 512-521
- Ajayi, S. S. (1979). *Utilization of Forest WildLife in West Africa*. Misc/79/26. Food and Agriculture Organization, Rome, Pp 79.  
<https://doi.org/10.1016/b978-0-12-816962-9.00013-2>
- Ajeigbe, S.O., Tauheed, A.M. and Nzalak, J.O. (2021). Histomorphological Study of the Pons and Medulla Oblongata of Africa striped ground squirrel (*Xerus erythropus*). *Egyptian Journal of Veterinary Science*. 52(3):361-372.  
<https://doi.org/10.21608/ejvs.2021.75614.1232>
- Amir, A. and John, M. (2006). Anatomy of Olfaction system. Department of Neurosurgery and Spine, St Johns's Health centre, Santa Monica, CA. Medicine, Section 1-10
- Bukar, P. (2015). Anatomical comparison between the olfactory bulb of Africa giant rat (*Cricetomys gambianus*, waterhouse) and Wistar rat. M.sc submission at the department of Veterinary Anatomy, Faculty of Veterinary Medicine, Ahmadu Bello University, Zaria, Nigeria.
- Chao, T.I., Kasa, P. and Wolf, J.R (1997). Distribution of astroglia in the glomeruli of the rat main olfactory bulb: exclusion from the sensory subcompartment of neuropil. *Journal of Comparative Neurology*. 388:191-210.  
[https://doi.org/10.1002/\(sici\)1096-9861\(19971117\)388:2%3C191::aid-cne2%3E3.0.co;2-x](https://doi.org/10.1002/(sici)1096-9861(19971117)388:2%3C191::aid-cne2%3E3.0.co;2-x)
- Drury, R.A.B. (1980). Carlton's histological techniques. Oxford University Press U.S.A. Pp. 44-52.  
<https://doi.org/10.1093/odnb/9780192683120.013.31049>
- Fletcher, W. (2006). Brain Gross Anatomy from the lab manual for CVM 6120 In: Veterinary Neurology, Supported by University of Minnesota, College of Veterinary Medicine. University of Minnesota press Pp. 1-25
- Hamilton, K. A., Heinbockel, T., Ennis, M., Szabó, G., Erdélyi, F. and Hayar, A. (2005). Properties of external plexiform layer interneurons in mouse olfactory bulb slices. *Neuroscience*, 133(3): 819–829.  
<https://doi.org/10.1016/j.neuroscience.2005.03.008>
- Herron, M.D. and Waterman, J.M. (2004). "Xerus erythropus". *Mammalian Species*: Number 748. American Society of Mammalogists Pp. 1–4.  
<https://doi.org/10.1644/748>
- Ibe, C.S., Ikpegbu, E. and Nlebedum, U.C. (2018). Structure of the Main Olfactory Bulb and immunolocalisation of Brain-Derived Neurotrophic Factors in the Olfactory Layers of the African Grasscutter (*Thryonomys swinderianus*). *Alexandria Journal for Veterinary Science*. 56:1-10.  
<https://doi.org/10.5455/ajvs.278580>
- Joanna, M.E., Nathan, J.C. and Nicola, S. (2005). Cache protection strategies by western scrub-jays, *Aphelocoma californica*: implications for social cognition. *Animal Behaviours*, 70(6):1251-1263.  
<https://doi.org/10.1016/j.anbehav.2005.02.009>
- Kiernan, J.A. (2007). Histochemistry of staining methods for normal and degenerating myelin in the central and peripheral nervous systems. *Journal of Histotechnology*, 30(2):87-106.  
<https://doi.org/10.1179/his.2007.30.2.87>
- Kosaka, T. and Kosaka, K. (2009) Olfactory bulb anatomy. In: Squire LR (ed). Encyclopedia of Neuroscience, 7<sup>th</sup> ed. Oxford University Press, Oxford, Pp. 59-69. <https://doi.org/10.1016/b978-008045046-9.01686-7>
- Legg, E.W. and Clayton, N.S. (2014). Eurasian jays (*Garrulus glandarius*) conceal caches from onlookers. *Animal Cognition*, 17(5): 1223-1226.  
<https://doi.org/10.1007/s10071-014-0743-2>
- Molina, A.M., Moyano, M.R., Nyala, N., Lora, A.J., and Serrano-Caballero, J.M. (2015). Analysis of anaesthesia with ketamine combined with different sedatives in rats, *Journal of Veterinary Medicine*. 60(7):368-375. <https://doi.org/10.1722/1/8384-vetmed>.
- Moore, K. L. and Persaud, T.V.N. (2003). The Developing Human (Clinically Oriented Embryology), 8th Edition. Saunders Elsevier, Philadelphia, PA. USA, Pp. 380-392.
- Mori, K., Takahashi, Y.K., Igarashi, K.M. and Yamaguchi, M. (2006). Maps of odorant molecular features in the Mammalian olfactory

- bulb. *Physiology Review*, 86(2): 409–433. <https://doi.org/10.1152/physrev.00021.2005>
- Ngwenya, A., Patzke, N., Ihunwo, A.O. and Manger, P.R. (2011) Organization and chemical neuroanatomy of the African elephant (*Loxodonta africana*) Olfactory bulb. *Brain Structure and Function* 216:403-416. <https://doi.org/10.1007/s00429-011-0316-y>
- Nzalak, J.O., Ayo, J.O., Neils, J.S., Okpara, J.O. and Onyeanusi, B.I. (2005). Morphometric studies of the cerebellum and forebrain of the Africa giant rat (*Cricetomys gambianus*, waterhouse). *Tropical Veterinarian*, 23:87-92
- Nolte, J. (2007). *Elsevier's Intergrated Neuroscience*. Mosby, an affiliate of Elsevier Inc. Philadelphia, USA, Pp. 47-60.
- Olude, M.A; Ogunbunmi, T.K; Olopade, J.O and Ihunwo, A.O. (2014). The olfactory bulb structure of African giant rat (*Cricetomys gambianus*, Waterhouse 1840) I: cytoarchitecture. *Anatomical Science International*.1-7. <https://doi.org/10.1007/s12565-014-0227-0>
- Paxinos, G and Watson, C. (1998). *The Rat Brain in Stereotaxic Coordinates*. New York, Academic Press. Pp 8-11. <https://doi.org/10.1016/b978-0-12-547620-1.50003-5>
- Ramaswamy, S. (1978) Removal of the brain, A new procedure. *Italian Journal of Anatomy and Embryology*,82:105-110.<https://doi.org/10.1007/bf00317957>
- Shiple, M., Ennis, M. and Puche, A. (2004). Olfactory system. In: Paxinos G, editor. *The rat nervous system*. 3rd ed. CA: Elsevier Academic Press, USA, Pp 923–964. <https://doi.org/10.1016/b978-012547638-6/50030-4>
- Shoshani, J., Kpsky, W.J. and Marchant, G.H. (2006). Elephant brain. Part I: Gross morphology, functions, comparative anatomy and evolution. *Brain Research Bulletin*, 70: 124-157. <https://doi.org/10.1016/j.brainresbull.2006.03.016>
- Smitka M, Abomaali N. and Witt, M. (2009). Olfactory bulb ventricles as a frequent finding in magnetic resonance imagery studies of the olfactory system. *Neuroscience* 162:482-485. <https://doi.org/10.1016/j.neuroscience.2009.04.058>
- Thorington, R. and Hoffmann, R. (2005). *Family Sciuridae. Mammal species of the world. A taxonomic and geographic reference*. John Hopkins University press, Baltimore, UK. P754-818.
- Wei, Q., Zhang, H. and Guo, B. (2008). Histological structure difference of dog's olfactory bulb between different age and sex. *Zoological Research*, 29(5): 537-545.<https://doi.org/10.1111/azo.12178>