

## Conjoined Twins in One-humped Camel (*Camelus dromedarius*)

<sup>1\*</sup>Gambo, B.G., <sup>1</sup>Yahaya, A., <sup>2</sup>Sonfada, M.L and <sup>3</sup>Olopade, J.O

<sup>1</sup> Department of Veterinary Anatomy, University of Maiduguri, Maiduguri, Nigeria

<sup>2</sup> Department of Veterinary Anatomy, Usmanu Danfodiyo University, Sokoto, Nigeria

<sup>3</sup> Department of Veterinary Anatomy, University of Ibadan, Ibadan, Nigeria

\*Author for Correspondence: babaganag39@gmail.com: Tel. +234(0)8035665895

---

### Article History

**Received:** 24<sup>th</sup> Feb, 2020

**Revised:** 16<sup>th</sup> March, 2020

**Accepted:** 17<sup>th</sup> March, 2020

**Published:** 31<sup>st</sup> March, 2020

### Abstract

This report describes a case of thoraco-omphalopygopagus type of conjoined twins in one-humped camel (*Camelus dromedarius*) in Maiduguri, Nigeria. The conjoined camel fetuses were observed during postmortem at the Maiduguri Metropolitan Abattoir. Necropsy and radiography were carried out. There was thoracolumbar scoliosis in both fetuses, common thoracic and abdominal cavities separated by a diaphragm, fully developed but separate body features such as head, neck, limbs and tail. The heart, respiratory system and spleen were also separate but the fetuses shared a single large liver. Each fetus had separate gastrointestinal tract from mouth to cranial two third of jejunum that fused to form single caudal one third of jejunum and extended to the rectum. There were four ureters connected to a single bladder. There were bilateral kidneys and testicles located in the abdomen of each fetus. The findings of this report may assist to surgically resolve such cases when delivered alive for the survival of the twins or one of them. To the best of our knowledge, this is the first report of thoraco-omphalopygopagus twin in one-humped camel.

**Key words:** Conjoined; thoraco-omphalopygopagus; twins; One-humped Camel.

### Introduction

Conjoined twins are monozygotic and arise from a single ovum (Kumar *et al.*, 2014). Incomplete separation of the two portions of the embryo results in conjoined twins (Mazaheri *et al.*, 2014). There are nearly a dozen different types of conjoined twins. Among the most common classification are thoracopagus, omphalopagus, pygopagus, ischiopagus and craniopagus twins. These twins may share some visceral organs such as heart, liver, biliary tract and upper digestive tract, which, depending on how closely they are joined, makes it nearly impossible to separate them and save them both (Kaufman, 2004). Reports of fetal monstrosities and anomalies of different types have been reported in cattle (Roberts, 1971). Conjoined twins are reported to be more commonly seen in cattle compared to other domestic animals (Noden and de Lahunta, 1985). Conjoined twins occasionally occur in dogs (Nottidge *et al.*, 2007) and cats, and are very rare in horses, but they are not uncommon in sheep (Kamali *et al.*, 2014) and pigs. Recently, Mazaheri *et al.*, (2014) reported a case of thoraco-omphalopygopagus tribrachius tetrapus type of conjoined twins in lamb. Thoraco-omphalopagus types of conjoined twins in goat have also been reported by Binati and Riccaboti (2011). Kabar newspaper in 2010 reported a case of conjoined twins in camel that died shortly after birth in north-

western town of Hail in Saudi Arabia. We hereby report the occurrence of thoraco-omphalopygopagus type of conjoined twins in one-humped camel (*Camelus dromedarius*) in Maiduguri, north-eastern Nigeria.

### Materials and Methods

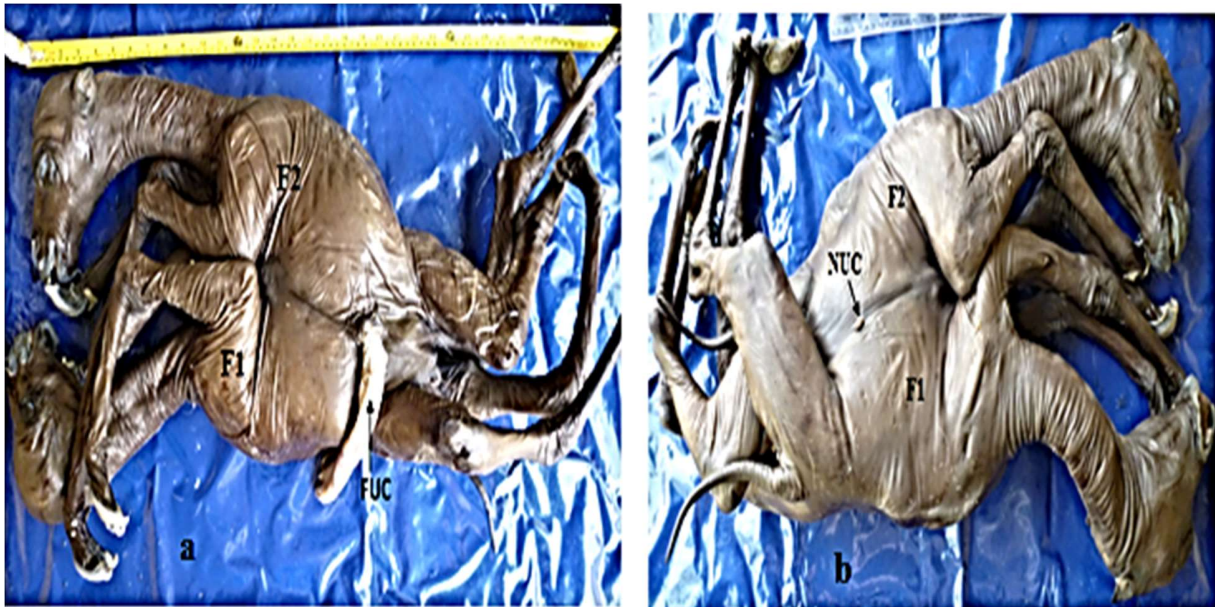Conjoined camel fetuses were obtained as fetal waste from Maiduguri Metropolitan Abattoir, Maiduguri, North-eastern Nigeria. The fetuses were presented to the Gross Anatomy and Embryology Laboratory of the Department of Veterinary Anatomy, University of Maiduguri. Careful and systematic examination and measurements of the conjoined twins were carried out. The fetuses were aged using developmental horizons (Sonfada *et al.*, 2012). An X-Ray was taken, after which they were embalmed by injecting 10% formalin into various sites then dipped into a 40% formalin tank for two weeks and were later dissected, examined and findings recorded.

### Results

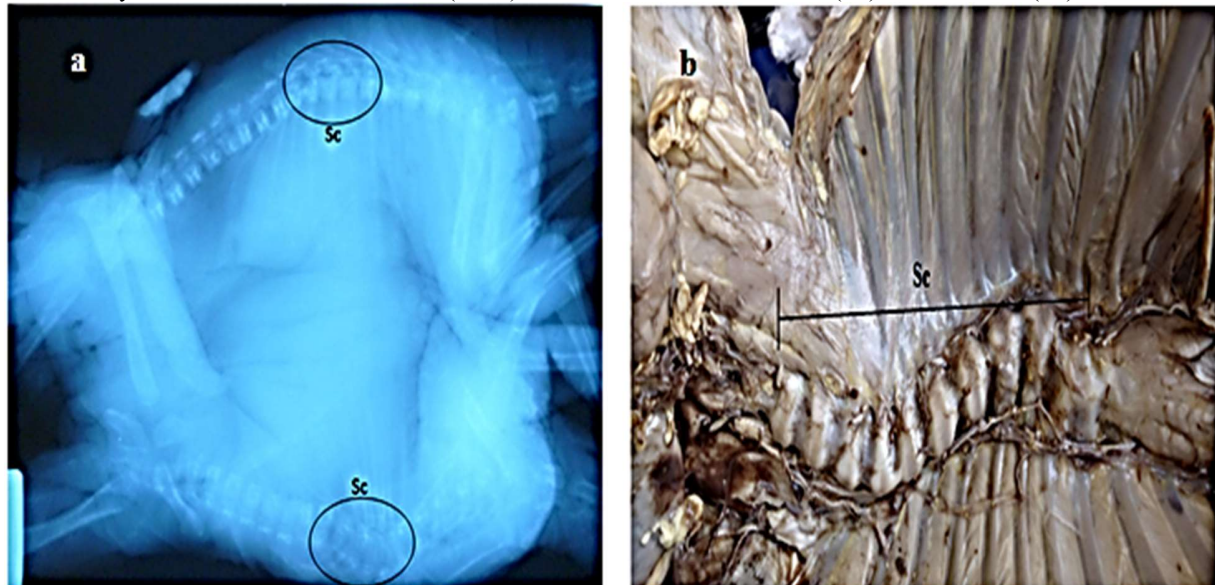
The fetuses were in their second trimester of pregnancy having total weight of 10.5kg. The first fetus (F1) had crown-rump lengths of 62 cm, while that of the second fetus (F2) was 57 cm. Both fetuses were male, ventrally joined from manubrium

sterni to the inguinal region (Thoraco-abdominopelvic) (Figure 1), sharing one fully formed umbilical cord on one side and a non-functional rudimentary cord on the other side (Figure 1). Thoracolumbar scoliosis was observed in both fetuses (Figure 2). The fetuses shared common thorax and abdominal cavities separated by a diaphragm, and had fully developed separate body features (head, neck, limbs and tail) with no anal openings. Each fetus had separate heart, respiratory tract, lungs, spleen, and gastrointestinal tract from mouth to cranial two-third of the jejunum, after which they

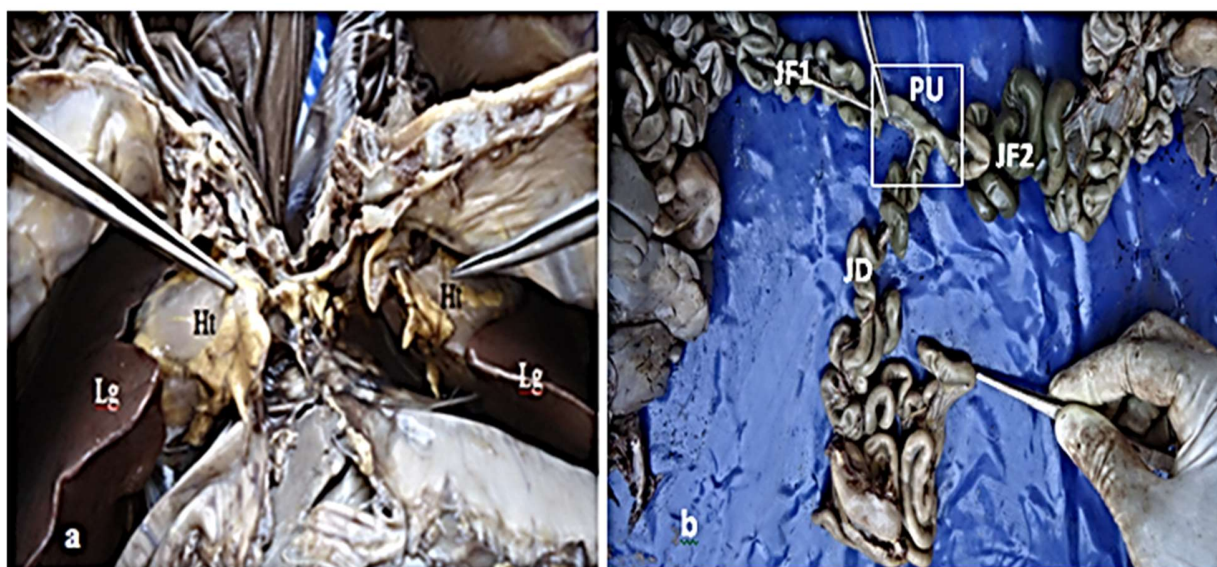
unite in a "T" shaped pattern and continued as a single distal one third of jejunum (Figure 3), followed by ileum and large intestine up to the rectum which further bifurcated to supply each fetus in a similar "T" shaped pattern. The conjoined twins had one large liver (Figure 4) with distinct lobulations only on the visceral surfaces. Single bladder received four ureters, there were bilateral kidneys and testicles in each fetus located abdominally. Each fetus had a penis and prepuce with penis protruding in F1, but not protruding in F2 (Figure 5).



**Figure 1.** Conjoined camel twin fetuses: **a** showing single functional umbilical cord (FUC), and **b** showing rudimentary nonfunctional umbilical cord (NUC) on the other side of fetus one (F1) and fetus two (F2).



**Figure 2.** Conjoined camel twin fetuses: **a**, Radiograph and **b**, dissected specimen, showing thoracolumbar scoliosis (Sc).

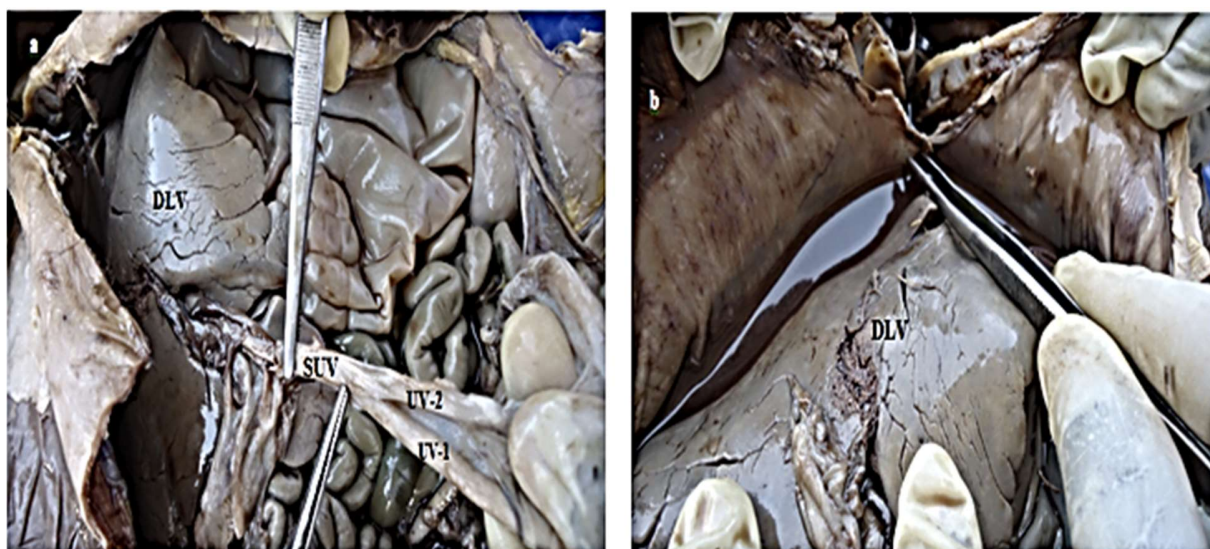


**Figure 3:** a, Thoracic cavity of conjoined camel twin fetuses showing 2 hearts (Ht) and lungs (Lg), and b, Jejunum of the fetuses (F1 and F2) unite (PU) to form single distal one-third jejunum (JD).

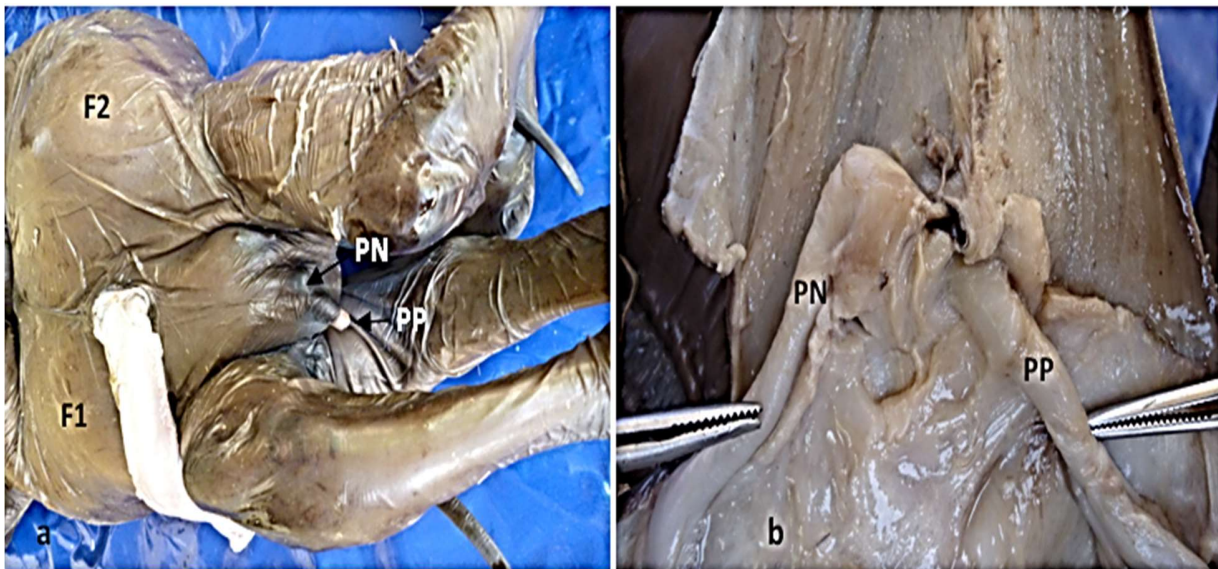
### Discussion

The occurrence of congenital malformations depends on the breed, species, geographical location and several other factors. Several reports pointed that about 1.5% to 6% of all live-born domestic animals present at least one visible congenital malformation (Hyttel *et al.*, 2010). The origin of congenital malformation is regarded as a result of interaction between the environment of the developing embryo and its genetic makeup (Kamali *et al.*, 2014).

Siamese or conjoined twinning are non-hereditary tetratologic abnormalities. They are monozygotic in origin, due to incomplete subdivision of single embryo into two components, mostly at the stage of primitive streak development (Noden and de Lahunta, 1985). This report presents a typical case of thoraco-omphalopygopagus conjoined twinning, as fusion of the two fetuses extends from the manubrium sterni to the pelvic region. As a result of this fusion, a common thorax and abdomino-pelvic cavities were created. It was reported that the wider



**Figure 4.** Opened abdominal cavity of conjoined camel twin fetuses showing: Umbilical vein one (UV- 1) and umbilical vein (UV-2) uniting to form single umbilical vein (SUV) that entered the liver in a, and the diaphragmatic surface of the large single liver (DLV) in both a and b.



**Figure 5.** Inguinal region of conjoined camel twin fetuses showing: Penis protruding prepuce (PP) of fetus one (F1), and prepuce with no visible penis protruding it (PN) in fetus two (F2) in **a**, and skin reflected in **b**.

extend of the fusion of the thoracic cage, the higher the chance of abnormalities associated (Cywes *et al.*, 1997; Mazaheri *et al.*, 2014).

It has been reported that in conjoined thoracopagus twins, the hearts were of great significance (Cywes *et al.*, 1997) and cardiac abnormalities were seen in almost any type of fusion (Ambar *et al.*, 2010), and (Mazaheri *et al.*, 2014) stated that thoracopagus twins mostly present cardiac anomalies with about 90% cases of shared pericardium. In this study, the two hearts are of unequal sizes, with F1 having larger heart than F2, but each in a separate pericardium. This report describes thoraco-omphalopygopagus type of conjoined twins in one-humped camel (*Camelus dromedarius*), for the first time in Maiduguri, Nigeria.

The findings of this report may assist to surgically resolve such cases when delivered alive for the survival of the twins or one of them. While we admit that genetic and toxicology tests not done, we recommend that in an environment like Nigeria where prevalence rate of congenital abnormalities is low; researchers should partner with butchers and abattoir workers so that cases observed by them can be referred for scientific reporting.

#### Acknowledgements

The authors wish to thank Dogoli Mohammed and Abubakar Goni Muhammad for the technical assistance in Embalming and Radiography respectively.

#### Conflict of interest

The authors declare that there is no conflict of interest.

#### References

- Ambar, S.S., Halkati, P.C. and Patted, S.V. (2010). Twin Heart with a Fused Atria and Separate Ventricles in Conjoined Twins. *Ann. Pediatr. Cardio.*, 3(2): 196-198.
- Binati, D. and Riccaboti, P. (2011). Thoraco-omphalopagus Conjoined Twins in Chamois-coloured Domestic Goat kids. *Anat. Histol. Embryol.*, 41(3): 159-162.
- Cywes, S., Millar, A.J. and Rode, H. (1997). Conjoined Twins-The Cape Town experience. *Pediatr. Surg. Int.*, 12(4) 234-248.
- Hyttel, P., Sinowatz, F. and Vejlsted, M. (2010). *Essentials of Domestic Animal Embryology*. Ed., Betteridge, K. British, Sanders Elsevier, pp 338-348.
- Kamali, Y., Khaksar, Z., Sharaki, A.R., Rasouli, B. and Kajbafi, M. (2014). A Detailed Systematic Study of Monocephalic Symmetric Twin Lambs. *Open Vet. J.*, 4(2): 124-127.
- Kaufman, M.H. (2004). The Embryology of Conjoined Twins. *Childs Nervous System* 20(8-9): 508-525.
- Kumar, S., Pandey, A.K., Kushwaha, R.B., Sharma, U., and Dwivedi D.K. (2014). Dystocia due to Conjoined Twin Monster in a Cow. *Indian J. Anim. Reprod.*, 35(1): 54-56.
- Mazaheri, Y., Nourinezhad, J., Ranjbar, R., Khaksary, M., Ghadiri, A., and Lombeshkon, H. (2014). A Case of Conjoined Twins (Thoraco-omphalopygopagus Tribrachius Tetrapus) in Lamb. *Vet. Res. Forum* 5(1): 73-76.
- Noden, D.M. and de Lahunta, A. (1985). *The Embryology of Domestic Animal. Development Mechanisms and Malformations*. Baltimore, USA, Williams and Wilkins, pp 44-45.

- Nottidge, H.O., Omobowale, T.O., Olopade, J.O., Oladiran, O.O., and Ajala, O.O. (2007). A Case of Craniothoracopagus (Monocephalus Thoracopagus Tetrabrachius) in Dog. *Anatomia Histologia Embryologia* 36: 179-181.
- Roberts, S.J. (1971). *Veterinary Obstetrics and Genital diseases*. 2<sup>nd</sup> edn. Scientific Book Agency, Lucknow, India.
- Sonfada, M.L., Kwari, H.D., Umar, A.A., Shehu, S.A., Wiam, I.M., Hena, S.A., Danmaigoro, A., and Onyeausi, B.I.(2012). Fetal Age Estimation in Dromedarian Camel using Developmental Horizons. In the Proceedings of 3<sup>rd</sup> Conference of the International Society of Camelid Research and Development, at the Department of Animal and Veterinary Sciences, Sultan Qaboos University, Muscat, Sultanate of Oman. 29<sup>th</sup> Jan. - 1<sup>st</sup> Feb. 2012. pp 115-117.