

**Trichobezoar: Case Report and Literature Review**

Moawia Elbalal Mohammed<sup>1\*</sup>, Mustafa Idris Abdelrahman<sup>2</sup>,  
Elmustafa O. M<sup>2</sup>

**Abstract:**

A bezoar is an agglomeration of food or foreign material in the intestinal tract usually noticed in ruminants. It can be classified as trichobezoar (hair) or phytobezoar (plant material). Stomach is the commonest site for bezoar formation, which may result in obstruction, gastric wall ulceration and malnutrition. They present with abdominal pain, small bowel obstruction or malnutrition. Trichobezoars are associated with trichotillomania. This is a case report of trichobezoar in a Sudanese girl who presented with abdominal pain. This to our knowledge is the first case to be reported from Sudan.

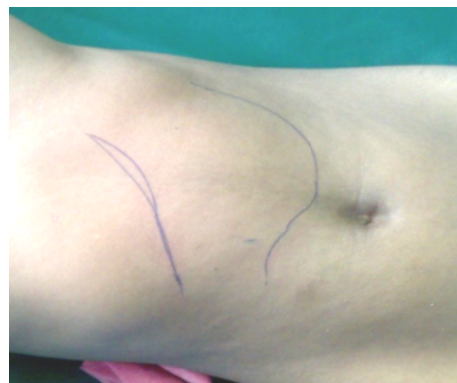**Key words:** Bezoar, Trichobezoar, Trichotillomania, Sudan.

**B**ezoars are incompletely digested food or fibrous material that may accumulate and cause intestinal obstruction. The term bezoar comes from either the Arabic "badzehr" or Persian "pazehr" or Hebrian "beluzaar" that all mean antidote or counter poison<sup>1</sup>. Trichobezoars [ingestion of hair] are most common in children and adolescents with behavioral disorders<sup>2</sup>. Symptoms of abdominal pain and intestinal obstruction are related to trichobezoar size and 2500gm has been reported<sup>3</sup>. Its complications include bleeding, obstruction, gut perforation, acute pancreatic necrosis, obstructive jaundice, hypochromic anaemia, vitamin B12 deficiency and abdominal mass<sup>4</sup>. Some patients may not have evidence of hair loss. However, alopecia is a common accompanying sign<sup>5</sup>. The diagnosis is based on history, physical examination, and radiologic evidence. Urgent surgical intervention may be required<sup>6,7</sup>.

**Case report:**

A 17-yearold Sudanese girl presented with six months history of a mild and dull-aching upper abdominal pain not related to meals. She complained of early satiety, but no vomiting or weight loss. She admitted to pull

and swallow her hair. Clinically she was rather short depressed, shy and poorly responding to questions. Physical examination was revealed epigastric mass 15x15cm, firm and tender (Fig 1). Laboratory studies were within normal limits but CT scan of the abdomen showed distended stomach with multiple well defined, linear mass like a bag full of worms filling the posterior aspect of the gastric wall and extending down to the duodenum (Fig2). Endoscopy showed a huge mass of hair occupying the lumen of the stomach and reaching the duodenum(Fig3).



**Figure 1:** the epigastric mass

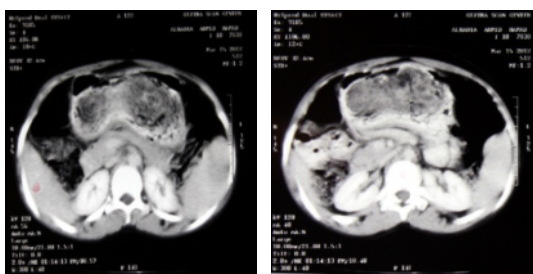
Removal of the bezoar was initially tried endoscopically using a dormia basket and a polypectomy snare without success. The mass was then removed surgically. It measured 9 x 22 cm ad weighted 1000gm (Fig 4 and 5). The postoperative course was uneventful. Psychiatric consultation was requested.

1,2.Department of medicine, Faculty of Medicine, University of Gezira.

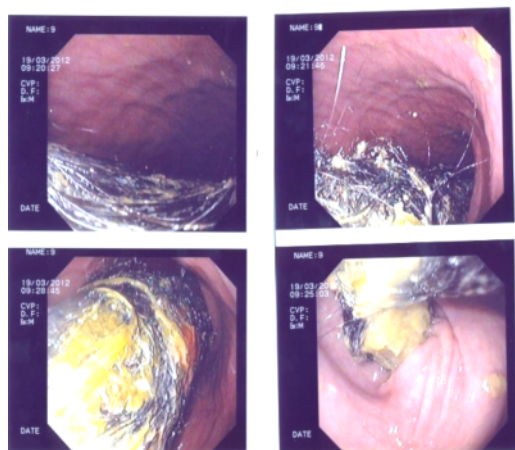
\*Correspondant:moawiaelbalal@yahoo.com.

**Discussion:**

Trichobezoars are gastrointestinal masses formed from ingested hair. They grow slowly in the stomach and sometimes extend to the small bowel<sup>7</sup>. The typical patient is a teenage girl, however, trichobezoar has been described in all age groups<sup>8</sup>. The disorder has a female preponderance among the age group of 10 - 19 years<sup>2</sup>. Trichobezoars are generally seen in patients, suffering from trichotillomania<sup>9</sup>.



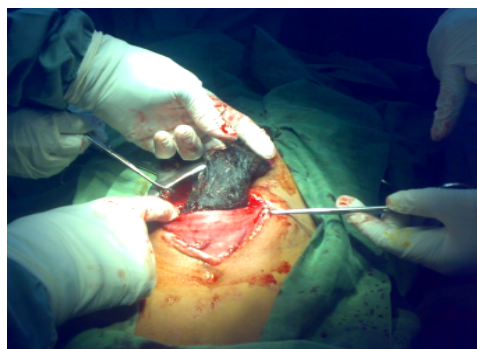
**Fig 2:** CT abdomen showing a worms-like mass.



**Fig 3:** Endoscopic appearance of the trichobezoar

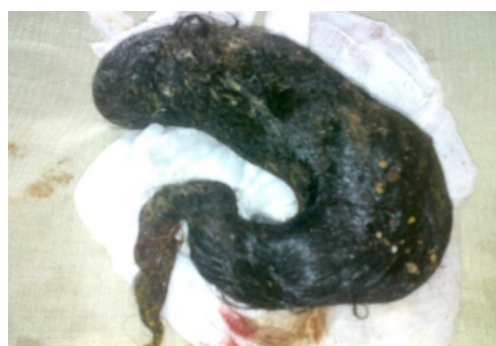The swallowed hair becomes black due to the denaturation of hair protein by the gastric acid<sup>10</sup>. The symptoms depend on the size and time of presentation. The bezoar we have extracted was weight of 1000gm compared to that reported in the literature<sup>3</sup> which was 2500gm. Our patient's symptoms are in keeping with that mentioned in the literature as epigastric pain, weight loss, poor appetite, vomiting and halitosis<sup>6</sup>. Lamerton sign describes the large firm epigastric mass<sup>11</sup>. Our patient admitted ingesting her own hair; however alopecia is a common accompanying

sign, yet, some patients, might not show evidence of hair loss<sup>7</sup>. Unlike our case pressure necrosis was reported along the lesser curvature in 10% of the patients<sup>9</sup>.



**Fig 4:** gastrostomy showing the bezoar

Fortunately unlike our case, subphrenic abscess was described in two cases<sup>12</sup>. Likewise, thirteen cases were reported as Rapunzel syndrome where a long tail of hair strands extends from the main mass in the stomach along the small bowel to reach the caecum or beyond, only<sup>13</sup>. Iron deficiency anaemia is a common association<sup>14</sup>. CT scan shows well defined ovoid intraluminal heterogeneous mass<sup>15</sup>. The diagnosis is based on clinical suspicion and confirmed on conventional radiography and barium meal study<sup>16</sup>. Sonographic features are not pathognomonic, but a hyper echoic curvilinear dense strip at the anterior margin of the lesion with acoustic shadowing may suggest the diagnosis<sup>17</sup>.



**Fig 5:** The extracted bezoar

Small trichobezoars can be removed endoscopically from the stomach like any foreign body by various methods and techniques e.g: after fragmentation by water, jet or injecting cellulose, or a drill device or a

tripod forceps, or polypectomy snare, or a dormia basket, or a mechanical lithotripter or Laser<sup>18</sup>. However, surgery remains the treatment of choice<sup>7</sup>. Laparoscopic removal of large trichobezoars was attempted, but it was all tedious and time consuming<sup>19</sup>.

#### Conclusion

Trichobezoar is rare for which high suspicion index is required for its diagnosis particularly when psychic disorder is suspected.

#### References:

1. Elgood C. A. Treatise on the bezoar stone. *Ann Med History* 1935; 7:73-80.
2. DeBalkey M, Ochsner A. Bezoars and concretions. *Surgery* 1938; 4:934-997.
3. Naraez RJ, Pascasio AJM, Pabon JM, et al. Giant gastric and duodenal trichobezoar. Presentation of a case and review of the literature. *Gastroenterol Hepatol* 1995; 18:87-90.
4. Phillips MR, Zaheer S, Drugas GT. Gastric trichobezoar: case report and literature review. *Mayo Clin Proc.* 1998; 73:653-656.
5. Konen O, Rathus V, Shapiro M. Unsuspected trichobezoar in a child with short hair. *Am J Roentgenol.* 2001; 176:258-259.
6. Kaushik NK, Sharma YP, Negi A, et al. Images-gastric trichobezoar. *Indian J Radiol Imaging.* 1999; 9:137-139.
7. Andrus CH, Ponsky JL. Bezoar: classification, pathophysiology and treatment. *Am J Gastroenterol* 1988; 83:476-478.
8. Guerrier G. Trichobezoar in a 3-year-old girl deprived of affection. *Pediatric* 1968; 23:559-623.
9. Avissar E, Goldberg M, Lernau O. Bezoar induced ulceration and perforation of the upper gastrointestinal tract in mentally retarded patients. *Pediatr Surg Int* 1994; 9:279-280.
10. Grosfeld JL, Schreiner RL, Franken EA, et al. The changing pattern of gastrointestinal bezoars in infants and children. *Surgery* 1988; 88:425-432.
11. Lamerton AJ. Trichobezoar: two case reports- a new physical sign. *Am J Gastroenterol* 1984; 79:354-360.
12. Koplewitz BZ, Daneman A, Fields S, et al. Case 29: Gastric Trichobezoar and subphrenic abscess. *Radiology* 2000; 217:739-742.
13. Vaughn E, Sawyers J, Scott H. The Rapunzel syndrome: an unusual complication of intestinal bezoar. *Surgery* 1968; 63:339-382.
14. McGehee FT, Buchanan GR. Trichopagia and trichobezoar: etiologic role of iron deficiency anaemia. *J Paediatr* 1980; 97:946-948.
15. Newman B, Girdany BR. Gastric trichobezoars-sonographic and computed topographic appearance. *Pediatr Radiol* 1990; 20:526-527.
16. Harris V, Hanely G. Unusual features and complications of bezoars in children. *Am J Roentgenol Radium Ther Nucl Med* 1975; 123:742-745.
17. Malpani A, Ramani SK, Wolverson MK. Role of sonography in trichobezoars. *J Ultrasound Med* 1988; 7: 661-664.
18. Wang YG, Seitz U, Li ZL, et al. Endoscopic management of huge bezoars. *Endoscopy* 1998; 30:371-374.
19. De Backer A, Van Nooten V, Vandenplas Y. Huge trichobezoar in 10 years-old girl: case report with emphasis on endoscopy in diagnosis and therapy. *J Paediatric Gastroenterol and Nutr* 1999; 28:513-515.