

**Ultrasound- guided fine needle aspiration cytology and cell block in the diagnosis of focal liver lesions at Khartoum Hospital, Sudan**

Ahmed A. Mohammed<sup>1</sup>, Shawgi Elsiddig<sup>2</sup>, Mohamed Abdullhamid<sup>2</sup>, Gasim I. Gasim<sup>3</sup> and Ishag Adam<sup>3\*</sup>

**Abstract**

**Background:** The appropriate clinical management of various hepatic lesions depends on accurate diagnosis. Fine needle aspiration and cell block have gained popularity because they are convenient, minimally invasive, quick and have good performance profiles.

**Objective:** To investigate the cytomorphological features of distinctive non-neoplastic and neoplastic lesions of the liver and to evaluate the sensitivity, specificity and diagnostic accuracy of ultrasound- guided (USG) fine needle aspiration cytology (FNAC) and cell block in the diagnosis of liver diseases at Khartoum Teaching Hospital.

**Method:** A cross-sectional study was conducted at Khartoum Teaching Hospital, Sudan during the period of November 2008 to October 2011. One hundred and five cytological materials were collected from patients with focal liver lesions who referred after initial clinical and radiological assessment for ultrasound-guided fine needle aspiration cytology (USG -FNAC).

**Results:** The age of the patients ranged from 5- 60 years and 64 (61%) of these patients were males. Out of 105 investigated samples 76 (72.4%) and 41(39.0%) were malignant by cytology and cell block respectively. Out of these 105 samples, 71 were investigated by both cytology and cell blocks and were included in the final analyses of the FNAC in comparison to cell block. The sensitivity, specificity, positive predictive value and negative predictive value of the cytology were 100% (93.0 – 100%), 63.3% (45.2 – 79.0%), 78.8% (66.2 – 88.3%) and 0 (0 – 14.6%), respectively.

**Conclusion:** Thus, USG -FNAC is a sensitive but not specific method in differentiating the benign and malignant focal liver lesions. Differentiation between primary liver malignant lesions and metastatic lesion needs adjunct technique

**Key words:** neoplastic lesion, non-neoplastic lesion

**T**he liver is a common site for various non-neoplastic and neoplastic lesions such as primary liver tumors (benign or malignant), metastatic deposits, congenital and acquired cysts, abscesses and granulomas. The appropriate clinical management of liver lesions depended on accurate diagnosis which is a dilemma<sup>1,2</sup>.

Ultrasound-guided (USG) fine needle aspiration cytology (FNAC) is an accurate, rapid, sensitive and specific method for diagnosis of the focal liver lesions<sup>3</sup>.

However, some inflammatory lesions or diffuse liver diseases may appear as non-

homogeneous lesions, such lesions can also be sampled by FNAC to exclude neoplasm<sup>4</sup>. The cell block technique should be used for processing the residual material remaining after completion of cytologic preparation. This material often contains valuable diagnostic evidence and tissue fragments that cannot be processed by cytology. Major advantage of cell block methods is ability to perform multiple immunocytochemistry or other special stains if needed<sup>5</sup>.

In Sudan, cancer is the third leading cause of death-after malaria and pneumonia-which is accounting for 5% of all deaths. Liver cancer accounts for about 7.5% of all cancers [6]. The aim of this study is to evaluate the role of the USG -FNAC in differentiation of focal hepatic lesions as well as to interpret the findings in combination with those obtained by cell block and selected immunohistochemical markers.

1.Faculty of Medicine, the National Ribat University  
2.Faculty of Medical Laboratory Sciences, Omdurman University  
3.Faculty of Medicine, University of Khartoum  
\*Correspondence to Ishag Adam  
P.O. Box 102, Khartoum, Sudan.  
Email:ishagadam@hotmail.com

## Materials and Methods

A cross-sectional study was conducted at Khartoum Teaching Hospital during the period of November 2008 to October 2011. After signing an informed consent, patients with clinical, biochemical and radiological evidence of liver lesion with normal prothrombin time were subjected to USG - FNAC. The patients with hemangioma and hydatid disease of liver diagnosed by ultrasound were excluded to avoid undue complications. The cytological material was obtained using 20 or 22-gauge, 90-mm spinal needle which was introduced into the lesion under ultrasound guidance. The smears were stained by May-Grönwald-Giemsa, Papanicolaou, hematoxylin and eosin (H and E) stains. Reticulin, periodic acid-Schiff (PAS), Gram's and Ziehl-Neelson (ZN) stains were done whenever needed. Visible tissue fragments whenever obtained during FNA were studied as cell blocks. Cyto-histomorphological diagnoses were correlated and the specificity, sensitivity and accuracy of FNAC were evaluated.

### Cell Block

After preparation of smears for Pap and diff Quick Stains, the residual material was mixed with formalin, centrifuged at 1500 rpm for 10 minutes the deposit was foiled with filter paper and processed with automatic processing machine to prepare paraffin - embedded block, 3-5u sections were prepared using microtome and from each specimen four slides were stained by H&E, and avidin biotin complex (ABC) procedure for the immunocytochemical markers. .

### Immunohistochemistry

Three sections of 5µm in thickness were obtained from formalin fixed paraffin wax embedded tissue using rotary microtome. Sections required for immunohistochemistry were treated by heat retrieval technique, and were immunostained using avidin biotin technique to detect alpha-fetoproteins (AFP), hepar-1 and cytokeratin. Sections were dewaxed in hot plate oven and cleared in 2 changes of xylene for 2 minutes, then hydrated through ethanol (100%, 90%, 70%, 50%) water 2 minutes for each, then were

retrieved by water bath heat retrieval technique, treated with hydrogen peroxide solution for 15minutes, then washed in phosphate buffer saline (PH7.4) for 5 minutes, treated with protein blocker solution for 15minutes, then treated in primary antibody for 30minutes, rinsed in phosphate buffer saline , then treated with avidin biotin complex for 30minutes, rinsed in phosphate buffer saline , treated with diaminobenzaldehyde (DAB) for 10 minutes, washed in phosphate buffer saline for 5 minutes, counter stained Mayer's haematoxylin for 1 minute, washed and blued in running tap water, dehydrate, cleared and mounted in DPX mount ant.

### Ethics

The study received ethical clearance from the Research Board at the Faculty of Medical Laboratory Sciences, Omdurman University.

### Statistics:

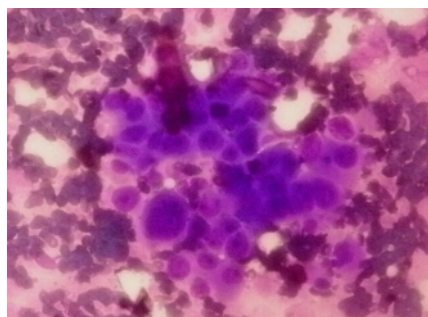
Data were entered in computer using SPSS (statistic package for social sciences) for soft ware version 16.0 for analysis. Sensitivity, specificity, positive predictive value and negative predictive value were calculated. Sensitivity of the cytology was calculated as true positives / (true positive + false negatives), specificity as true negatives/ (true negatives+ false positives), positive predictive value as true positives/(true positives + false positives), negative predictive value as true negatives/(true negatives + false negative)<sup>7</sup>.

### Results

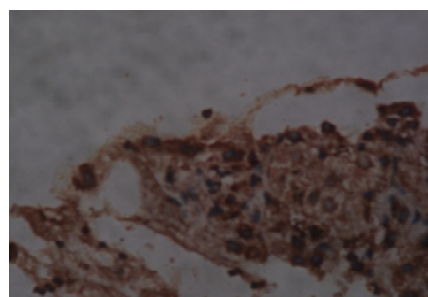
One hundred and five cytological materials were investigated. The majority of the patients having liver lesions were males (64, 61%). The diagnosis by cytology was found to be malignant (72.4%), benign lesion (17.1%), bloody sample (1%), normal hepatocyte (9.5%) and there was no negative sample (sample deficient in cells) where deficient samples were repeated before release of patients. Whereas the diagnosis by examination of cell block was found to be malignant (39%), benign lesion (24.8%), bloody sample (27.6%), normal hepatocytes (3.8%) and (4.8%) of the samples were deficient and no cells were seen. Fifty-two

(73.2%) and 41 (57.7%) samples were positive and malignant by direct cytology and cell block technique, respectively.

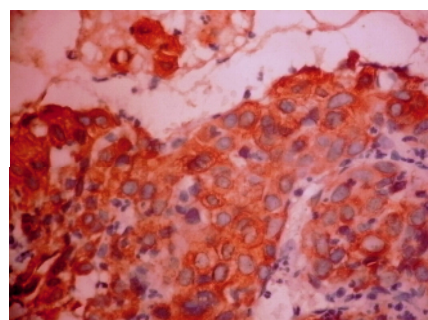
The malignant focal lesions were hepatocellular carcinoma (25.7%), metastatic adenocarcinoma (42%), spindle cell sarcoma (2.9%) and hepatoblastoma (1%), figure 1(A-D).



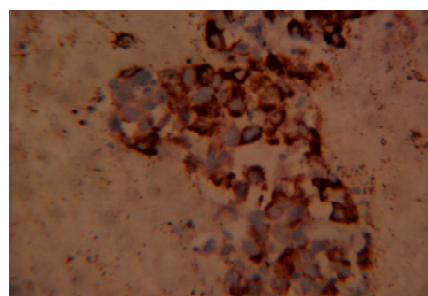
A. Hepatocellular Carcinoma Diff Quick Stain. X40.



B. Cell Block. Positive for Alfa Fetoprotein X40.



C. Cell block positive for Cytokeratin. X40



D. Cell block positive for HepPar1 X40.

Figure 1: Different hepatic lesions diagnosed by US – guided FNAC and cell block at Khartoum Hospital

The 41 positive slides with cell block are also positive by cytology. Out of 30 samples negative with cell block, 11 were positive by cytology 63.3% (45.2 – 79.0). Table1. The sensitivity , specificity, positive and negative predictive values of the cytology were 100% (93.0 – 100 %), 63.3 (45.2 – 79.0%) ,78.8% (66.2 – 88.3) and 46.3 % (0 – 14.6%) respectively. Table 2

**Table 1:** Performance of cytology and cell block in the diagnosis of the liver lesion at Khartoum, Sudan.

		Cytology Results		Total
		+ve	-ve	
Cell block	+ve	41	0	41
	-ve	11	19	30
Total		52	19	71

**Table 2:** Diagnostic performance of cytology using cell block as gold standard at Khartoum, Sudan.

Sensitivity	100 % (93.0 – 100%)
Specificity	63.3 % (45.2 – 79.0%)
+ve predictive value	78.8 % (66.2 -88.3%)
-ve predictive value	0 % ( 0 – 14.6%)

## Discussion

In the current study USG -FNAC was compared with cell block (with immunochemical markers in some cases) in differentiation of focal hepatic lesions. Needle core biopsy has been the gold standard procedure for histopathologic diagnosis of focal hepatic lesions for more than six decades. Recently USG -FNAC has emerged as a minimally invasive, relatively inexpensive and a rapid method of pathologic evaluation of primary or metastatic hepatic masses<sup>8</sup>.

In the current study USG -FNAC has full sensitivity (100%) but low specificity (63.3%) in comparison with cell block. Previous reports showed that the diagnostic accuracy of liver lesions approached 100% and also the diagnostic and subtyping accuracy of liver malignancies significantly improved if the conventional smear and cell block were

combined together<sup>9</sup>. Recently, Swamyet *al.*, observed high diagnostic accuracy of FNAC (97.82%) with a sensitivity and specificity of 96.87 and 100% respectively where histology using core needle biopsy was the gold standard [10]. Generally, the diagnostic accuracy of FNAC of liver ranged between 78-97.8% in the previous reports<sup>1-3</sup>.

In the current study, 27.6% of the samples submitted for cell block histology were bloody samples. The bloody samples were repeated immediately in case of cytological smears whereas cell block adequacy cannot be assessed before hand in the cell blocks. Previously Nithyananda, et al., showed 25 % of the samples were bloody samples and therefore these samples were not investigated and hence the possibility of malignancy was not excluded<sup>15</sup>.

Generally, the problem of scanty samples can be minimized by an immediate on-site cytopathological evaluation which can determine the adequacy of specimens, render a specific preliminary diagnosis. Around one third (32%) of FNACs in various organs were found non-diagnostic because of scant cellularity or poor preservation when performed without immediate on-site evaluation<sup>16</sup>. Previous report has shown that immediate on-site cytopathological examination and cell block preparation from FNACs improved the diagnostic performance and accuracy and decrease the non-diagnostic results<sup>17</sup>.

It is worth to be mentioned that the optimal results and diagnosis of liver lesions depend on multidisciplinary team of clinician, radiologist, cytopathologist and an on-site cytology service with a combined cytohistological approach and immunohistochemistry facility<sup>18</sup>.

### Conclusion:

In this study, USG -FNAC was a sensitive but not specific method in differentiating the benign and malignant focal liver lesions. Differentiation between primary liver malignant lesions and metastatic lesion needs adjunct techniques

### Acknowledgements

Authors would like to thank the entire patient for participation in the study. This work was funded by Omdurman University.

### References

1. Kuo FY, Chen WJ, Lu SN et al. Fine needle aspiration cytodiagnosis of liver tumors. *Acta Cytol* 2004; 48:142-8.
2. Leiman G. Liver and Spleen. In: Orell SR, Sterret GF, Whitaker D, editors. Fine needle aspiration cytology. 4th ed. New Delhi: Churchill Livingstone; 2005. pp. 293-316.
3. Das DK, Tripathi RP, Chachra KL et al. Role of guided fine needle aspiration cytology in diagnosis and classification of liver malignancies. *Trop Gastroenterol* 1997; 18: 101-6.
4. Tsui WM, Cheng F, Lee Y. Fine needle aspiration cytology of liver tumors. *Annal Contemp Diagn Pathol* 1998; 2:79-93.
5. Chandan VS, Faquin WC, Wilbur DC et al. The role of immunolocalization of CD57 and GLUT-1 in cell blocks in fine-needle aspiration diagnosis of papillary thyroid carcinoma. *Cancer* 2006; 108:331-336.
6. Hamad HM. Cancer initiatives in Sudan. *Ann Oncol* 2006; Suppl 8:32-36.
7. Harper R, Reeves B. Reporting of precision of estimates for diagnostic accuracy: a review. *BMJ* 1999, 318:1322-1323.
8. Jain D. Diagnosis of hepatocellular carcinoma: fine needle aspiration cytology or needle core biopsy. *J Clin Gastroenterol* 2002; 35(5 Suppl 2):S101-8.
9. Ceyhan K, Kupana SA, Bektaş M et al. The diagnostic value of on-site cytopathological evaluation and cell block preparation in fine-needle aspiration cytology of liver masses. *Cytopathology* 2006; 17:267-74.
10. Swamy MC, Arathi C, Kodandaswamy C. Value of ultrasonography-guided fine needle aspiration cytology in the investigative sequence of hepatic lesions with an emphasis on hepatocellular carcinoma. *J Cytol* 2011; 28:178-84
11. Ramdas A, Chopra R. Diagnostic accuracy of fine needle aspiration cytology of liver lesions. *J Cytol* 2003; 20:121-3.
12. Cochand-Priollet B, Chagnon S, Ferrand J et al. Comparison of cytologic examination of smears and histologic examination of tissue cores obtained by fine needle aspiration biopsy of the liver. *Acta Cytol* 1987; 31:476-80.
13. França AV, Valério HM, Trevisan M et al. Fine needle aspiration biopsy for improving the diagnostic accuracy of cut needle biopsy of focal liver lesions. *Acta Cytol* 2003; 47: 332-6.

15. Nathan NA, Narayan E, Smith MM et al. Cell block cytology. Improved preparation and its efficacy in diagnostic cytology. *Am J Clin Pathol* 2000; 114: 599-606.
16. Nasuti JF, Gupta PF, Baloch ZW. Diagnostic value and cost –effectiveness of on-site evaluation of fine-needle aspiration specimens: review of 5688 cases. *Diagn Cytopathol* 2002; 27:1–4.
17. Baloch ZW, Tam D, Langer J et al. Ultrasound-guided fine-needle aspiration biopsy of the thyroid: role of on-site assessment and multiple cytologic preparations. *Diagn Cytopathol* 2000; 23:425–9.