

Neurological Manifestations of Dural Sinus Thrombosis

Abbashar Hussein*, Mohammed Abubaker Elnager, Hisham Hamdalla, Amira Sidig,
Husam A M Ali and Mohammed O EH Gadour

Abstract

Background: Dural sinus thrombosis is a clinical syndrome that has a diversity of signs and symptoms that can be easily misinterpreted with other common neurological diseases such as brain infections.

Objective: to study the clinical presentation of dural sinus thrombosis among Sudanese patients seen at Elshaab Teaching Hospital.

Methodology: This is a prospective, descriptive, cross sectional, hospital based study conducted in Elshaab Teaching Hospital- Khartoum Sudan, in the period from November 2008 to July 2010. All adult Sudanese patients with dural sinus thrombosis who were admitted to the hospital and accepted to participate in the study during the period from November 2008-July 2010 (50 patients) were enrolled. History, clinical examination and relevant investigations including MRI were done for all patients. Data were collected, analyzed, conclusions drawn and recommendations stated.

Results: Females (98%) in child bearing age were mostly affected. Delivery and pregnancy were the common risk factors; head ache, neck pain and stiffness were the frequent neurological symptoms. Papilledema was the commonest neurological finding. Saggital sinus thrombosis was found to be the major radiological finding and great majority of patients showed remarkable improvement with treatment.

Conclusion: Dural sinus thrombosis is uncommon neurological problem, however the diagnosis should always be considered in the right clinical setting, as it is a treatable condition

Key Word: dura mater, subarachnoid, cerebrospinal fluid.

The dural venous sinuses are venous channels found between layers of dura mater in the brain. They receive blood from internal and external veins of the brain, receive cerebrospinal fluid (CSF) from the subarachnoid space, and ultimately empty into the internal jugular vein^{1,2}. Cerebral vein and dural sinus thrombosis (CVT) is less common than most other causes of stroke. Cerebral venous thrombosis (CVT) is uncommon, with an overall incidence of <1/100,000 annually. The disorder is more common in neonates and children than in adults, and among young adults more common in women than men. The major risk factors for CVT in adults are prothrombotic (hypercoagulable) conditions, infection, head injury, and mechanical precipitants^{3,4}.

*correspondence to Dr. Abbashar Hussien, faculty of medicine, University Of Kartoum- Sudan

The clinical presentation of CVT is highly variable. Headache is the most frequent symptom and may occur as part of an isolated intracranial hypertension syndrome, with or without vomiting, papilledema, and visual problems. MRI in combination with MR venography is the most sensitive examination technique for demonstrating the thrombus and the occluded dural sinus or vein. Anticoagulation is the main stay of treatment. Predictors of poor long-term prognosis include CNS infection, malignancy, deep CVT location, intracranial hemorrhage, Glasgow coma scale score on admission <9, mental status abnormality, age >37 years, and male sex^{5,6}.

Objective:

To study the clinical presentation and some of the risk factors associated with dural sinus thrombosis among Sudanese patients seen in

Elshaab Teaching Hospital in the period between November 2008 and July 2010.

Methodology:

This is prospective descriptive cross sectional, hospital based study, conducted at Elshaab Teaching Hospital, which is a tertiary hospital, located in the centre of Khartoum state. There are two neurological units with 43 beds and two neurosurgical units with 50 beds. There are three intensive care units, two neurology referred clinics and three neurosurgery referred clinics each week. All adult Sudanese patients with dural sinus thrombosis who were admitted to the hospital and accepted to participate in the study during the period from November 2008-July 2010 were enrolled. The consent was taken from the patient or the family when the patient is confused. The study was approved by the local ethics committee. The data were collected using carefully designed questionnaire. The informers were either the patients or close relatives. A full detailed history and proper systemic and neurological examination was performed to each patient by the authors. The following investigations were done for each patient: Urine analysis, hemoglobin, total white blood cells, erythrocyte sedimentation rate, brain MRI and magnetic resonant venography. The rest of the investigations depend on the underlying causes of dural venous thrombosis e.g. sickling test, protein C, protein S, antithrombin 111 assessment, antinuclear antibodies, anti DNA antibodies and antiphospholipid antibody. All patients were closely followed up for early detection of complications and outcome. The data were entered to the computer from a master sheet recording using software program, the data were analyzed and the results were expressed as figures, tables, graphs using statistical package for social science (SPSS).

Limitations of the study: The explanatory power of the study was limited by its small sample size, inherited conditions screening was not done. A further limitation is related to the duration of the study which was short.

Results:

The study showed that 49 patients (98%) of our studied group were females, and the

majority was in the age group 25-35 years (table1).

Table1: shows age distribution among 50 patients with dural sinus thrombosis seen in ELshaab Hospital in the period (November 2008-July 2010).

Age	Frequency	Percent
less than 25	14	28%
25-35	25	50%
more than 35	11	22%
Total	50	100%

It was found that 33 patients (66%) were from the center of the Sudan, 14(28%) from north, 2(4%) from west and one patient (2%) was from the south. 44 patients (88%) were housewives, 4 (8%) were students and 2 patients (4%) were unemployed.

Table 2: Distribution of risk factors among 50 patients with dural sinus thrombosis seen at El Shaab Hospital in the period November 2008-July 2010.

Risk Factors	Frequency	Percent
Gastrointestinal symptoms	1	1.78%
Musculoskeletal symptoms	7	12.5%
Gynecological symptoms	30	53.57%
Pregnancy Induced Hypertension	5	8.9%
Ear discharge	4	7.14%
Sinusitis	3	5.35%
Dental problems	2	3.57%
Eye infection	0	0%
Facial infection	0	0%
Deep vein thrombosis	3	5.35%
Sickle cell anaemia	1	1.78%
Total	56	100%

Delivery was found to be the common gynecological risk factor, [17patients

(56,7%)], followed by pregnancy [8 (26,7%)] Fig(1).

The second cranial nerve was found to be the most common affected one [41 (84%)patients], followed by the six cranial nerve [4(8%) patients].

Figure(3)shows that the most common radiological findings were saggital sinus thrombosis which was detected in 24 patients(48%),followed by transverse sinus thrombosisThe outcome of the study was as follows: 36 (72%) patients recovered

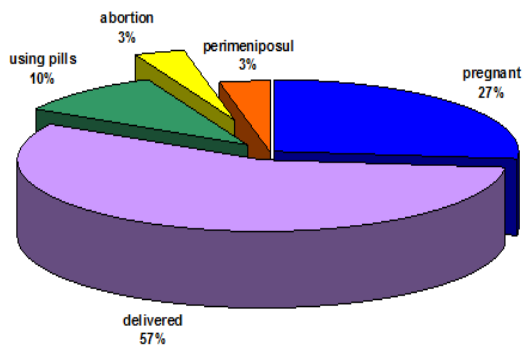


Figure1:The distribution of Gynecological risk factors among 49 female patients with dural sinus thrombosis seen at El Shaab Hospital in the period November 2008-July 2010.

Table 3:The distribution of neurological symptoms among 50 patients with dural sinus thrombosis, seen at ELshaab Hospital in the period from November 2008 to July 2010.

Neurological symptoms	Frequency	Percent
limb weakness	14	28%
Numbness	0	0%
Headache	48	96%
Convulsions	23	46%
Loss of consciousness	23	46%
Neck stiffness	45	90%
Neck pain	45	90%
Cranial nerve symptoms	40	88%
Loss of sphincter control	23	46%
Impaired vision	47	87%
Loss of vision	4	.08%

completely,7 (14%) left with residual weakness, 4 (8%) lost their vision, and 3 patients(6%)died.

Discussion:

The study showed that the majority of our patients were females, this is similar to what was reported by Ferro ⁷. The female predominance in CVT is found in young adults, but not in children or older adults². Similar to what was reported by the International Study on Cerebral Vein and Dural Sinus Thrombosis (ISCVT) the ages of

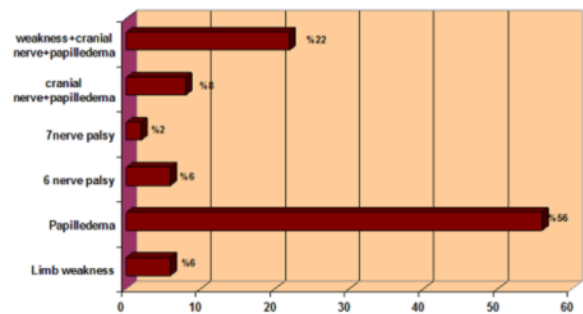


Figure 2: The neurological findings among 50 patients with Dural sinus thrombosis seen in ELshaab Hospital in the period from November 2008-July 2010.

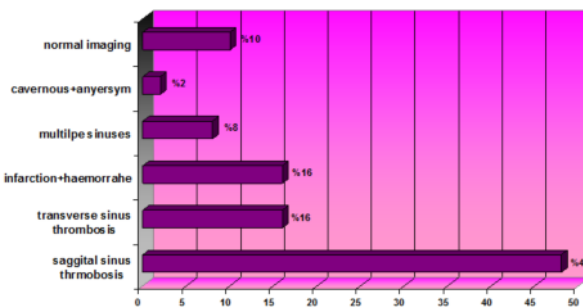


Figure 3: The radiological findings among 50 patients with Dural sinus thrombosis seen in ELshaab Hospital in the period from November 2008-July 2010.

the majority of our patients were between 25-35years. This, most properly is due to the fact that this age group is the reproductive age and so patients are more prone to use pills or become pregnant⁸.

Regarding risk factors of Dural Venous Thrombosis, our findings did not differ from what was mentioned in the literature ⁹. The study showed that gynecological risk factors were the most common ones ⁴. Other risk

factors reported among our studied group included; ear discharge, sinusitis and dental problems, this is similar to what was reported by other researchers worldwide^{3,7,10}.

Cerebral vein and dural sinus thrombosis (CVT) has a highly variable clinical presentation^{11,12}. The onset can be acute, subacute, or chronic.

It did appear that headache is the most frequent symptom of CVT. Headaches associated with CVT are more frequent in women and young patients than in men or older adults. Other symptoms like neck pain and stiffness, symptoms referable to cranial nerves involvement were observed in a considerable number of our patients. Similar to other reports, sagittal sinus thrombosis were more frequent than transverse sinus thrombosis¹³.

Both infarction and haemorrhage were detected in 16% of our patients. These are bad prognostic features. Normal imaging does not rule out dural sinus thrombosis. We found that most of our patients showed remarkable improvement (72%), this is similar to what was reported by Ferro JM and his colleagues⁷. Almost 14% of our studied group left with residual weakness, which is comparable to the 22% in the above mentioned study.

Mortality in the studied group (6%) was nearly similar to what was stated in ISCVT study (8.3%)⁸.

Conclusion:

In this study dural sinus thrombosis is more common in females. Gynecological conditions are most common risk factors. Dural sinus thrombosis has variable clinical presentation; most common symptom was headache and neck pain. Papilledema was the commonest examination findings. Diagnosis is combination of high clinical suspicion and

neuroimaging. Great majority of the patients showed remarkable improvement. Further studies-with larger sample size-are needed to assess the role of risk factors in the

References:

1. Crassard, I, Soria, C, Tzourio, C, et al. A negative D-dimer assay does not rule out cerebral venous thrombosis: a series of seventy-three patients. *Stroke* 2005; 36:1716-1722.
2. Ferro JM, Canhão P, Stam J. ISCVT Investigators. Prognosis of cerebral vein and dural sinus thrombosis: results of the International Study on Cerebral Vein and Dural Sinus Thrombosis (ISCVT). *Stroke* 2004; 35:664-672.
3. DeVeber, G, Andrew, M, Adams, C and the Canadian Pediatric Ischemic Stroke Study Group. Cerebral sinovenous thrombosis in children. *N Engl J Med* 2001; 345:417-422.
4. Lanska, DJ, Kryscio, RJ. Risk factors for peripartum and postpartum stroke and intracranial venous thrombosis. *Stroke* 2000; 31:1274-1279.
5. Lancon, JA, Killough, KR, Tibbs, RE. Spontaneous dural sinus thrombosis in children. *Pediatr Neurosurg* 1999; 30:23-27.
6. Towbin, A. The syndrome of latent cerebral venous thrombosis: its frequency and relation to age and congestive heart failure. *Stroke* 1973; 4:419-425.
7. Ferro, JM, Correia, M, Pontes, C. Cerebral vein and dural sinus thrombosis in Portugal: 1980-1998. *Cerebrovasc Dis* 2001; 11:177-183.
8. Higgins JN, Owler BK, Cousins C et al. Venous sinus stenting for refractory benign intracranial hypertension. *Lancet* 2002; 359:228-235.
9. Bousser MG, Chiras J, Bories J et al. Cerebral venous thrombosis - review of 38 cases. *Stroke* 1985; 16:199-205
10. Biousse V, Ameri A, Bousser MG. Isolated intracranial hypertension as the only sign of cerebral venous thrombosis. *Neurology* 1999; 53:1537-1545.
11. Lopes MG, Ferro J, Pontes C. Headache and cerebral venous thrombosis. *Cephalalgia* 2000; 20:292-300.
12. Stam, J (2005). Thrombosis of the cerebral veins and sinuses. *N Engl J Med*; 352:1791-1800.
13. Selim M, Fink J, Linfante I, et al. Diagnosis of cerebral venous thrombosis with echo-planar T2*-weighted magnetic resonance imaging. *Arch Neurol* 2002; 59:1021-1028.