

Intranasal Leiomyoma: An extremely rare case

Sleman A S¹, Fadl A F², Abusabib, M M³

Abstract

This case report describes an extremely rare case of a cellular leiomyoma in the nasal cavity. A 40 yrs-old Sudanese woman presented to our hospital with tumoral lesion in the left nasal cavity with symptoms of nasal obstruction, nasal discharge, anosmia, snoring and spells of mild epistaxis. At gross inspection, the tumor measured 6×8×10 cm. microscopically after excision; the tumor consisted of many spindled cells with blunt ended nuclei. The diagnosis was confirmed as cellular intranasal leiomyoma. To the best of our knowledge, only 28 cases were reported in the English literature so far.

Case Report

A 40-year-old Sudanese woman presented to ENT department in Omdurman Teaching Hospital Sudan with a big nasal mass. The mass was initially small and in 5 years it reached a large size.

She had complete nasal obstruction, nasal discharge, anosmia, snoring and attacks of mild epistaxis and frontal headache. Her past medical history showed no significant problems.

On examination, externally there was swelling in the left side of the nasal root with widened intercanthal distance (hypertelorism). The swelling was bony hard and not tender.

Anterior rhinoscopy revealed rounded big fleshy, pink colored mass filling left nasal cavity; measuring about 6 × 8 cm. The mass has smooth surface, pushing the nasal septum to the right side, not tender or friable. The septum was intact anteriorly but the right nasal cavity was completely blocked by the pushed nasal septum. Posterior rhinoscopy was difficult. The ear examination showed mild retracted left tympanic membrane. Anosmia was evident on the cranial nerves examination. The other cranial nerves were intact.

A computed tomography (CT) scan of the region showed a big mass measuring 8×6×10 cm occupying both nasal cavities extending to the left maxillary sinus, both ethmoids and sphenoid sinuses making a single cavity (Figure 1,2). There was no bony erosion in relation to the orbit or base of the skull.

1. ENT department, Omdurman Teaching Hospital, Sudan.

2. Associate professor, Head ENT department, Omdurman Islamic University, Sudan.

3. Specialist, ENT department, Omdurman Teaching Hospital, Sudan.

Correspondences to: Al Amarat 12217, P.O. Box 8102, Khartoum, Sudan. Email: drfadlent@hotmail.com

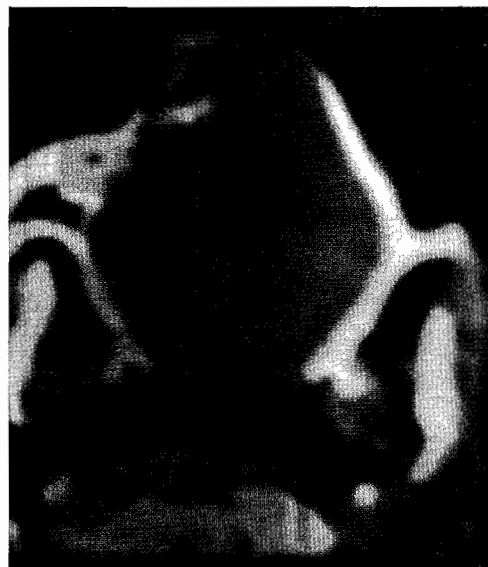

Figure (1): CT Scan axial section (soft tissue window) showing big soft tissue mass occupying whole nasal cavity and extending to nasopharynx

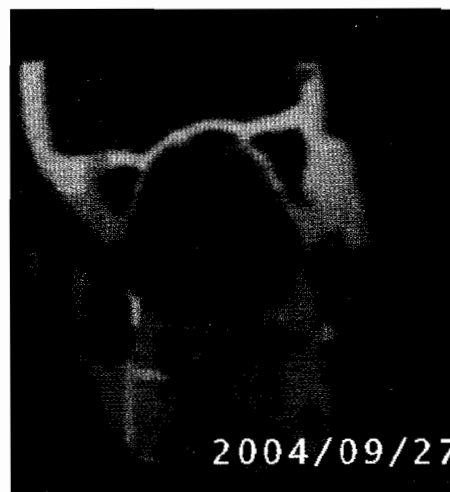

Figure (2): CT Scan coronal section (soft tissue window) showing big soft tissue mass occupying whole nasal cavity, bilateral maxillary and ethmoidal sinuses and extending to sphenoid sinus

Under local anesthesia punch biopsy taken from the left nasal mass revealed leiomyoma in histopathology.

On October 2004, total resection of the mass via left lateral rhinotomy approach was performed. The mass was firm, pinkish in color occupying the left nasal cavity, left maxillary sinus, bilateral ethmoidal sinuses and extending to the left sphenoid sinus, making one big cavity. It was shelled out easily and it measured 6×8×10 cm (Figure 3).

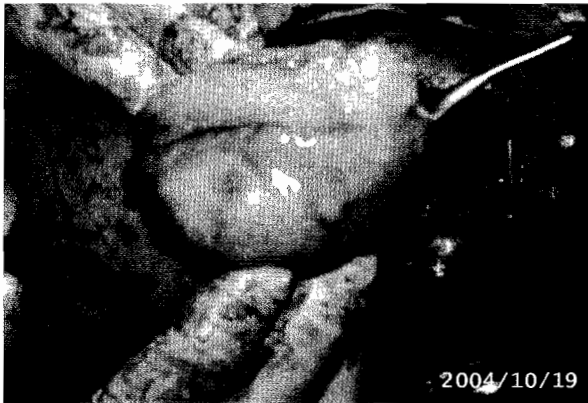


Figure (3): the nasal mass after removal

Postoperative recovery was uneventful and she was discharged in good condition after 4 days. Histopathology of the excisional biopsy showed the tumor consisted of many spindle cells with blunt ended nuclei, features consistent with leiomyoma. No mitotic figures were observed. This was further confirmed by immunohistochemistry. On follow up there has been no recurrence 2 years postoperatively.

Discussion

Leiomyoma is a benign myogenic tumor that may develop wherever smooth muscle is present. It occurs commonly in the uterus, skin, and gastrointestinal tract and is rare within the nasal cavity.¹

Enzinger and Weiss analyzed a total of 7,748 leiomyomas, 95% of the tumors occurred in the female genitalia (uterus), 3% in the skin, 0.9% in the gastrointestinal tract and the remainder in various sites. Leiomyomas are classified into 3 histological subtypes: vascular, nonvascular and epithelioid or leiomyoblastoma. Vascular leiomyoma is a relatively uncommon smooth muscle tumor rarely found in head and neck area.² to the best of our knowledge; there have been only 28 reported cases of nasal leiomyoma in English medical literature.^{2, 3, and 4}

Several benign and malignant entities appear as a polypoid mass in the nasal cavity, with inflammatory polyps being by far the most

common.⁶ Leiomyomas developing in the nasal cavity and paranasal sinuses are extremely rare.

Prominent clinical symptoms are nasal obstruction and pain, but nasal bleeding is rather less frequent⁴. This case was diagnosed histologically as cellular leiomyoma. Immunohistochemistry studies further confirmed the diagnosis as both smooth muscle actine (SMA) and vimentin (mesenchymal marker) were positive while desmin and myogenin (skeletal muscle marker) were negative.

Differential diagnosis included angiofibroma, inverted papilloma, hemangiopericytoma, schwannoma and malignancy specially squamous cell carcinoma, adenocarcinoma and adenoicycstic carcinoma.

Leiomyomas of the skin and subcutis are usually divided into vascular and nonvascular types. In the nasal cavity, three hypotheses have been given for the origin of smooth muscle tumors: from aberrant undifferentiated mesenchyme; from smooth muscle elements in the wall of blood vessels or from both sources.⁷ Most of the authors support the idea that the vascular smooth muscle is the origin of the tumor. Malignant transformation of vascular leiomyoma has not been reported, in spite of local recurrence in a few cases (2 of 562 cases).⁸

Conclusion

Leiomyomas of the nasal cavity are extremely rare. This case is the 29th reported case in the literature. The exact origin of these tumors is not known, but most agree that the etiology is probably from smooth muscle cells in the walls of blood vessels. Surgical excision of these benign tumors yields high cure rates. No malignant transformation has been reported.

Acknowledgment

The authors express their gratitude and thanks to Professor Bashir I Mukhtar (SMSB, Khartoum) and Ass. Professor Mohamad Abdul Hameed (Dean Faculty of Medical Laboratories, Omdurman Islamic University) for their great help in the histopathological studies. Also thanks are extended to Dr. Ahmad A Badea (Pathology Department, Rabat University) and Dr. Babikir I Mohamed (Pathology Department, Khartoum Radiation and Isotope Hospital) for their great work in immunohistochemistry confirmation.

References

1. Bloom DC, Finley JC Jr, Broberg TG et al. Leiomyoma of the nasal septum. *Rhinology* 2001 Dec;39(4):233-5
2. Osaki M, Osaki M, Kodani I et al. Vascular Leiomyoma of the Nasal Cavity: Case Report and Review of the Literature. *Yonago Acta medica* 2002;45:113-116.

3. Wang, C.-P. Chang, Y.-L. Sheen, T.-S. Vascular Leiomyoma of the Head and Neck. *Laryngoscope* April 2004; 114(4):661-665.
4. Horie S, Hasegawa K and Terada T. Cellular Leiomyoma of the Nasal Cavity: Report of a Case and Review of Literature. *Yonago Acta medica* 2001;44:85–89.
5. Vincenzi, Rossil G, Monzani D et al Atypical (bizarre) leiomyoma of the nasal cavity with prominent myxoid change. *Journal of Clinical Pathology* 2002;55:872-875.
6. Fu YS, Perzin KH. Non-epithelial tumours of the nasal cavity, paranasal sinuses, and nasopharynx; a clinicopathologic study. *Cancer* 1975;35:1300–8.
7. Batsakis JG. Tumors of the head and neck. clinical and pathological considerations. 2nd ed.; 1979. p.354–356.
8. Hachisuga T, Hashimoto H, Enjoji M. Angioleiomyoma. a clinicopathologic reappraisal of 562 cases. *Cancer* 1984;54:126–130.