

Case Report

Iatrogenic stomach perforation complicating unrecognized posttraumatic diaphragmatic hernia (Gastro Thorax)

Mohamed Elamin Ahmed¹ and Omer Alkarouri²

Abstract

We report a case of 21-year-old male patient with traumatic diaphragmatic herniation of the stomach that is misdiagnosed as a hemo-pneumothorax with the resulting insertion of a chest tube causing iatrogenic perforation of the stomach and draining of gastric content into the pleural cavity. An emergency thoracotomy was performed, and the stomach has been repaired and reduced to the abdomen, followed by repair of the left diaphragm. Postoperative wound infection due to residual empyema was treated aggressively.

We discussed and highlighted the diagnostic approach to clinical management of traumatic diaphragmatic rupture (TDR) and the importance of using nasogastric (NG) tube to avoid occurrence of such iatrogenic trauma.

Key words: Diaphragmatic rupture Stomach perforation.

Traumatic diaphragmatic rupture after blunt trauma is a marker of severity¹. Herniations of the abdominal content through the defect in the diaphragm occur as the intra thoracic pressure is lower than that of the intra abdominal pressure². Different case reports mentioned different causes for stomach perforation:

- Due to severity of trauma with great impact on the herniating stomach resulting in immediate perforation³.
- As a result of gastric incarceration following TDR after a period of time^{4,5}.
- And a rare case of TDR with laceration of stomach caused by violent cough⁶.
- Iatrogenic causes are also mentioned⁷, and our case falls under this category.

1. Consultant Cardiothoracic Surgeon, Dean of Research Alneelain University Khartoum

2. Department of cardio-thoracic surgery, Elshaab Teaching Hospital, Khartoum, Sudan

Case report

A 21-year-old male was involved in a severe road traffic accident (RTA) following which he had multiple bruises overlying lower left chest and hip and lower extremities, as well as pain in the left hip with inability to put weight on the left foot. Patient was 1st seen at a nearby general hospital, initially managed and discharged after observation over night. Patient didn't improve and his chest pain and dyspnoea persisted. He was referred to another hospital. Following chest x-ray [fig.1] a decision to put a chest tube was made by the surgical registrar on call, following which a little bubble came out in the underwater seal bottle, so another chest drain was attempted without much drainage and no clinical improvement. In fact the patient's condition became worst. A more experienced physician inserted a well positioned chest tube for the purpose (3rd chest tube in array)[fig.2], but this time the chest tube drainage was gastric fluid [fig.3].

Fig 1: CXR showing fluid level in the stomach.

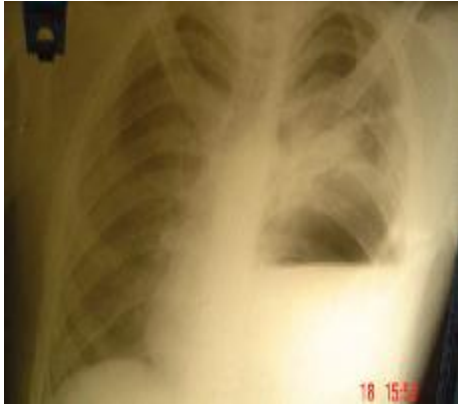

Fig 2: 3rd chest tube in array.

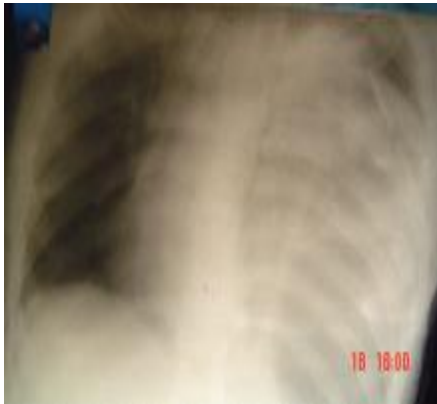

Fig 3: chest drainage bottle with gastric fluid



Patient condition deteriorated over the following hours.

The patient was referred to our specialized Cardio-Thoracic Surgery unit in Elshaab

Teaching Hospital. On examination the patient was found to be morbid, confused, hypotensive, with low urine output. CXR was reviewed and a diagnosis of ruptured diaphragm with iatrogenic perforated stomach in the left chest (Gastro Thorax) was made. Continued resuscitation of the patient with I.V fluids and colloids as well as I.V antibiotics was performed. Patient was taken for emergency surgery. Postero-lateral 7th intercostal space thoracotomy was performed and the findings were as follow; skin, subcutaneous space and muscles were flooded with gastric content. Adequate surgical toilet with saline wash was done. A large perforation and a small one were found in the stomach, repair was done and the stomach was reduced back into the abdomen, followed by repair of the diaphragm [fig.4, fig5].

Fig 4: large perforation in the stomach

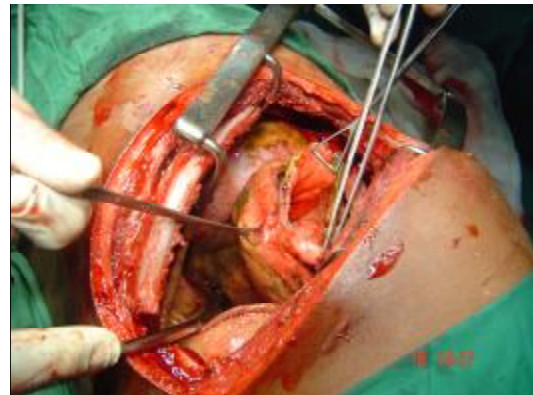
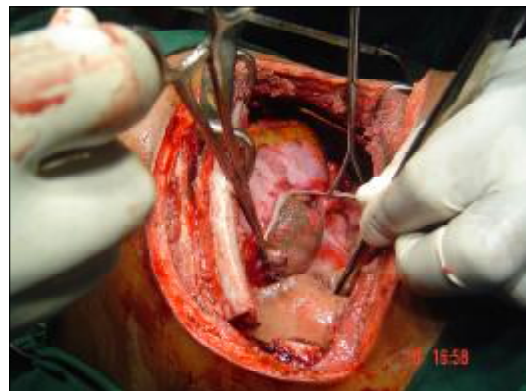


Fig 5: large defect in the left diaphragm after repair and reduction of stomach.



Large basal and apical chest tubes were left for drainage. I.V metronidazole and cephalosporin were administered to safeguard against synergistic bacteria i.e. Meleny's gangrene.

As expected; postoperatively the patient's condition improved, but severe thoracotomy wound infection and dehiscence occurred due to residual empyema. With continuous occlusive dressing and repeated wound culture and change of antibiotics accordingly we managed to close the dehisced wound.

Discussion

The reported incidence of traumatic diaphragmatic rupture (TDR) after blunt truncal trauma varies between different studies 0% - 8% of all hospitalized car accident victims^{1, 6, 8-10}. Most (90% -- 95%) of these TDR are in the left side², with mortality rate that varies between 16.6 % -- 33.3%¹.

Complications such as visceral herniation or strangulation may arise early in patient's clinical course or remote from the traumatic event⁹. Such injuries have been treated by labarotomy or thoracotomy according to the associated organ damage¹¹.

Blunt TDR presents a difficult diagnostic dilemma. There is no satisfactory diagnostic tool for TDR other than having a high index of clinical suspicion⁹

It has been reported as one of the most commonly missed injuries in trauma⁸. The diagnosis is more difficult in the absence of accompanying abdominal or thoracic injury, in such cases; the injury is initially, often, overlooked¹².

Initial chests radiography (CXR) or computed tomography (CT) of the chest remains the 1st diagnostic test for most institutes with no statistical difference between the two choices as documented by recent studies⁹. Nevertheless, CT is highly recommended by some older papers².

Inserting a nasogastric tube may be of a great help in recognizing TDR with gastric herniation. A previous study mentioned that in a group of patients, who were surgically proven to have TDR with gastric herniation, the diagnoses was made or confirmed by

inserting NG tube in six out of eight patients¹³. Also NG tube is useful in decompressing the stomach in cases of tension gastro thorax which is a life threatening condition. Although there is an argument about this point, that the NG tube may exacerbate the condition, and it is best to use percutaneous needle decompression of the stomach throw the chest wall which is thought to be safer and more rapid¹⁴.

During the last years thoracoscopy is introduced as one of the good choices for diagnosing the suspected cases. It is both a good diagnostic and under certain conditions, therabutic, tool. It is quickly performed, has high probability of success and cause little surgical trauma¹².

Conclusion

Chest tube insertion whenever needed one shouldn't hesitate to put one, but only rarely indicated as emergency as in tension pneumothorax. In chest x-ray if you find a shadow in the left lower part of the chest and there is a history of blunt chest trauma; stomach herniation in the thorax is to be considered. To establish the diagnosis, an NG tube, CXR is the answer. Diaphragmatic rupture can be passed unnoticed in blunt injuries. In most cases there is no need for emergency repair, only analgesia and conservative initial management might be sufficient. Surgical repair may be done electively throw thoracotomy or labarotomy according to surgeon preference and experience. From this case we do recommend for perforated stomach in the chest to be called GASTRO-THORAX.

References

1. Sirbu H, Busch T, Spillner J et al. Late bilateral diaphragmatic rupture: challenging diagnostic and surgical repair. *Hernia* 2005; 9:90-92
2. Heiberg E, Wolverson MK, Hurd RN et al. CT recognition of traumatic rupture of the diaphragm. *AJR* 1980; 135:369-372
3. Yamane Y, Kubo H, Ikeda M et al. Left diaphragmatic hernia due to blunt chest trauma

complicated with intrapleural gastric perforation. *Kyobu Geka* 1995; 48(9):796-799

4. Abboud B, Tabet G, Bou Jaoude J et al. Gastric incarceration and perforation following posttraumatic diaphragmatic hernia: case report and review of literature. *J Med Liban* 2007; 55(2):104-107

5. Prieto Nieto I, Perez Robledo JP et al. Gastric incarceration and perforation following posttraumatic diaphragmatic hernia. *Acta Chir Belg* 2001; 101(2): 81-83

6. Kara E, Kaya Y, Zeybek R et al. A case of a diaphragmatic rupture complicated with laceration of stomach and spleen caused by a violent cough presenting with mediastinal shift. *Ann Acad Med Singapore* 2004; 33:649-650

7. Zieren J, Enzwei ler C, Muller JM. Tube thoracostomy complicates unrecognized diaphragmatic rupture. *Thorac Cardiovasc Surg* 1999; 47(3):199-202

8. Slim K, Bousquet J, Chipponi J. Laparoscopic repair of missed blunt diaphragmatic rupture using prosthesis. *Surg Endosc* 1998; 12:1358-1360

9. Nau T, Seitz H, Mousavi M et al. The diagnostic dilemma of traumatic rupture of the diaphragm. *Surg Endosc* 2001; 15:992-996

10. How C, Tee A, Quah J. Delayed presentation of gastro thorax masquerading as pneumothorax. *Primary Care Respiratory Journal* 2007; 16(1):54-56

11. Kurata K, Kubota K, Oosawa H et al. Thoracoscopic repair of traumatic diaphragmatic rupture. *Surg Endosc* 1996; 10:850-851

12. Kocher TM, Gurke L, Kuhrmeier A et al. Misleading symptoms after a minor blunt chest trauma. *Surg Endosc* 1998; 12:879-881

13. Perlman SJ, Rogers LF, Mintzer RA et al. Abnormal course of nasogastric tube in traumatic rupture of left hemi diaphragm. *ARJ Am J Roentgenol* 1984; 142(1):85-88

14. Slater RG. Tention gastro thorax complicating acute traumatic diaphragmatic rupture. *J Emerg Med* 1992; 10(1):25-30.